



National Comprehensive  
Cancer Network®

NCCN Clinical Practice Guidelines in Oncology (NCCN Guidelines®)

# Hepatobiliary Cancers

Version 5.2021 — September 21, 2021

**NCCN.org**

NCCN Guidelines for Patients® available at [www.nccn.org/patients](http://www.nccn.org/patients)

**Continue**



National  
Comprehensive  
Cancer  
Network®

# NCCN Guidelines Version 5.2021 Hepatobiliary Cancers

[NCCN Guidelines Index](#)  
[Table of Contents](#)  
[Discussion](#)

**\*Al B. Benson, III, MD/Chair †**

Robert H. Lurie Comprehensive Cancer  
Center of Northwestern University

**\*Michael I. D'Angelica, MD/Vice-Chair ¶**

Memorial Sloan Kettering Cancer Center

**Daniel E. Abbott, MD ¶**

University of Wisconsin  
Carbone Cancer Center

**Daniel A. Anaya, MD ¶**

Moffitt Cancer Center

**Robert Anders, MD, PhD ≠**

The Sidney Kimmel Comprehensive  
Cancer Center at Johns Hopkins

**Chandrakanth Are, MD, MBA ¶**

Fred & Pamela Buffett Cancer Center

**Melinda Bachini ¥**

The Cholangiocarcinoma Foundation

**Mitesh Borad, MD †**

Mayo Clinic Cancer Center

**Daniel Brown, MD † ¶**

Vanderbilt-Ingram Cancer Center

**Adam Burgoyne MD †**

US San Diego Moores Cancer Center

**Prabhleen Chahal, MD ≠**

Case Comprehensive Cancer Center/  
University Hospitals Seidman Cancer Center  
and Cleveland Clinic Taussig Cancer Institute

**Daniel T. Chang, MD §**

Stanford Cancer Institute

**Jordan Cloyd, MD ¶**

The Ohio State University Comprehensive  
Cancer Center - James Cancer Hospital  
and Solove Research Institute

**Jordan Cloyd, MD ¶**

The Ohio State University Comprehensive  
Cancer Center - James Cancer Hospital  
and Solove Research Institute

**Anne M. Covey, MD ¶**

Memorial Sloan Kettering Cancer Center

**Sepideh Gholami, MD ¶**

UC Davis Comprehensive Cancer Center

**Evan S. Glazer, MD, PhD ¶**

St. Jude Children's Research Hospital/The  
University of Tennessee Health Science  
Center

**Lipika Goyal, MD †**

Massachusetts General Hospital  
Cancer Center

**William G. Hawkins, MD ¶**

Siteman Cancer Center at Barnes-  
Jewish Hospital and Washington  
University School of Medicine

**Erika Hissong, MD ≠**

University of Michigan Rogel Cancer Center

**Renuka Iyer, MD † ¶**

Roswell Park Cancer Institute

**Rojymon Jacob, MD §**

O'Neal Comprehensive  
Cancer Center at UAB

**R. Kate Kelley, MD † ‡**

UCSF Helen Diller Family  
Comprehensive Cancer Center

**Robin Kim, MD § ¶**

Huntsman Cancer Institute  
at the University of Utah

**Matthew Levine, MD, PhD §**

Abramson Cancer Center  
at the University of Pennsylvania

**Manisha Palta, MD §**

Duke Cancer Institute

**James O. Park, MD ¶**

Fred Hutchinson Cancer Research Center/  
Seattle Cancer Care Alliance

**Steven Raman, MD ¶**

UCLA Jonsson Comprehensive Cancer Center

**Sanjay Reddy, MD, FACS ¶**

Fox Chase Cancer Center

**Vaibhav Sahai, MD, MS †**

University of Michigan  
Rogel Cancer Center

**Tracey Schefter, MD §**

University of Colorado Cancer Center

**Gagandeep Singh, MD ¶**

City of Hope National Medical Center

**Stacey Stein, MD †**

Yale Cancer Center/Smilow Cancer Hospital

**Jean-Nicolas Vauthey, MD ¶**

The University of Texas MD Anderson Cancer Center

**Alan P. Venook, MD † ‡ †**

UCSF Helen Diller Family  
Comprehensive Cancer Center

**Adam Yopp, MD ¶**

UT Southwestern Simmons  
Comprehensive Cancer Center

**Continue**

**NCCN**

**Susan Darlow, PhD**

**Cindy Hochstetler, PhD**

**Liz Hollinger, BSN, RN**

**Nicole McMillian, MS**

[NCCN Guidelines Panel Disclosures](#)

≠ Gastroenterology	≠ Pathology
‡ Hematology/Hematology oncology	§ Radiotherapy/Radiation oncology
‡ Internal medicine	¶ Surgery/Surgical oncology
¶ Interventional radiology	ξ Transplantation
† Medical oncology	* Discussion section writing committee
¥ Patient advocacy	

National  
Comprehensive  
Cancer  
Network®

# NCCN Guidelines Version 5.2021

## Hepatobiliary Cancers

[NCCN Guidelines Index](#)  
[Table of Contents](#)  
[Discussion](#)

### [NCCN Hepatobiliary Cancers Panel Members](#) [Summary of the Guidelines Updates](#)

#### Hepatocellular Carcinoma (HCC)

- [HCC Screening \(HCC-1\)](#)
- [Diagnosis of HCC \(HCC-2\)](#)
- [Clinical Presentation and Workup: HCC Confirmed \(HCC-3\)](#)
- [Potentially Resectable or Transplantable, Operable by Performance Status or Comorbidity \(HCC-4\)](#)
- [Unresectable Hepatocellular Carcinoma \(HCC-5\)](#)
- [Liver-Confined Disease, Inoperable by Performance Status, Comorbidity, or With Minimal or Uncertain Extrahepatic Disease \(HCC-6\)](#)
- [Principles of Imaging \(HCC-A\)](#)
- [Principles of Biopsy \(HCC-B\)](#)
- [Child-Pugh Score \(HCC-C\)](#)
- [Principles of Surgery \(HCC-D\)](#)
- [Principles of Locoregional Therapy \(HCC-E\)](#)
- [Principles of Radiation \(HCC-F\)](#)
- [Principles of Systemic Therapy \(HCC-G\)](#)

#### Biliary Tract Cancers: Gallbladder Cancer

- [Incidental Finding at Surgery \(GALL-1\)](#)
- [Incidental Finding on Pathologic Review \(GALL-2\)](#)
- [Mass on Imaging \(GALL-3\)](#)
- [Jaundice and Metastatic Disease \(GALL-4\)](#)
- [Post-Resection \(GALL-5\)](#)
- [Principles of Surgery and Pathology \(GALL-A\)](#)

#### Biliary Tract Cancers: Intrahepatic Cholangiocarcinoma

- [Presentation, Workup, Primary Treatment \(INTRA-1\)](#)
- [Adjuvant Treatment, Surveillance \(INTRA-2\)](#)
- [Principles of Surgery \(INTRA-A\)](#)

#### Biliary Tract Cancers: Extrahepatic Cholangiocarcinoma

- [Presentation, Workup, Primary Treatment \(EXTRA-1\)](#)
- [Adjuvant Treatment, Surveillance \(EXTRA-2\)](#)
- [Principles of Surgery \(EXTRA-A\)](#)

#### Biliary Tract Cancers

- [Principles of Imaging \(BIL-A\)](#)
- [Principles of Radiation Therapy \(BIL-B\)](#)
- [Principles of Systemic Therapy \(BIL-C\)](#)

#### Hepatobiliary Cancers

- [Staging \(ST-1\)](#)

**Clinical Trials:** NCCN believes that the best management for any patient with cancer is in a clinical trial. Participation in clinical trials is especially encouraged.

To find clinical trials online at NCCN Member Institutions, [click here: nccn.org/clinical\\_trials/member\\_institutions.aspx](#).

**NCCN Categories of Evidence and Consensus:** All recommendations are category 2A unless otherwise indicated.

See [NCCN Categories of Evidence and Consensus](#).

**NCCN Categories of Preference:** All recommendations are considered appropriate. [See NCCN Categories of Preference](#).

The NCCN Guidelines® are a statement of evidence and consensus of the authors regarding their views of currently accepted approaches to treatment. Any clinician seeking to apply or consult the NCCN Guidelines is expected to use independent medical judgment in the context of individual clinical circumstances to determine any patient's care or treatment. The National Comprehensive Cancer Network® (NCCN®) makes no representations or warranties of any kind regarding their content, use or application and disclaims any responsibility for their application or use in any way. The NCCN Guidelines are copyrighted by National Comprehensive Cancer Network®. All rights reserved. The NCCN Guidelines and the illustrations herein may not be reproduced in any form without the express written permission of NCCN. ©2021.



Updates in Version 5.2021 of the NCCN Guidelines for Hepatobiliary Cancers from Version 4.2021 include:

#### [HCC-G \(1 of 2\)](#)

- Subsequent-Line Therapy If Disease Progression
  - Dostarlimab-gxly was added as a treatment option for patients with MSI-H/dMMR tumors. This is a category 2B, Useful in Certain Circumstances recommendation.
  - Footnote I added: Dostarlimab-gxly is a recommended treatment option for patients with MSI-H/dMMR recurrent or advanced tumors that have progressed on or following prior treatment and who have no satisfactory alternative treatment options. (Also on BIL-C, 2 of 4)

#### [HCC-G \(2 of 2\)](#)

- The following references were added:
  - Andre T, Berton D, Curigliano G, et al. Safety and efficacy of anti-PD-1 antibody dostarlimab in patients (pts) with mismatch repair-deficient (dMMR) solid cancers: Results from GARNET study [abstract]. J Clin Oncol 2021;39:Abstract 9. (Also on BIL-C, 4 of 4)
  - Berton D, Banerjee SN, Curigliano G, et al. Antitumor activity of

dostarlimab in patients with mismatch repair-deficient/microsatellite instability-high tumors: A combined analysis of two cohorts in the GARNET study [abstract]. J Clin Oncol 2021;39:Abstract 2564. (Also on BIL-C, 4 of 4)

#### [BIL-C \(2 of 4\)](#)

- Subsequent-Line Therapy for Biliary Tract Cancers If Disease Progression
  - Dostarlimab-gxly was added as a treatment option for patients with MSI-H/dMMR recurrent or advanced tumors. This is a category 2B, Useful in Certain Circumstances recommendation.
  - Footnote g added: For patients who have not been previously treated with a checkpoint inhibitor because there is a lack of data for subsequent use of immunotherapy in patients who have previously been treated with a checkpoint inhibitor.

#### [MS-1](#)

- The discussion section has been updated to reflect the changes in the algorithm.

Updates in Version 4.2021 of the NCCN Guidelines for Hepatobiliary Cancers from Version 3.2021 include:

#### [HCC-G \(1 of 2\)](#)

- Subsequent-Line Therapy for Hepatocellular Carcinoma if Disease Progression
  - Nivolumab (Child-Pugh Class B only) changed from category 2A to category 2B and moved from Other Recommended Regimens to Useful in Certain Circumstances.
  - Other Recommended Regimens: Nivolumab was removed as a

treatment option for patients with Child-Pugh Class A.

- Footnote
  - Footnote k revised: ~~Consider if MSI-H HCC.~~ Pembrolizumab is a recommended treatment option for patients with or without MSI-H HCC.

#### [MS-1](#)

- The discussion section has been updated to reflect the changes in the algorithm.

Updates in Version 3.2021 of the NCCN Guidelines for Hepatobiliary Cancers from Version 2.2021 include:

#### [BIL-C 2 of 3](#)

- Subsequent-Line Therapy for Biliary Tract Cancers if Disease Progression
  - Useful in Certain Circumstances: Added "Infigratinib" for cholangiocarcinoma with *FGFR2* fusions or rearrangements.

RK, et al. Final results from a phase II study of infigratinib (BGJ398), an *FGFR*-selective tyrosine kinase inhibitor, in patients with previously treated advanced cholangiocarcinoma harboring an *FGFR2* gene fusion or rearrangement. J Clin Oncol 2021;39:265-265.

#### [BIL-C 3 of 3](#)

- Reference updated for Infigratinib: Javle M, Roychowdhury S, Kelley

#### [MS-1](#)

- The discussion section has been updated to reflect the changes in the algorithm.

Updates in Version 2.2021 of the NCCN Guidelines for Hepatobiliary Cancers from Version 1.2021 include:

#### [HCC-4](#)

- Surgical Assessment: UNOS criteria:
  - Sub-bullet 1 revised: *AFP level ≤1000 ng/mL and patient has a tumor 2-5 cm in diameter or 2-3 tumors ≤3 cm each 1-3 cm in diameter.*

- 5th bullet revised: ... (UNOS) criteria [*AFP level ≤1000 ng/mL and single lesion...*]

#### [MS-1](#)

- The discussion section has been updated to reflect the changes in the algorithm.

#### [HCC-D](#)

[Continued](#)  
**UPDATES**



Updates in Version 1.2021 of the NCCN Guidelines for Hepatobiliary Cancers from Version 5.2020 include:

### General

- The Principles of Radiation Therapy ([HCC-F](#)) has been separated out from the Principles of Locoregional Therapy ([HCC-E](#)).

### HCC-1

- Screening
  - ▶ 2nd column revised, "Ultrasound ± Alpha fetoprotein" changed to "Ultrasound + Alpha fetoprotein."
  - ▶ Footnote d revised, "...outcomes for patients with HCC in the setting of *NAFLD*/HBV/HCV cirrhosis when the *NAFLD*/HBV/HCV is successfully treated."

Footnote j removed, "AFP is considered optional for screening," (See Principles of Imaging, HCC-A [HCC-3](#))

- Workup: Multidisciplinary evaluation
  - ▶ 9th bullet revised, "Abdominal/pelvic CT or MRI with contrast, *if not previously done or needs updating.*"
  - ▶ New bullet 10 added, "Consider referral to a hepatologist."
  - ▶ Last column: "*Liver-confined disease*, inoperable by performance status, ~~or comorbidity, local disease only or with minimal or unknown extrahepatic disease.~~ (Also on HCC-6)
  - ▶ according to institutional practice and based on the assessment of bleeding risk."
  - ▶ 2nd bullet, sub-bullet 1 added, "*Tumor mutational burden (TMB) testing.*" (Also INTRA-1, EXTRA-1)
  - ▶ Footnote i revised, "The data reflect use on or after sorafenib *in patients who previously tolerated sorafenib at a dose of at least 400 mg per day.*"

### HCC-4

- Surgical Assessment
  - ▶ After UNOS criteria, 2nd bullet added: "Extended criteria."

### Surveillance

- ▶ 4th bullet revised, "...for carriers of hepatitis *if not previously done.*"
- Footnote x revised, "*Extended criteria/downstaging protocols are available at selected centers and through UNOS...*"
- Footnote dd revised, "*Multiphasic abdominal/pelvic MRI or multi-phase CT scans for liver assessment, are recommended. Consider CT chest and CT/MRI pelvis (See Principles of Imaging, HCC-A)* (Also on HCC-5).

### HCC-5

- Treatment
  - ▶ After "Not a transplant candidate" the treatment options were

divided into two separate pathways:

- ▶ After "Not a transplant candidate" the treatment options were divided into two separate pathways:
  - ◊ Upper pathway: Locoregional therapy preferred listed with corresponding options.
  - ◊ Lower pathway: Includes the options of clinical trial, systemic therapy, and best supportive care. (Also HCC-6)

### Surveillance

- ▶ 4th bullet added, "Consider early imaging per local protocol."

### HCC-6

- Metastatic disease or Extensive liver tumor burden pathway:
  - ▶ Recommendation revised to "~~Consider Biopsy to confirm metastatic disease for histologic confirmation if not previously done.~~"

### HCC-A (1 of 3)

### Screening and surveillance

- ▶ 1st paragraph, last sentence changed, "Serum biomarkers such as AFP may incrementally improve the performance of imaging-based screening and surveillance, ~~but their cost-effectiveness has not been established; and their use as supplementary surveillance tests is optional.~~"

### HCC-B

### Initial biopsy

- ▶ 3rd sub-bullet revised, "Confirmation of metastatic disease could change clinical decision-making *including enrollment in clinical trials.*"
- ▶ Bullet removed, "Histologic grading or molecular characterization is desired."

### HCC-E (1 of 2)

### Arterially Directed Therapies

- ▶ 3rd bullet: New sub-bullet added, "With RE, delivery of  $\geq 205$  Gy to the tumor may be associated with increased overall survival." 4th bullet: New sub-bullet, added, "Randomized controlled trials have shown that Y-90 is not superior to sorafenib for treating advanced HCC. RE may be appropriate in some patients with advanced HCC, specifically patients with segmental or local portal vein, rather than main portal vein thrombosis."
- ▶ Bullet removed, "The angiographic endpoint of embolization may be chosen by the treating physician."

[Continued](#)  
**UPDATES**





# NCCN Guidelines Version 5.2021

## Hepatobiliary Cancers

### Updates in Version 1.2021 of the NCCN Guidelines for Hepatobiliary Cancers from Version 5.2020 include:

- ▶ Last bullet revised, "...benefit in ~~two~~ three randomized trials; other randomized phase III trials are ongoing to *further investigate other systemic therapies including immunotherapy in combination with arterial therapies.*"

#### [HCC-E \(2 of 2\)](#)

- New references added,
  - ▶ Garin E, Tselikas L, Guiu B et al and the DOSISPHERE-01 Study Group. Personalised versus standard dosimetry approach of selective internal radiation therapy in patients with locally advanced hepatocellular carcinoma (DOSISPHERE-01): a randomised, multicentre, open-label phase 2 trial. *Lancet Gastroenterol Hepatol* 2021;6:17-29. [HCC-E \(2 of 2\)](#)
  - ▶ Vilgrain V, Pereira H, Assenat E, et al. Efficacy and safety of selective internal radiotherapy with yttrium-90 resin microspheres compared with sorafenib in locally advanced and inoperable hepatocellular carcinoma (SARAH): an open-label randomised controlled phase 3 trial. *Lancet Oncol* 2017;18:1624-36.
  - ▶ Chow PKH, Gandhi M, Tan SB, et al. SIRveNIB: Selective Internal Radiation Therapy Versus Sorafenib in Asia-Pacific Patients With Hepatocellular Carcinoma. *J Clin Oncol* 2018;36:1913-21.
  - ▶ Kulik LM, Carr BI, Mulcahy MF, et al. Safety and efficacy of 90Y radiotherapy for hepatocellular carcinoma with and without portal vein thrombosis. *Hepatology* 2008;47:71-81.
  - ▶ Ricke J, Klumpen HJ, Amthauer H, et al. Impact of combined selective internal radiation therapy and sorafenib on survival in advanced hepatocellular carcinoma. *J Hepatol* 2019;71:1164-1174.

#### [HCC-F \(1 of 2\)](#)

- Treatment Modalities
  - ▶ 1st paragraph heading modified, "*External Beam Radiation Therapy.*"
  - ▶ 1st bullet, sub-bullet 6 revised, "SBRT (~~1-5 fractions~~) *typically 3-5 fractions is...*"
- Bullet 2, revised, "~~Dosing for EBRT is generally 30-50 Gy in 3-5 fractions, depending on the ability to meet normal organ constraints and underlying liver function. Other hypofractionated schedules >5 fractions may also be used if clinically indicated.~~"

- ◊ New tertiary bullet 1 added, "Initial volumes to 45 Gy in 1.8 Gy per fraction."
- ◊ New tertiary bullet 2 added, "Boost to 50 to 60 Gy in 1.8-2 Gy per fraction."

- ▶ Sub-bullet 2 revised, "~~Dosing for SBRT.~~"

- ◊ Tertiary bullet 1 revised, "~~is generally 30-50 Gy (typically in 3-5 fractions)...~~"

#### [HCC-G \(1 of 2\)](#)

- First-Line Therapy
  - ▶ Preferred Regimens: Sorafenib and lenvatinib have been moved under, "Other Recommended Regimens."
  - ▶ Under Useful in Certain Circumstances: The nivolumab recommendation was revised to include (*Child-Pugh Class A or B*)
- Subsequent-Line Therapy If Disease Progression
  - ▶ The following were moved from the list of "Options" to under "Other Recommended Regimens."
    - ◊ Nivolumab (*Child-Pugh Class A or B*);
    - ◊ Nivolumab + ipilimumab (*Child-Pugh Class A only*);
    - ◊ Pembrolizumab (*Child-Pugh Class A only*) (*category 2B*)
- Footnotes
  - ▶ Footnote c added, "Patients on atezolizumab + bevacizumab should have adequate endoscopic evaluation and management for esophageal varices within approximately 6 months prior to treatment or according to institutional practice and based on the assessment of bleeding risk."
  - ▶ 2nd bullet, sub-bullet 1 added, "Tumor mutational burden (TMB) testing." (Also INTRA-1, EXTRA-1)
  - ▶ Footnote i revised, "The data reflect use on or after sorafenib in patients who previously tolerated sorafenib at a dose of at least 400 mg per day." Footnote j revised, "For patients who have not been previously treated with a checkpoint inhibitor *because there is a lack of data for subsequent use of immunotherapy in patients who have previously been treated with a checkpoint inhibitor.*"
  - ▶ Footnote k added, "Consider if MSI-H HCC."

[Continued](#)

UPDATES

**Updates in Version 1.2021 of the NCCN Guidelines for Hepatobiliary Cancers from Version 5.2020 include:****GALL-1**

- Postoperative Workup
  - 4th column: Unresectable, 2nd bullet revised, **Consider Additional molecular testing.** (Also on GALL-2, GALL-3, GALL-4, INTRA-1, EXTRA-1)."
- Footnote
  - Footnote c revised, **"If there is evidence of For (high-risk) locoregionally advanced disease, (big mass invading liver and/or nodal disease, including cystic duct node positive), consideration to consider neoadjuvant chemotherapy should be given to largely to rule out rapid progression and avoid futile surgery. There are limited clinical trial data to define standard regimen or definitive benefit. See Principles of Systemic Therapy (BIL-C)." (Also on GALL-2, GALL-3, and GALL-4)."**

**GALL-A (2 of 2)**

- Mass on Imaging: Patients Presenting with Gallbladder Mass/ Disease Suspicious for Gallbladder Cancer:
  - 1st bullet revised, **"...carried out with *multiphasic* cross-sectional imaging..."**

**INTRA-1**

- Primary Treatment
  - Resectable pathway, 2nd bullet revised: Resection and *regional lymphadenectomy*.
    - ◊ Sub-bullet removed, **"Consider lymphadenectomy for accurate staging."**
- Footnote
  - Footnote e added, "ASCO Guidelines for management of viral HBV in cancer/chemo patients: <https://www.asco.org/sites/new-www.asco.org/files/content-files/advocacy-and-policy/documents/2020-HBV-PCO-Algorithm.pdf>."

**BIL-B**

- Unresectable
  - 1st sub-bullet revised, **"All tumors irrespective of the location may be amenable to *EBRT* radiation therapy (3D-CRT, IMRT, or SBRT)."**
  - 4th bullet revised, **"RT Dosing ~~Dosing~~ for SBRT for biliary tract tumors."**
    - ◊ New sub-bullet, **"EBRT."**
      - Tertiary bullet 1 new, **"Initial volumes to 45 Gy in 1.8 Gy**

fraction

- Tertiary bullet 2 new, **"Boost to 50 to 60 Gy in 1.8-2 Gy per fraction"**
- ◊ New sub-bullet, **"SBRT."**
  - Tertiary bullet 1, revised, **"Dosing is generally 30-50 Gy (typically in 3-5 fractions) depending ..."**
  - Tertiary bullet 3 revised, **"For intrahepatic tumors, SBRT in 1-5 fractions (typically 3-5 fractions) ..."**

**BIL-C (1 of 3)**

- Heading revised, **"Neoadjuvant Therapy (for gallbladder cancer only)."**
- Neoadjuvant Therapy; Other Recommended Regimens:
  - Removed the following regimens:
    - ◊ 5-fluorouracil + cisplatin (category 2B)
    - ◊ Capecitabine + cisplatin (category 2B)
- Adjuvant Therapy; Other Recommended Regimens
  - Removed: 5-fluorouracil + cisplatin (category 3)
  - Single agents: Gemcitabine (~~gallbladder and intrahepatic cholangiocarcinoma only~~)

**BIL-C (2 of 3)**

- Primary Treatment for Unresectable and Metastatic Disease
  - Other Recommended Regimens
    - ◊ 5-fluorouracil + cisplatin changed from category 2A to *category 2B recommendation*
    - ◊ Capecitabine + cisplatin changed from category 2A to *category 2B recommendation*
    - ◊ Gemcitabine + albumin-bound paclitaxel (~~cholangiocarcinoma only~~)
- Subsequent-line Therapy for Biliary Tract Cancers if Disease Progression
  - Useful in Certain Circumstances
    - ◊ 2nd bullet revised, **"For MSI-H/dMMR tumors/*TMB-H* tumors."**
    - ◊ 5th bullet added, **"For *BRAF*-V600E mutated tumors: Dabrafenib + trametinib."**
    - ◊ 6th bullet added, **"Nivolumab (category 2B)"**
    - ◊ 7th bullet added, **"Lenvatinib + pembrolizumab (category 2B)"**

**HEPATOCELLULAR CARCINOMA (HCC) SCREENING<sup>a</sup>****Patients at risk for HCC:<sup>b</sup>**

- **Cirrhosis<sup>c</sup>**
  - Hepatitis B, C<sup>d</sup>
  - Alcohol
  - Genetic hemochromatosis
  - Non-alcoholic fatty liver disease (NAFLD)<sup>d,e</sup>
  - Stage 4 primary biliary cholangitis<sup>f</sup>
  - Alpha-1-antitrypsin deficiency
  - Other causes of cirrhosis<sup>g</sup>
- **Without cirrhosis**
  - Hepatitis B<sup>c,h</sup>

Ultrasound (US)<sup>i</sup>  
+  
Alpha fetoprotein (AFP)<sup>a</sup>

AFP positive<sup>j</sup>  
or  
US nodule(s) ≥10 mm

Additional  
workup  
([See HCC-2](#))

US nodule(s) <10 mm → Repeat US + AFP in 3–6 mo

US negative<sup>k</sup> → Repeat US + AFP in 6 mo

<sup>a</sup> [See Principles of Imaging \(HCC-A\)](#).

<sup>b</sup> Adapted with permission from Marrero JA, et al. Hepatology 2018;68:723-750.

<sup>c</sup> Patients with cirrhosis or chronic hepatitis B viral infection should be enrolled in an HCC screening program ([See Discussion](#)).

<sup>d</sup> There is evidence suggesting improved outcomes for patients with HCC in the setting of NAFLD/HBV/HCV cirrhosis when the NAFLD/HBV/HCV is successfully treated. Referral to a hepatologist should be considered for the management of these patients.

<sup>e</sup> White DL, Clin Gastroenterol Hepatol 2012;10:1342-1359.

<sup>f</sup> Beuers U, et al. Am J Gastroenterol 2015;110:1536-1538.

<sup>g</sup> Schiff ER, Sorrell MF, and Maddrey WC. Schiff's Diseases of the Liver. Philadelphia: Lippincott Williams & Wilkins (LWW); 2007.

<sup>h</sup> Additional risk factors include HBV carrier with family history of HCC, Asian males ≥40 y, Asian females ≥50 y, and African/North American Blacks with hepatitis B.

<sup>i</sup> Most clinical practice guidelines recommend US for HCC screening. US exams should be done by qualified sonographers or physicians. Liver dynamic CT or dynamic MRI may be performed as an alternative to US if US fails to detect nodules or if visualization is poor. Korean Liver Cancer Association; National Cancer Center. Gut Liver 2019;13:227–299. ([See Principles of Imaging, HCC-A](#)).

<sup>j</sup> Positive or rising AFP should prompt CT or MRI regardless of US results.

<sup>k</sup> US negative means no observation or only definitely benign observation(s).

**Note:** All recommendations are category 2A unless otherwise indicated.

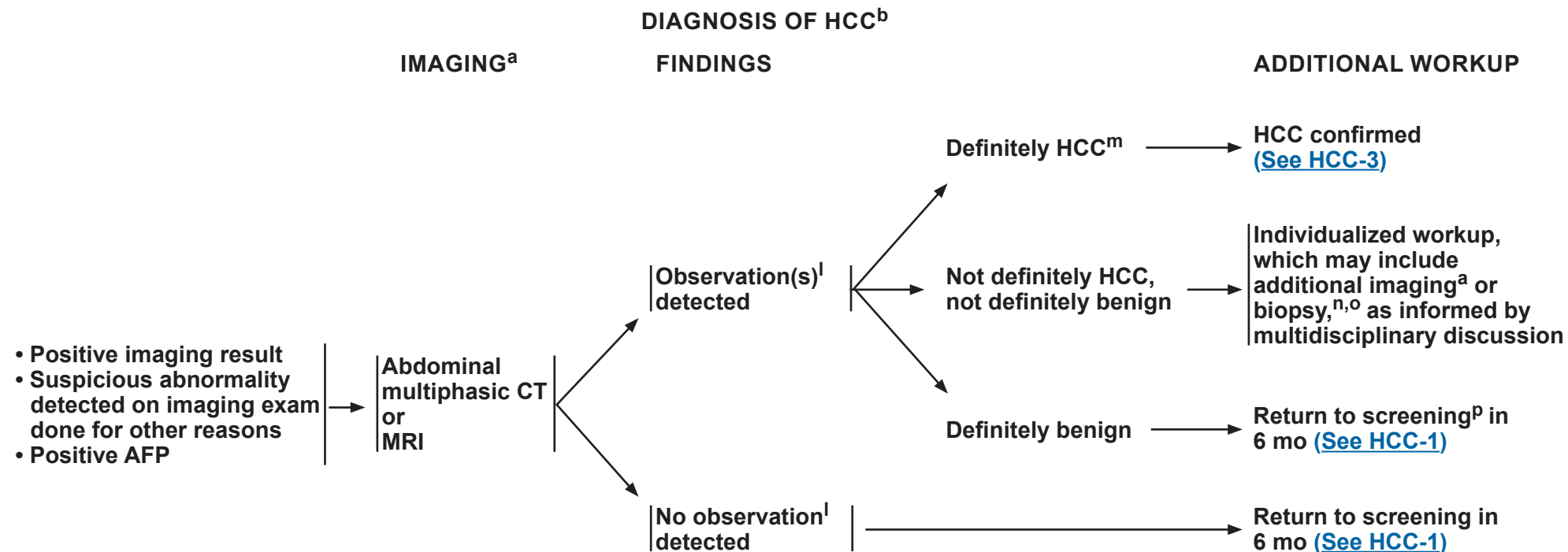
**Clinical Trials:** NCCN believes that the best management of any patient with cancer is in a clinical trial. Participation in clinical trials is especially encouraged.





# NCCN Guidelines Version 5.2021

## Hepatocellular Carcinoma



<sup>a</sup> [See Principles of Imaging \(HCC-A\)](#).

<sup>b</sup> Adapted with permission from Marrero JA, Kulik LM, Sirlin C, et al. Diagnosis, staging, and management of hepatocellular carcinoma: 2018 practice guidance by the American Association for the Study of Liver Diseases. Hepatology 2018;68:723-750.

<sup>l</sup> An observation is an area identified at imaging that is distinctive from background liver. It may be a mass or a pseudo lesion.

<sup>m</sup> Criteria for observations that are definitely HCC have been proposed by LI-RADS and adopted by AASLD. These criteria apply only to patients at high risk for HCC. OPTN has proposed imaging criteria for HCC applicable in candidates for liver transplant. [See Principles of Imaging \(HCC-A\)](#).

<sup>n</sup> Before biopsy, evaluate if patient is a resection or transplant candidate. If patient is a potential transplant candidate, consider referral to transplant center before biopsy.

<sup>o</sup> [See Principles of Biopsy \(HCC-B\)](#).

<sup>p</sup> If no observations are detected at diagnostic imaging despite positive surveillance tests, then return to surveillance in 6 months if the most reasonable explanation is that surveillance tests were false positive. Consider imaging with an alternative method +/- AFP if there is reasonable suspicion that the diagnostic imaging test was false negative.

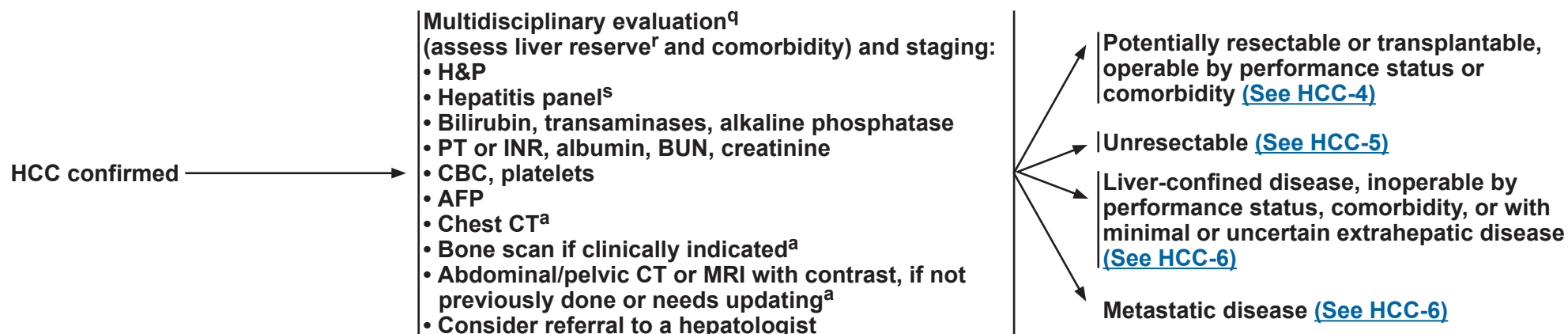
**Note:** All recommendations are category 2A unless otherwise indicated.

**Clinical Trials:** NCCN believes that the best management of any patient with cancer is in a clinical trial. Participation in clinical trials is especially encouraged.



## CLINICAL PRESENTATION

## WORKUP



<sup>a</sup> [See Principles of Imaging \(HCC-A\)](#).

<sup>q</sup> [See NCCN Guidelines for Older Adult Oncology](#).

<sup>r</sup> [See Child-Pugh Score \(HCC-C\)](#) and assessment of portal hypertension (eg, varices, splenomegaly, thrombocytopenia).

<sup>s</sup> An appropriate hepatitis panel should preferably include:

- Hepatitis B surface antigen (HBsAg). If the HBsAg is positive, check HBeAg, HBeAb, and quantitative HBV DNA and refer to hepatologist.
- Hepatitis B surface antibody (for vaccine evaluation only).
- Hepatitis B core antibody (HBcAb) IgG. The HBcAb IgM should only be checked in cases of acute viral hepatitis. An isolated HBcAb IgG may still be chronic HBV and should prompt testing for a quantitative HBV DNA.
- Hepatitis C antibody. If positive, check quantitative HCV RNA and HCV genotype and refer to hepatologist.

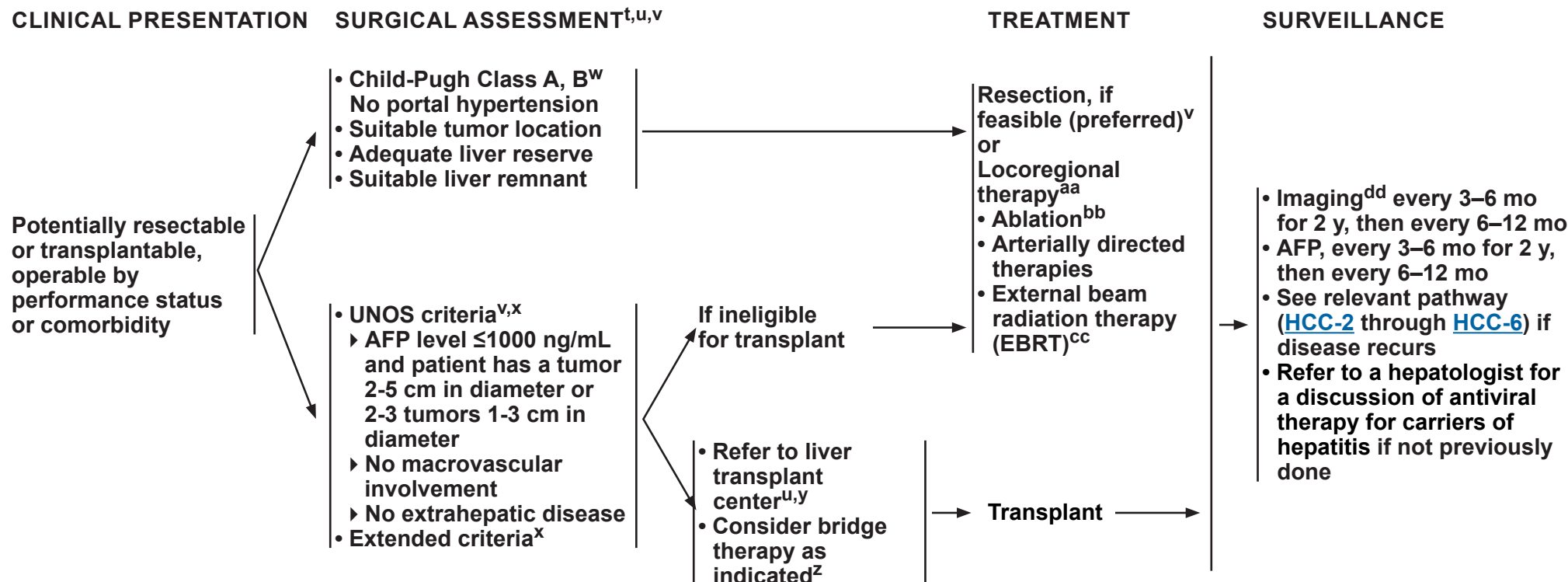
**Note:** All recommendations are category 2A unless otherwise indicated.

**Clinical Trials:** NCCN believes that the best management of any patient with cancer is in a clinical trial. Participation in clinical trials is especially encouraged.



# NCCN Guidelines Version 5.2021

## Hepatocellular Carcinoma



<sup>t</sup> Discussion of surgical treatment with patient and determination of whether patient is amenable to surgery.

<sup>u</sup> Patients with Child-Pugh Class A liver function, who fit UNOS criteria ([www.unos.org](http://www.unos.org)) and are resectable could be considered for resection or transplant. There is controversy over which initial strategy is preferable to treat such patients. These patients should be evaluated by a multidisciplinary team.

<sup>v</sup> [See Principles of Surgery \(HCC-D\)](#).

<sup>w</sup> In highly selected Child-Pugh Class B patients with limited resection.

<sup>x</sup> Extended criteria/downstaging protocols are available through UNOS. See [https://optn.transplant.hrsa.gov/media/1200/optn\\_policies.pdf#nameddest=Policy\\_09](https://optn.transplant.hrsa.gov/media/1200/optn_policies.pdf#nameddest=Policy_09).

<sup>y</sup> Mazzaferro V, et al. N Engl J Med 1996;334:693-700.

<sup>z</sup> Many transplant centers consider bridge therapy for transplant candidates ([See Discussion](#)).

<sup>aa</sup> [See Principles of Locoregional Therapy \(HCC-E\)](#).

<sup>bb</sup> In well-selected patients with small, properly located tumors ablation should be considered as definitive treatment in the context of a multidisciplinary review.

<sup>cc</sup> [See Principles of Radiation Therapy \(HCC-F\)](#).

<sup>dd</sup> Multiphasic abdominal MRI or multiphase CT scans for liver assessment, CT chest and CT/MRI pelvis. [See Principles of Imaging \(HCC-A\)](#).

**Note:** All recommendations are category 2A unless otherwise indicated.

**Clinical Trials:** NCCN believes that the best management of any patient with cancer is in a clinical trial. Participation in clinical trials is especially encouraged.

For relapse, [see Initial Workup \(HCC-3\)](#)



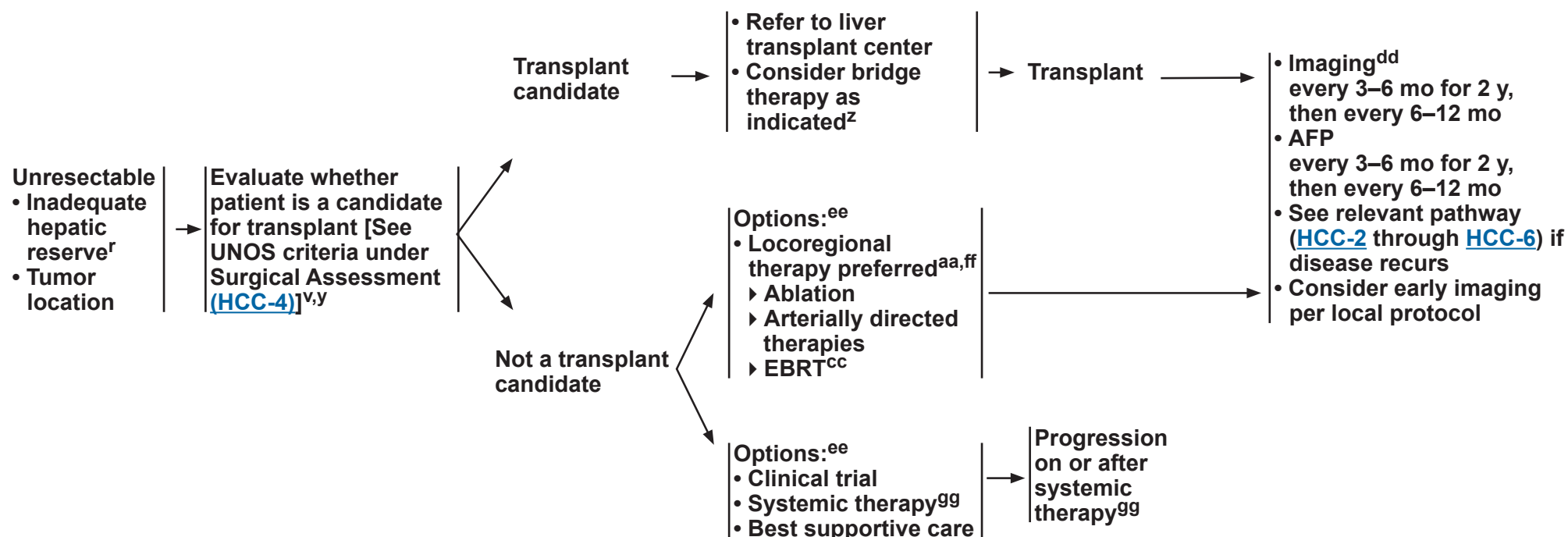
# NCCN Guidelines Version 5.2021

## Hepatocellular Carcinoma

### CLINICAL PRESENTATION

### TREATMENT

### SURVEILLANCE

<sup>r</sup> See [Child-Pugh Score \(HCC-C\)](#) and assessment of portal hypertension (eg, varices, splenomegaly, thrombocytopenia).<sup>v</sup> See [Principles of Surgery \(HCC-D\)](#).<sup>y</sup> Mazzaferro V, et al. N Engl J Med 1996;334:693-700.<sup>z</sup> Many transplant centers consider bridge therapy for transplant candidates ([See Discussion](#)).<sup>aa</sup> See [Principles of Locoregional Therapy \(HCC-E\)](#).<sup>cc</sup> See [Principles of Radiation Therapy \(HCC-F\)](#).<sup>dd</sup> Multiphasic abdominal MRI or multiphase CT scans for liver assessment, CT chest and CT/MRI pelvis. See [Principles of Imaging \(HCC-A\)](#).<sup>ee</sup> Order does not indicate preference. The choice of treatment modality may depend on extent/location of disease, hepatic reserve, and institutional capabilities.<sup>ff</sup> Use of chemoembolization has also been supported by randomized controlled trials in selected populations over best supportive care.<sup>gg</sup> See [Principles of Systemic Therapy \(HCC-G\)](#).**Note:** All recommendations are category 2A unless otherwise indicated.**Clinical Trials:** NCCN believes that the best management of any patient with cancer is in a clinical trial. Participation in clinical trials is especially encouraged.



### CLINICAL PRESENTATION

### TREATMENT

**Liver-confined disease, inoperable by performance status, comorbidity or with minimal or uncertain extrahepatic disease**



- Options:<sup>ee</sup>**
- **Locoregional therapy preferred<sup>aa</sup>**
    - **Ablation**
    - **Arterially directed therapies**
    - **EBRT<sup>cc</sup>**
  - **Clinical trial**
  - **Systemic therapy<sup>gg</sup>**
  - **Best supportive care**



**Progression on or after systemic therapy<sup>gg</sup>**

**Metastatic disease or Extensive liver tumor burden**



**Biopsy<sup>o</sup> for histologic confirmation if not previously done**



- Options:<sup>ee</sup>**
- **Clinical trial**
  - **Systemic therapy<sup>gg</sup>**
  - **Best supportive care**



**Progression on or after systemic therapy<sup>gg</sup>**

<sup>o</sup> [See Principles of Biopsy \(HCC-B\).](#)

<sup>aa</sup> [See Principles of Locoregional Therapy \(HCC-E\).](#)

<sup>cc</sup> [See Principles of Radiation Therapy \(HCC-F\).](#)

<sup>ee</sup> Order does not indicate preference. The choice of treatment modality may depend on extent/location of disease, hepatic reserve, and institutional capabilities.

<sup>gg</sup> [See Principles of Systemic Therapy \(HCC-G\).](#)

**Note:** All recommendations are category 2A unless otherwise indicated.

**Clinical Trials:** NCCN believes that the best management of any patient with cancer is in a clinical trial. Participation in clinical trials is especially encouraged.





## PRINCIPLES OF IMAGING

### Screening and Surveillance

Screening and surveillance for HCC is considered cost effective in patients with cirrhosis of any cause and patients with chronic hepatitis B (CHB) even in the absence of cirrhosis.<sup>1,2</sup> The recommended screening and surveillance imaging method is US, and the recommended interval is every 6 months.<sup>1,2</sup> Liver dynamic CT or dynamic MRI are more sensitive than US for HCC detection,<sup>3</sup> but they are more costly. They may be performed as an alternative to US if US fails to detect nodules or if visualization is poor (see below).<sup>4</sup> Serum biomarkers such as AFP may incrementally improve the performance of imaging-based screening and surveillance.

### Imaging Diagnosis of HCC

- After a positive screening or surveillance test or after lesions are detected incidentally on routine imaging studies done for other reasons, multiphasic abdominal CT or MRI studies with contrast are recommended to establish the diagnosis and stage the tumor burden in the liver. Optimal imaging technique depends on the modality and contrast agent, as summarized by LI-RADS.<sup>5</sup> To standardize interpretation, the AASLD,<sup>1</sup> EASL,<sup>2</sup> OPTN,<sup>6</sup> and LI-RADS<sup>5,7</sup> have adopted imaging criteria to diagnose HCC nodules ≥10 mm. Criteria have not been proposed for nodules smaller than 10 mm as these are difficult to definitively characterize at imaging. Major imaging features of HCC include arterial phase hyperenhancement, nonperipheral venous or delayed phase washout appearance, enhancing capsule appearance, and threshold growth.<sup>5,7</sup> LI-RADS also provides imaging criteria to diagnose major vascular invasion.<sup>5</sup> Having criteria for vascular invasion is necessary because the tumor in the vein may not have the same imaging features as parenchymal tumors.
- Importantly, imaging criteria for parenchymal nodules apply only to patients at high risk for developing HCC: namely, those with cirrhosis, CHB, or current or prior HCC. In these patients, the prevalence of HCC is sufficiently high that lesions meeting imaging criteria for HCC have close to a 100% probability of being HCC. The criteria do not apply to the general population or, except for CHB, to patients with chronic liver disease that has not progressed to cirrhosis. The criteria are designed to have high specificity for HCC; thus, lesions meeting these criteria can be assumed to represent HCC and may be treated as such without confirmatory biopsy. As a corollary, the criteria have modest sensitivity; thus, many HCCs do not satisfy the required criteria and failure to meet the criteria does not exclude HCC.<sup>5</sup>
- Lesions that do not meet the imaging criteria described above for HCC require individualized workup, which may include additional imaging or biopsy as informed by multidisciplinary discussion and are outlined in the treatment algorithms.
- Quality of MRI is dependent on patient compliance.

### Extrahepatic Staging

- Frequent sites of extrahepatic metastases from HCC include lungs, bone, and lymph nodes. Adrenal and peritoneal metastases also may occur. For this reason, chest CT, complete imaging of abdomen and pelvis with contrast-enhanced CT or MRI, and selective use of bone scan<sup>8</sup> when skeletal symptoms are present are recommended at initial diagnosis of HCC and for monitoring disease while on the transplant wait list or during or after treatment for response assessment. Chest CT may be performed with contrast if concurrently acquired with contrast-enhanced abdominal/pelvic CT. If MRI is performed, chest CT may be acquired without contrast.

**Note:** All recommendations are category 2A unless otherwise indicated.

**Clinical Trials:** NCCN believes that the best management of any patient with cancer is in a clinical trial. Participation in clinical trials is especially encouraged.

## References



## PRINCIPLES OF IMAGING

### Imaging Diagnosis of iCCA and cHCC-CCA

Patients at risk for HCC due to cirrhosis, CHB, or other conditions are also at elevated risk for developing non-HCC primary hepatic malignancies such as intrahepatic cholangiocarcinoma (iCCA) and combined HCC-cholangiocarcinoma (cHCC-CCA). Although iCCAs and cHCC-CCAs tend to have malignant imaging features, the features are not sufficiently specific to permit noninvasive diagnosis.<sup>7,9</sup> Biopsy or definitive resection usually is necessary to make a diagnosis.

### Imaging Protocol for Response Assessment After Treatment

CT of the chest and multiphasic CT or MRI of the abdomen and pelvis are the preferred modalities as they reliably assess intranodular arterial vascularity, a key feature of residual or recurrent tumor. Overall nodule size does not reliably indicate treatment response since a variety of factors may cause a successfully treated lesion to appear stable in size or even larger after treatment.

### Role of CEUS

Contrast-enhanced US (CEUS) is considered a problem-solving tool for use at select centers with the relevant expertise for characterization of indeterminate nodules. It is not suitable for whole-liver assessment, surveillance, or cancer staging.<sup>10</sup>

### Role of PET

PET/CT has limited sensitivity but high specificity, and may be considered when there is an equivocal finding.<sup>11</sup> When an HCC is detected by CT or MRI and has increased metabolic activity on PET/CT, higher intralesional standardized uptake value (SUV) is a marker of biologic aggressiveness and might predict less optimal response to locoregional therapies.<sup>12</sup>

**Note:** All recommendations are category 2A unless otherwise indicated.

**Clinical Trials:** NCCN believes that the best management of any patient with cancer is in a clinical trial. Participation in clinical trials is especially encouraged.

## [References](#)



### PRINCIPLES OF IMAGING REFERENCES

- <sup>1</sup> Marrero JA, Kulik LM, Sirlin C, et al. Diagnosis, staging, and management of hepatocellular carcinoma: 2018 Practice Guidance by the American Association for the Study of Liver Diseases. *Hepatology* 2018;68:723-750.
- <sup>2</sup> European Association for the Study of the Liver, European Organisation for Research and Treatment of Cancer. EASL-EORTC clinical practice guidelines: management of hepatocellular carcinoma. *J Hepatol* 2012;56:908-943.
- <sup>3</sup> Colli A, Fraquelli M, Casazza G, et al. Accuracy of ultrasonography, spiral CT, magnetic resonance, and alpha-fetoprotein in diagnosing hepatocellular carcinoma: a systematic review. *Am J Gastroenterol* 2006;101:513-23.
- <sup>4</sup> Korean Liver Cancer Association; National Cancer Center. 2018 Korean Liver Cancer Association-National Cancer Center Korea Practice Guidelines for the Management of Hepatocellular Carcinoma. *Gut Liver* 2019;13(3):227-299.
- <sup>5</sup> ACR. American College of Radiology (ACR) Liver Imaging Reporting And Data System (LI-RADS) v2017 2018 [cited 2018 May 28]. Available from: <http://www.acr.org/Quality-Safety/Resources/LIRADS>.
- <sup>6</sup> Pomfret EA, Washburn K, Wald C, et al. Report of a national conference on liver allocation in patients with hepatocellular carcinoma in the United States. *Liver Transpl* 2010;16:262-78.
- <sup>7</sup> Fowler KJ, Potretzke TA, Hope TA, et al. LI-RADS M (LR-M): definite or probable malignancy, not specific for hepatocellular carcinoma. *Abdom Radiol (NY)* 2018; 43:149-157.
- <sup>8</sup> Harding JJ, Abu-Zeinah G, Chour JF, et al. Frequency, morbidity, and mortality of bone metastases in advanced hepatocellular carcinoma. *J Natl Compr Canc Netw* 2018;16:50-58.
- <sup>9</sup> Choi JY, Lee JM, Sirlin CB. CT and MR imaging diagnosis and staging of hepatocellular carcinoma: part II. Extracellular agents, hepatobiliary agents, and ancillary imaging features. *Radiology* 2014;273:30-50.
- <sup>10</sup> Claudon M, Dietrich CF, Choi BI, et al. Guidelines and good clinical practice recommendations for Contrast Enhanced Ultrasound (CEUS) in the liver - update 2012: A WFUMB-EFSUMB initiative in cooperation with representatives of AFSUMB, AIUM, ASUM, FLAUS and ICUS. *Ultrasound Med Biol* 2013;39:187-210.
- <sup>11</sup> Lamarca A, Barriuso J, Chander A, et al. <sup>18</sup>F-fluorodeoxyglucose positron emission tomography (<sup>18</sup>FDG-PET) for patients with biliary tract cancer: Systematic review and meta-analysis. *J Hepatol* 2019;71:115-129.
- <sup>12</sup> Sun DW, An L, Wei F, et al. Prognostic significance of parameters from pretreatment (18)F-FDG PET in hepatocellular carcinoma: a meta-analysis. *Abdom Radiol (NY)* 2016;41:33-41.

**Note:** All recommendations are category 2A unless otherwise indicated.

**Clinical Trials:** NCCN believes that the best management of any patient with cancer is in a clinical trial. Participation in clinical trials is especially encouraged.



### PRINCIPLES OF BIOPSY

Indicators for consideration of biopsy, which may include:

- **Initial biopsy**

- ▶ Lesion is highly suspicious for malignancy at multiphasic CT or MRI but does not meet imaging criteria<sup>a</sup> for HCC.
- ▶ Lesion meets imaging criteria<sup>1</sup> for HCC but:
  - ◊ Patient is not considered at high risk for HCC development (ie, does not have cirrhosis, CHB, or current or prior HCC).
  - ◊ Patient has cardiac cirrhosis, congenital hepatic fibrosis, or cirrhosis due to a vascular disorder such as Budd-Chiari syndrome, hereditary hemorrhagic telangiectasia, or nodular regenerative hyperplasia.<sup>b</sup>
  - ◊ Patient has elevated CA 19-9 or carcinoembryonic antigen (CEA) with suspicion of intrahepatic cholangiocarcinoma or cHCC-CCA.
- ▶ Confirmation of metastatic disease could change clinical decision-making including enrollment in clinical trials.
- ▶ Surgical resection without biopsy should be considered with multidisciplinary review.

- **Repeat biopsy**

- ▶ Non-diagnostic biopsy
- ▶ Prior biopsy discordant with imaging, biomarkers, or other factors

<sup>a</sup> Imaging criteria for HCC have been proposed by LI-RADS and adopted by AASLD. These criteria apply only to patients at high risk for HCC. OPTN has proposed imaging criteria for HCC applicable in liver transplant candidates. [See Principles of Imaging \(HCC-A\)](#).

<sup>b</sup> These conditions are associated with formation of nonmalignant nodules that may resemble HCC at imaging.

**Note:** All recommendations are category 2A unless otherwise indicated.

**Clinical Trials:** NCCN believes that the best management of any patient with cancer is in a clinical trial. Participation in clinical trials is especially encouraged.



# NCCN Guidelines Version 5.2021

## Hepatocellular Carcinoma

### CHILD-PUGH SCORE

Chemical and Biochemical Parameters	Scores (Points) for Increasing Abnormality		
	1	2	3
Encephalopathy (grade) <sup>1</sup>	None	1–2	3–4
Ascites	Absent	Slight	Moderate
Albumin (g/dL)	>3.5	2.8–3.5	<2.8
Prothrombin time <sup>2</sup>			
Seconds over control	<4	4–6	>6
INR	<1.7	1.7–2.3	>2.3
Bilirubin (mg/dL)	<2	2–3	>3
• For primary biliary cirrhosis	<4	4–10	>10

**Class A = 5–6 points; Class B = 7–9 points; Class C = 10–15 points.**

**Class A: Good operative risk**

**Class B: Moderate operative risk**

**Class C: Poor operative risk**

<sup>1</sup> Trey C, Burns DG, Saunders SJ. Treatment of hepatic coma by exchange blood transfusion. N Engl J Med 1966;274:473-481.

<sup>2</sup> Van Rijn JL, Schmidt NA, Rutten WP. Correction of instrument- and reagent-based differences in determination of the International Normalized Ratio (INR) for monitoring anticoagulant therapy. Clin Chem 1989;35:840-843.

Source: Pugh R, Murray-Lyon I, Dawson J, et al: Transection of the oesophagus for bleeding oesophageal varices. Br J of Surg 1973;60:646-649. ©British Journal of Surgery Society Ltd. Adapted with permission. Permission is granted by John Wiley & Sons Ltd on behalf of the BJSS Ltd.

**Note:** All recommendations are category 2A unless otherwise indicated.

**Clinical Trials:** NCCN believes that the best management of any patient with cancer is in a clinical trial. Participation in clinical trials is especially encouraged.



**PRINCIPLES OF SURGERY**

- Patients must be medically fit for a major operation.
- Hepatic resection is indicated as a potentially curative option in the following circumstances:
  - ▶ Adequate liver function (generally Child-Pugh Class A without portal hypertension, but small series show feasibility of limited resections in patients with mild portal hypertension)<sup>1</sup>
  - ▶ Solitary mass without major vascular invasion
  - ▶ Adequate future liver remnant (FLR) (at least 20% without cirrhosis and at least 30%–40% with Child-Pugh Class A cirrhosis, adequate vascular and biliary inflow/outflow)
- Hepatic resection is controversial in the following circumstances, but can be considered:
  - ▶ Limited and resectable multifocal disease
  - ▶ Major vascular invasion
- For patients with chronic liver disease being considered for major resection, preoperative portal vein embolization should be considered.<sup>2</sup>
- Patients meeting the United Network for Organ Sharing (UNOS) criteria ([AFP level ≤1000 ng/mL and single lesion ≥2 cm and ≤5 cm, or 2 or 3 lesions ≥1 cm and ≤3 cm] [www.unos.org](http://www.unos.org)) should be considered for transplantation (cadaveric or living donation).
- The Model for End-Stage Liver Disease (MELD) score is used by UNOS to assess the severity of liver disease and prioritize the allocation of the liver transplants.<sup>3,5</sup> MELD score can be determined using the MELD calculator: <https://optn.transplant.hrsa.gov/resources/allocation-calculators/meld-calculator/>. There are patients whose tumor characteristics are marginally outside of the UNOS guidelines who should be considered for transplant.<sup>3</sup> Furthermore, there are patients who are downstaged to within criteria that can also be considered for transplantation.<sup>4</sup> Candidates are eligible for a standardized MELD exception if, before completing locoregional therapy, they have lesions that meet *one* of the following criteria:
  - ▶ One lesion >5 cm and ≤8 cm
  - ▶ 2 or 3 lesions that meet all of the following:
    - ◊ Each lesion ≤5 cm, with at least one lesion >3 cm
    - ◊ A total diameter of all lesions ≤8 cm
  - ▶ 4 or 5 lesions each <3 cm, and a total diameter of all lesions ≤8 cm.
  - ▶ For more information, see: [https://optn.transplant.hrsa.gov/media/1200/optn\\_policies.pdf#nameddest=Policy\\_09](https://optn.transplant.hrsa.gov/media/1200/optn_policies.pdf#nameddest=Policy_09)
- Patients with Child-Pugh Class A liver function, who fit UNOS criteria and are resectable, could be considered for resection or transplant. There is controversy over which initial strategy is preferable to treat such patients. These patients should be evaluated by a multidisciplinary team.
- Based on retrospective analyses, older patients may benefit from liver resection or transplantation for HCC, but they need to be carefully selected, as overall survival is lower than for younger patients.<sup>6</sup>

<sup>1</sup> Santambrogio R, Kluger MD, Costa M, et al. Hepatic resection for hepatocellular carcinoma in patients with Child-Pugh's A cirrhosis: Is clinical evidence of portal hypertension a contraindication? HPB (Oxford) 2013;15:78-84.

<sup>2</sup> Brouquet A, Andreou A, Shindoh J, et al. Methods to improve resectability of hepatocellular carcinoma. Recent Results Cancer Res. 2013;190:57-67.

<sup>3</sup> Heimbach, JK. Evolution of Liver Transplant Selection Criteria and U.S. Allocation Policy for Patients with Hepatocellular Carcinoma, Semin Liver Dis (2020) [Epub ahead of print].

<sup>4</sup> Rudnick SR, Russo MW. Liver transplantation beyond or downstaging within the Milan criteria for hepatocellular carcinoma. Expert Rev Gastroenterol Hepatol 2018;12:265-275.

<sup>5</sup> Kamath PS, Wiesner RH, Malinchoc M, et al. A model to predict survival in patients with end-stage liver disease. Hepatology 2001;33:464-570.

<sup>6</sup> Faber W, Stockmann M, Schirmer C, et al. Significant impact of patient age on outcome after liver resection for HCC cirrhosis. Eur J Surg Oncol 2014;40:208-213.

**Note:** All recommendations are category 2A unless otherwise indicated.

**Clinical Trials:** NCCN believes that the best management of any patient with cancer is in a clinical trial. Participation in clinical trials is especially encouraged.

**PRINCIPLES OF LOCOREGIONAL THERAPY****I. General Principles**

- All patients with HCC should be evaluated for potential curative therapies (resection, transplantation, and for small lesions, ablative strategies). Locoregional therapy should be considered in patients who are not candidates for surgical curative treatments, or as a part of a strategy to bridge patients for other curative therapies. These are broadly categorized into ablation, arterially directed therapies, and radiotherapy.

**II. Treatment Information****A. Ablation (radiofrequency, cryoablation, percutaneous alcohol injection, microwave):**

- All tumors should be amenable to ablation such that the tumor and, in the case of thermal ablation, a margin of normal tissue is treated. A margin is not expected following percutaneous ethanol injection.
- Tumors should be in a location accessible for percutaneous/laparoscopic/open approaches for ablation.
- Caution should be exercised when ablating lesions near major vessels, major bile ducts, diaphragm, and other intra-abdominal organs.
- Ablation alone may be curative in treating tumors  $\leq 3$  cm. In well-selected patients with small properly located tumors, ablation should be considered as definitive treatment in the context of a multidisciplinary review. Lesions 3 to 5 cm may be treated to prolong survival using arterially directed therapies, or with combination of an arterially directed therapy and ablation as long as tumor location is accessible for ablation.<sup>1-3</sup>
- Unresectable/inoperable lesions  $> 5$  cm should be considered for treatment using arterially directed therapy, systemic therapy, or EBRT.<sup>4-6</sup>
- Sorafenib should not be used as adjuvant therapy post-ablation.<sup>7</sup>

**B. Arterially Directed Therapies:**

- All tumors irrespective of location may be amenable to arterially directed therapies provided that the arterial blood supply to the tumor may be isolated without excessive non-target treatment.
- Arterially directed therapies include bland transarterial embolization (TAE),<sup>4,5,8,9</sup> chemoembolization (transarterial chemoembolization [TACE]<sup>10</sup> and TACE with drug-eluting beads [DEB-TACE]<sup>4,11</sup>), and radioembolization (RE) with yttrium-90 (Y-90) microspheres.<sup>12,13</sup>
- All arterially directed therapies are relatively contraindicated in patients with bilirubin  $> 3$  mg/dL unless segmental treatment can be performed.<sup>14</sup> RE with Y-90 microspheres has an increased risk of radiation-induced liver disease in patients with bilirubin  $> 2$  mg/dL.<sup>13</sup>
  - With RE, delivery of  $\geq 205$  Gy to the tumor may be associated with increased overall survival.<sup>18</sup>
- Arterially directed therapies in highly selected patients have been shown to be safe in the presence of limited tumor invasion of the portal vein.
  - Randomized controlled trials have shown that Y-90 is not superior to sorafenib for treating advanced HCC. RE may be appropriate in some patients with advanced HCC,<sup>19,20</sup> specifically patients with segmental or lobar portal vein, rather than main portal vein thrombosis.<sup>22</sup>
- Sorafenib may be appropriate following arterially directed therapies in patients with adequate liver function once bilirubin returns to baseline if there is evidence of residual/recurrent tumor not amenable to additional local therapies. The safety and efficacy of the use of sorafenib concomitantly with arterially directed therapies has not been associated with significant benefit in three randomized trials; other randomized phase III trials are ongoing to investigate other systemic therapies including immunotherapy in combination with arterial therapies.<sup>15-17,22</sup>

Note: All recommendations are category 2A unless otherwise indicated.

Clinical Trials: NCCN believes that the best management of any patient with cancer is in a clinical trial. Participation in clinical trials is especially encouraged.

**References**

**PRINCIPLES OF LOCOREGIONAL THERAPY  
REFERENCES**

- <sup>1</sup> Chen MS, Li JQ, Zheng Y, et al. A prospective randomized trial comparing percutaneous local ablative therapy and partial hepatectomy for small hepatocellular carcinoma. *Ann Surg* 2006;243:321-328.
- <sup>2</sup> Feng K, Yan J, Li X, et al. A randomized controlled trial of radiofrequency ablation and surgical resection in the treatment of small hepatocellular carcinoma. *J Hepatol* 2012;57:794-802.
- <sup>3</sup> Peng ZW, Zhang YJ, Liang HH, et al. Recurrent hepatocellular carcinoma treated with sequential transcatheter arterial chemoembolization and RF ablation versus RF ablation alone: a prospective randomized trial. *Radiology* 2012;262:689-700.
- <sup>4</sup> Malagari K, Pomoni M, Kelekis A, et al. Prospective randomized comparison of chemoembolization with doxorubicin-eluting beads and bland embolization with BeadBlock for hepatocellular carcinoma. *Cardiovasc Intervent Radiol* 2010;33:541-551.
- <sup>5</sup> Maluccio M, Covey AM, Gandhi R, et al. Comparison of survival rates after bland arterial embolization and ablation versus surgical resection for treating solitary hepatocellular carcinoma up to 7 cm. *J Vasc Interv Radiol* 2005;16:955-961.
- <sup>6</sup> Yamakado K, Nakatsuka A, Takaki H, et al. Early-stage hepatocellular carcinoma: radiofrequency ablation combined with chemoembolization versus hepatectomy. *Radiology* 2008;247:260-266.
- <sup>7</sup> Bruix J, Takayama T, Mazzaferro V, et al. Adjuvant sorafenib for hepatocellular carcinoma after resection or ablation (STORM): a phase 3, randomised, double-blind, placebo-controlled trial. *Lancet Oncol* 2015;16:1344-1354.
- <sup>8</sup> Brown KT, Do RT, Gonen M, et al. Randomized trial of hepatic artery embolization for hepatocellular carcinoma using doxorubicin-eluting microspheres compared with embolization with microspheres alone. *J Clin Oncol* 2016;34:2046-2053.
- <sup>9</sup> Maluccio MA, Covey AM, Porat LB, et al. Transcatheter arterial embolization with only particles for the treatment of unresectable hepatocellular carcinoma. *J Vasc Interv Radiol* 2008;19:862-869.
- <sup>10</sup> Llovet JM, Real MI, Montana X, et al. Arterial embolisation or chemoembolisation versus symptomatic treatment in patients with unresectable hepatocellular carcinoma: a randomised controlled trial. *Lancet* 2002;359:1734-1739.
- <sup>11</sup> Lammer J, Malagari K, Vogl T, et al. Prospective randomized study of doxorubicin-eluting-bead embolization in the treatment of hepatocellular carcinoma: results of the PRECISION V study. *Cardiovasc Intervent Radiol* 2010;33:41-52.
- <sup>12</sup> Kulik LM, Carr BI, Mulcahy MF, et al. Safety and efficacy of 90Y radiotherapy for hepatocellular carcinoma with and without portal vein thrombosis. *Hepatology* 2008;47:71-81.
- <sup>13</sup> Salem R, Lewandowski RJ, Mulcahy MF, et al. Radioembolization for hepatocellular carcinoma using Yttrium-90 microspheres: a comprehensive report of long-term outcomes. *Gastroenterology* 2010;138:52-64.
- <sup>14</sup> Ramsey DE, Kernagis LY, Soulen MC, Geschwind J-FH. Chemoembolization of hepatocellular carcinoma. *J Vasc Interv Radiol* 2002;13:211-221.
- <sup>15</sup> Kudo M, Imanaka K, Chida N, et al. Phase III study of sorafenib after transarterial chemoembolization in Japanese and Korean patients with unresectable hepatocellular carcinoma. *Eur J Cancer*. 2011;47:2117-2127.
- <sup>16</sup> Lencioni R, Llovet JM, Han G, et al. Sorafenib or placebo plus TACE with doxorubicin-eluting beads for intermediate stage HCC: the SPACE trial. *J Hepatol* 2016;64:1090-1098.
- <sup>17</sup> Pawlik TM, Reyes DK, Cosgrove D, et al. Phase II trial of sorafenib combined with concurrent transarterial chemoembolization with drug-eluting beads for hepatocellular carcinoma. *J Clin Oncol* 2011;29:3960-3967.
- <sup>18</sup> Garin E, Tselikas L, Guiu B, et al and the DOSISPHERE-01 Study Group. Personalised versus standard dosimetry approach of selective internal radiation therapy in patients with locally advanced hepatocellular carcinoma (DOSISPHERE-01): a randomised, multicentre, open-label phase 2 trial. *Lancet Gastroenterol Hepatol* 2021;6:17-29.
- <sup>19</sup> Vilgrain V, Pereira H, Assenat E, et al. Efficacy and safety of selective internal radiotherapy with yttrium-90 resin microspheres compared with sorafenib in locally advanced and inoperable hepatocellular carcinoma (SARAH): an open-label randomised controlled phase 3 trial. *Lancet Oncol* 2017;18:1624-36.
- <sup>20</sup> Chow PKH, Gandhi M, Tan SB, et al. SIRveNIB: Selective Internal Radiation Therapy Versus Sorafenib in Asia-Pacific Patients With Hepatocellular Carcinoma. *J Clin Oncol* 2018;36:1913-21.
- <sup>21</sup> Kulik LM, Carr BI, Mulcahy MF, et al. Safety and efficacy of 90Y radiotherapy for hepatocellular carcinoma with and without portal vein thrombosis. *Hepatology* 2008;47:71-81.
- <sup>22</sup> Ricke J, Klumpen HJ, Amthauer H, et al. Impact of combined selective internal radiation therapy and sorafenib on survival in advanced hepatocellular carcinoma. *J Hepatol* 2019;71:1164-1174.

**Note:** All recommendations are category 2A unless otherwise indicated.**Clinical Trials:** NCCN believes that the best management of any patient with cancer is in a clinical trial. Participation in clinical trials is especially encouraged.



### PRINCIPLES OF RADIATION THERAPY

#### External Beam Radiation Therapy:

##### • Treatment Modalities:

- ▶ EBRT is a treatment option for patients with unresectable disease, or for those who are medically inoperable due to comorbidity.
- ▶ All tumors irrespective of the location may be amenable to radiation therapy (RT) (3D conformal RT (3D-CRT), intensity-modulated RT [IMRT], or stereotactic body RT [SBRT]). Image-guided RT (IGRT) is strongly recommended when using EBRT, IMRT, and SBRT to improve treatment accuracy and reduce treatment-related toxicity.
- ▶ Hypofractionation with photons<sup>1</sup> or protons<sup>2,3</sup> is an acceptable option for intrahepatic tumors, though treatment at centers with experience is recommended.
- ▶ SBRT is an advanced technique of hypofractionated EBRT with photons that delivers large ablative doses of radiation.
- ▶ There is growing evidence for the usefulness of SBRT in the management of patients with HCC.<sup>4,5</sup> SBRT can be considered as an alternative to ablation/embolization techniques or when these therapies have failed or are contraindicated.
- ▶ SBRT (typically 3–5 fractions) is often used for patients with 1 to 3 tumors. SBRT could be considered for larger lesions or more extensive disease, if there is sufficient uninvolved liver and liver radiation tolerance can be respected. There should be no extrahepatic disease or it should be minimal and addressed in a comprehensive management plan. The majority of data on radiation for HCC liver tumors arises from patients with Child-Pugh A liver disease; safety data are limited for patients with Child-Pugh B or poorer liver function. Those with Child-Pugh B cirrhosis can be safely treated, but they may require dose modifications and strict dose constraint adherence.<sup>6</sup> The safety of liver radiation for HCC in patients with Child-Pugh C cirrhosis has not been established, as there are not likely to be clinical trials available for Child-Pugh C patients.<sup>7,8</sup>
- ▶ Proton beam therapy (PBT) may be appropriate in specific situations.<sup>9,10</sup>
- ▶ Palliative EBRT is appropriate for symptom control and/or prevention of complications from metastatic HCC lesions, such as bone or brain.

##### • RT Dosing:

- ▶ EBRT:
  - ◊ Initial volumes to 45 Gy in 1.8 Gy per fraction
  - ◊ Boost to 50 to 60 Gy in 1.8–2 Gy per fraction
- ▶ SBRT:
  - ◊ 30–50 Gy (typically in 3–5 fractions), depending on the ability to meet normal organ constraints and underlying liver function.
  - ◊ Other hypofractionated schedules >5 fractions may also be used if clinically indicated

**Note:** All recommendations are category 2A unless otherwise indicated.

**Clinical Trials:** NCCN believes that the best management of any patient with cancer is in a clinical trial. Participation in clinical trials is especially encouraged.

[See next page for  
References](#)



### PRINCIPLES OF RADIATION THERAPY REFERENCES

- <sup>1</sup> Tao R, Krishnan S, Bhosale PR, et al. Ablative radiotherapy doses lead to a substantial prolongation of survival in patients with inoperable intrahepatic cholangiocarcinoma: a retrospective dose response analysis. *J Clin Oncol* 2016;34:219-226.
- <sup>2</sup> Bush DA, Smith JC, Slater JD, et al. Randomized clinical trial comparing proton beam radiation therapy with transarterial chemoembolization for hepatocellular carcinoma: results of an interim analysis. *Int J Radiat Oncol Biol Phys* 2016;95:477-482.
- <sup>3</sup> Hong TS, Wo JY, Yeap BY, et al. Multi-institutional phase II study of high-dose hypofractionated proton beam therapy in patients with localized, unresectable hepatocellular carcinoma and intrahepatic cholangiocarcinoma. *J Clin Oncol* 2016;34:460-468.
- <sup>4</sup> Hoffe SE, Finkelstein SE, Russell MS, Shridhar R. Nonsurgical options for hepatocellular carcinoma: evolving role of external beam radiotherapy. *Cancer Control* 2010;17:100-110.
- <sup>5</sup> Wahl DR, Stenmark MH, Tao Y, et al. Outcomes after stereotactic body radiotherapy or radiofrequency ablation for hepatocellular carcinoma. *J Clin Oncol* 2016;34:452-459.
- <sup>6</sup> Cardenes HR, Price TR, Perkins SM, et al. Phase I feasibility trial of stereotactic body radiation therapy for primary hepatocellular carcinoma. *Clin Transl Oncol* 2010;12:218-225.
- <sup>7</sup> Andolino DL, Johnson CS, Maluccio M, et al. Stereotactic body radiotherapy for primary hepatocellular carcinoma. *Int J Radiat Oncol Biol Phys* 2011;81:e447-453.
- <sup>8</sup> Bujold A, Massey CA, Kim JJ, et al. Sequential phase I and II trials of stereotactic body radiotherapy for locally advanced hepatocellular carcinoma. *J Clin Oncol* 2013;31:1631-1639.
- <sup>9</sup> Proton Beam Therapy. American Society for Radiation Oncology, 2014. Available at: [http://www.astro.org/uploadedFiles/Main\\_Site/Practice\\_Management/Reimbursement/ASTRO%20PBT%20Model%20Policy%20FINAL.pdf](http://www.astro.org/uploadedFiles/Main_Site/Practice_Management/Reimbursement/ASTRO%20PBT%20Model%20Policy%20FINAL.pdf). Accessed 11/26/18.
- <sup>10</sup> Qi W, Fu S, Zhang Q, et al. Charged particle therapy versus photon therapy for patients with hepatocellular carcinoma: A systematic review and meta-analysis. *Radiother Oncol* 2015;114:289-295.

**Note:** All recommendations are category 2A unless otherwise indicated.

**Clinical Trials:** NCCN believes that the best management of any patient with cancer is in a clinical trial. Participation in clinical trials is especially encouraged.





### First-Line Systemic Therapy

Preferred Regimens	Other Recommended Regimens	Useful in Certain Circumstances
<ul style="list-style-type: none"> <li>• Atezolizumab + bevacizumab (Child-Pugh Class A only) (category 1)<sup>a,b,c,1</sup></li> </ul>	<ul style="list-style-type: none"> <li>• Sorafenib (Child-Pugh Class A) [category 1] or B7)<sup>d,e,2,3</sup></li> <li>• Lenvatinib (Child-Pugh Class A only)<sup>4,5</sup> (category 1)</li> </ul>	<ul style="list-style-type: none"> <li>• Nivolumab<sup>b,6</sup> (if ineligible for tyrosine kinase inhibitors [TKIs] or other anti-angiogenic agents) (Child-Pugh Class A or B) (category 2B)</li> <li>• FOLFOX (category 2B)<sup>f</sup></li> </ul>

Subsequent-Line Therapy <sup>g</sup> if Disease Progression <sup>h</sup>	Other Recommended Regimens	Useful in Certain Circumstances
<b>Options</b> <ul style="list-style-type: none"> <li>• Regorafenib (Child-Pugh Class A only) (category 1)<sup>i,7</sup></li> <li>• Cabozantinib (Child-Pugh Class A only) (category 1)<sup>i,8</sup></li> <li>• Ramucirumab (AFP ≥400 ng/mL only) (category 1)<sup>i,9</sup></li> <li>• Lenvatinib (Child-Pugh Class A only)</li> <li>• Sorafenib (Child-Pugh Class A or B7)<sup>d,e</sup></li> </ul>	<ul style="list-style-type: none"> <li>• Nivolumab + ipilimumab (Child-Pugh Class A only)<sup>b,i,13</sup></li> <li>• Pembrolizumab (Child-Pugh Class A only)<sup>b,j,k,14</sup> (category 2B)</li> </ul>	<ul style="list-style-type: none"> <li>• Nivolumab (Child-Pugh Class B only)<sup>b,j,10-12</sup> (category 2B)</li> <li>• Dostarlimab-gxly<sup>b,j,l,15,16</sup> for MSI-H/dMMR tumors (category 2B)</li> </ul>

<sup>a</sup> An FDA-approved biosimilar is an appropriate substitute for bevacizumab.

<sup>b</sup> See [NCCN Guidelines for Management of Immunotherapy-Related Toxicities](#).

<sup>c</sup> Patients on atezolizumab + bevacizumab should have adequate endoscopic evaluation and management for esophageal varices within approximately 6 months prior to treatment or according to institutional practice and based on the assessment of bleeding risk.

<sup>d</sup> See Child-Pugh Score ([HCC-C](#)) and assessment of portal hypertension (eg, varices, splenomegaly, thrombocytopenia).

<sup>e</sup> Caution: There are limited safety data available for Child-Pugh Class B or C patients and dosing is uncertain. Use with extreme caution in patients with elevated bilirubin levels. (Miller AA, et al. J Clin Oncol 2009;27:1800-1805). The impact of sorafenib on patients potentially eligible for transplant is unknown.

<sup>f</sup> There are limited data supporting the use of FOLFOX, and use of chemotherapy in the context of a clinical trial is preferred. (Qin S, et al. J Clin Oncol 2013;31:3501-3508).

<sup>g</sup> Larotrectinib and entrectinib are treatment options for patients with hepatocellular carcinoma that is NTRK gene fusion positive. (Drilon A, et al. N Engl J Med 2018;378:731-739; Doebele RC, et al. Lancet Oncol 2020;21:271-282.)

<sup>h</sup> There are no data to define optimal treatment for those who progress after first-line systemic therapy, other than sorafenib or nivolumab.

<sup>i</sup> The data reflect use on or after sorafenib in patients who previously tolerated sorafenib at a dose of at least 400 mg per day.

<sup>j</sup> For patients who have not been previously treated with a checkpoint inhibitor because there is a lack of data for subsequent use of immunotherapy in patients who have previously been treated with a checkpoint inhibitor.

<sup>k</sup> Pembrolizumab is a recommended treatment option for patients with or without MSI-H HCC.

<sup>l</sup> Dostarlimab-gxly is a recommended treatment option for patients with MSI-H/dMMR recurrent or advanced tumors that have progressed on or following prior treatment and who have no satisfactory alternative treatment options.

**Note:** All recommendations are category 2A unless otherwise indicated.

**Clinical Trials:** NCCN believes that the best management of any patient with cancer is in a clinical trial. Participation in clinical trials is especially encouraged.

**PRINCIPLES OF SYSTEMIC THERAPY**  
**REFERENCES**

- <sup>1</sup> Finn RS, Qin S, Ikeda M, et al. Atezolizumab plus bevacizumab in unresectable hepatocellular carcinoma. *N Engl J Med* 2020;382:1894-1905.
- <sup>2</sup> Llovet JM, Ricci S, Mazzaferro V, et al. Sorafenib in advanced hepatocellular carcinoma. *N Engl J Med* 2008;359:378-390.
- <sup>3</sup> Cheng AL, Kang YK, Chen Z, et al. Efficacy and safety of sorafenib in patients in the Asia-Pacific region with advanced hepatocellular carcinoma: a phase III randomised, double-blind, placebo-controlled trial. *Lancet Oncol* 2009;10:25-34.
- <sup>4</sup> Kudo M, Finn RS, Qin S, et al. Lenvatinib versus sorafenib in first-line treatment of patients with unresectable hepatocellular carcinoma: a randomised phase 3 non-inferiority trial. *Lancet* 2018;391:1163-1173.
- <sup>5</sup> Alsina A, Kudo M, Vogel A, et al. Subsequent anticancer medication following first-line lenvatinib: a posthoc responder analysis from the phase 3 REFLECT study in unresectable hepatocellular carcinoma. *J Clin Oncol* 2019;37:371-371.
- <sup>6</sup> Yau T, Park JW, Finn RS, et al. CheckMate 459: a randomized, multi-center phase III study of nivolumab (NIVO) vs sorafenib (SOR) as first-line (1L) treatment in patients (pts) with advanced hepatocellular carcinoma. *Ann Oncol* 2019 Oct;30 Suppl 5:v874-v87.
- <sup>7</sup> Bruix J, Qin S, Merle P, et al. Regorafenib for patients with hepatocellular carcinoma who progressed on sorafenib treatment (RESORCE): a randomized, double-blind, placebo-controlled, phase 3 trial. *Lancet* 2017;389:56-66.
- <sup>8</sup> Abou-Alfa GK, Meyer T, Cheng AL, et al. Cabozantinib in patients with advanced and progressing hepatocellular carcinoma. *N Engl J Med* 2018;379:54-63.
- <sup>9</sup> Zhu AX, Kang YK, Yen CJ, et al. REACH-2: A randomized, double-blind, placebo-controlled phase 3 study of ramucirumab versus placebo as second-line treatment in patients with advanced hepatocellular carcinoma (HCC) and elevated baseline alpha-fetoprotein (AFP) following first-line sorafenib. *J Clin Oncol* 2018;36:4003.
- <sup>10</sup> El-Khoueiry AB, Sangro B, Yau T, et al. Nivolumab in patients with advanced hepatocellular carcinoma (CheckMate 040): an open-label, non-comparative, phase 1/2 dose escalation and expansion trial. *Lancet* 2017;389:2492-2502.
- <sup>11</sup> Kudo M, Matilla A, Santoro A, et al. Checkmate-040: nivolumab (NIVO) in patients (pts) with advanced hepatocellular carcinoma (aHCC) and Child-Pugh B (CPB) status. *J Clin Oncol* 2019;37:327-327.
- <sup>12</sup> Kambhampati S, Bauer KE, Bracci PM, et al. Nivolumab in patients with advanced hepatocellular carcinoma and Child-Pugh class B cirrhosis: safety and clinical outcomes in a retrospective case series. *Cancer* 2019;125:3234-3241.
- <sup>13</sup> Yau T, Kang Y-K, Kim T-Y, et al. Efficacy and safety of nivolumab plus ipilimumab in patients with advanced hepatocellular carcinoma previously treated with sorafenib: The CheckMate 040 randomized clinical trial. *JAMA Oncol* 2020;6(11):e204564.
- <sup>14</sup> Zhu AX, Finn RS, Edeline J, et al. Pembrolizumab in patients with advanced hepatocellular carcinoma previously treated with sorafenib (KEYNOTE-224): a non-randomised, open-label phase 2 trial. *Lancet Oncol* 2018;19:940-952.
- <sup>15</sup> Andre T, Berton D, Curigliano G, et al. Safety and efficacy of anti-PD-1 antibody dostarlimab in patients (pts) with mismatch repair-deficient (dMMR) solid cancers: Results from GARNET study [abstract]. *J Clin Oncol* 2021;39:Abstract 9.
- <sup>16</sup> Berton D, Banerjee SN, Curigliano G, et al. Antitumor activity of dostarlimab in patients with mismatch repair-deficient/microsatellite instability-high tumors: A combined analysis of two cohorts in the GARNET study [abstract]. *J Clin Oncol* 2021;39:Abstract 2564.

**Note:** All recommendations are category 2A unless otherwise indicated.**Clinical Trials:** NCCN believes that the best management of any patient with cancer is in a clinical trial. Participation in clinical trials is especially encouraged.



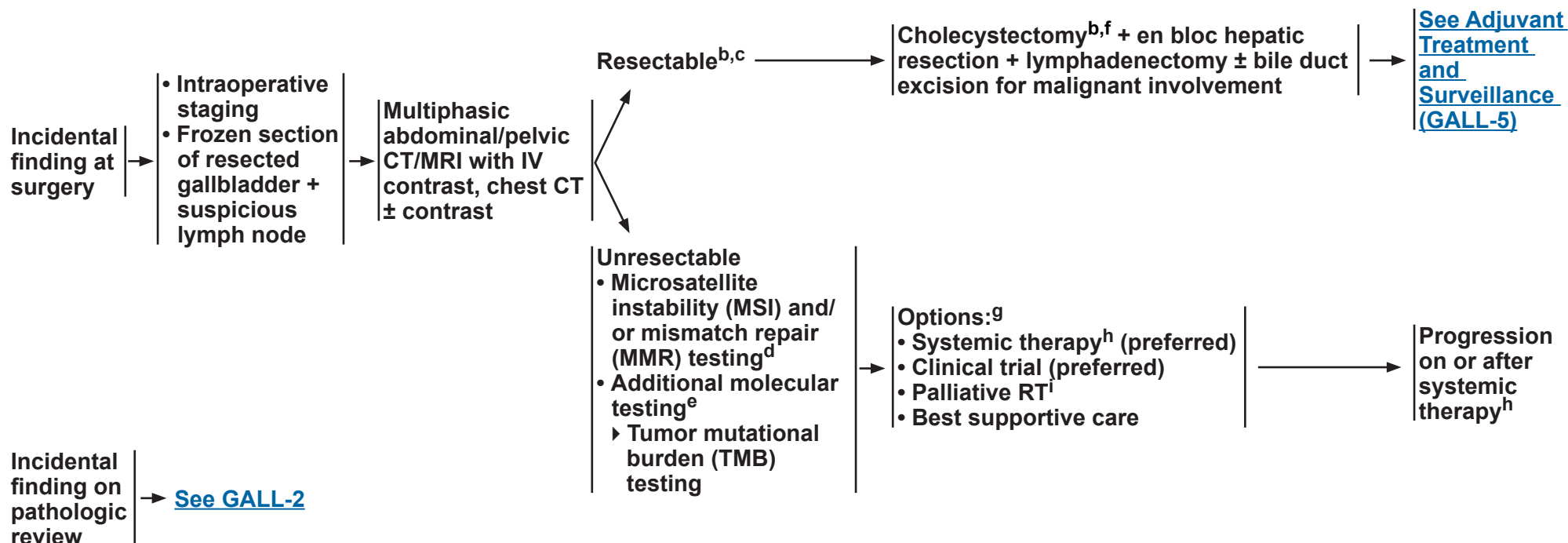
# NCCN Guidelines Version 5.2021

## Biliary Tract Cancers: Gallbladder Cancer

## PRESENTATION

POSTOPERATIVE WORKUP<sup>a</sup>

## PRIMARY TREATMENT



<sup>a</sup> See [Principles of Imaging \(BIL-A\)](#).

<sup>b</sup> See [Principles of Surgery and Pathology \(GALL-A\)](#).

<sup>c</sup> For locoregionally advanced disease, consider neoadjuvant chemotherapy to rule out rapid progression and avoid futile surgery. There are limited clinical trial data to define a standard regimen or definitive benefit. See [Principles of Systemic Therapy \(BIL-C\)](#).

<sup>d</sup> For patients with MMR deficient (dMMR)/MSI-high (MSI-H) tumors or a family history suggestive of *BRCA1/2* mutations, consider germline testing and/or referral to a genetic counselor.

<sup>e</sup> Testing may include *NTRK* gene fusion testing

<sup>f</sup> Depends on expertise of surgeon and/or resectability. Consider referral to surgeon with hepatobiliary expertise and consider intraoperative photography. If resectability is not clear, close incision.

<sup>g</sup> Order does not indicate preference. The choice of treatment modality may depend on extent/location of disease and institutional capabilities.

<sup>h</sup> See [Principles of Systemic Therapy \(BIL-C\)](#).

<sup>i</sup> See [Principles of Radiation Therapy \(BIL-B\)](#).

**Note:** All recommendations are category 2A unless otherwise indicated.

**Clinical Trials:** NCCN believes that the best management of any patient with cancer is in a clinical trial. Participation in clinical trials is especially encouraged.

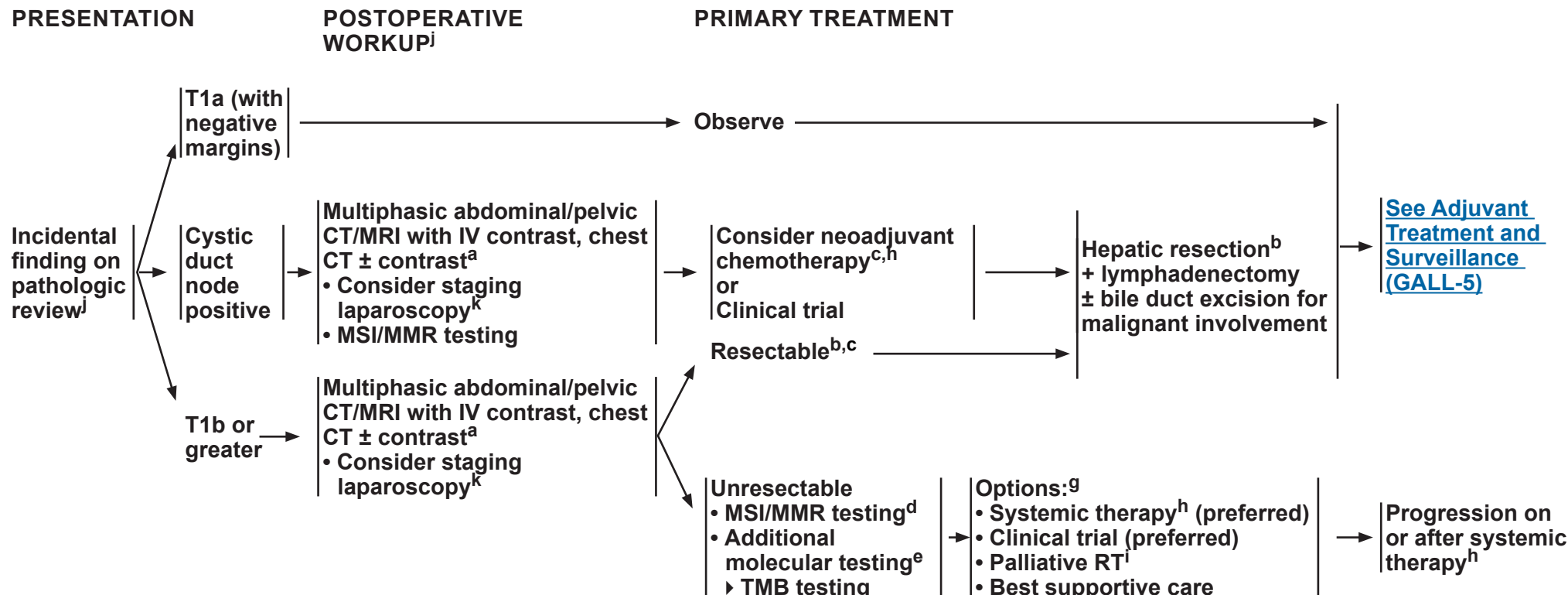
**Other Clinical Presentations**  
See [GALL-3](#)  
and [GALL-4](#)

**GALL-1**



# NCCN Guidelines Version 5.2021

## Biliary Tract Cancers: Gallbladder Cancer

<sup>a</sup> [See Principles of Imaging \(BIL-A\).](#)<sup>b</sup> [See Principles of Surgery and Pathology \(GALL-A\).](#)<sup>c</sup> For locoregionally advanced disease, consider neoadjuvant chemotherapy to rule out rapid progression and avoid futile surgery. There are limited clinical trial data to define a standard regimen or definitive benefit. [See Principles of Systemic Therapy \(BIL-C\).](#)<sup>d</sup> For patients with dMMR/MSI-H tumors or a family history suggestive of *BRCA1/2* mutations, consider germline testing and/or referral to a genetic counselor.<sup>e</sup> Testing may include *NTRK* gene fusion testing.<sup>g</sup> Order does not indicate preference. The choice of treatment modality may depend on extent/location of disease and institutional capabilities.<sup>h</sup> [See Principles of Systemic Therapy \(BIL-C\).](#)<sup>i</sup> [See Principles of Radiation Therapy \(BIL-B\).](#)<sup>j</sup> Consider multidisciplinary review.<sup>k</sup> Butte JM, et al. HPB (Oxford) 2011;13:463-472.**Note:** All recommendations are category 2A unless otherwise indicated.**Clinical Trials:** NCCN believes that the best management of any patient with cancer is in a clinical trial. Participation in clinical trials is especially encouraged.Other Clinical  
Presentations  
See [GALL-3](#)  
and [GALL-4](#)

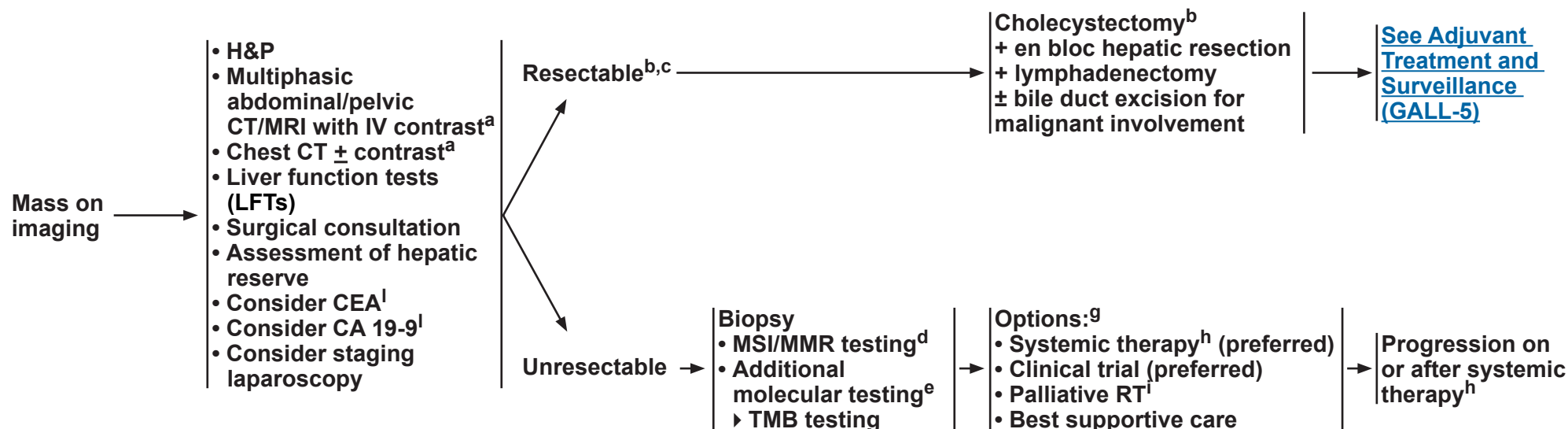
National  
Comprehensive  
Cancer  
Network®

# NCCN Guidelines Version 5.2021

## Biliary Tract Cancers: Gallbladder Cancer

[NCCN Guidelines Index](#)  
[Table of Contents](#)  
[Discussion](#)

### PRESENTATION AND WORKUP

<sup>a</sup> See [Principles of Imaging \(BIL-A\)](#).<sup>b</sup> See [Principles of Surgery and Pathology \(GALL-A\)](#).<sup>c</sup> For locoregionally advanced disease, consider neoadjuvant chemotherapy to rule out rapid progression and avoid futile surgery. There are limited clinical trial data to define a standard regimen or definitive benefit. See [Principles of Systemic Therapy \(BIL-C\)](#).<sup>d</sup> For patients with dMMR/MSI-H tumors or a family history suggestive of *BRCA1/2* mutations, consider germline testing and/or referral to a genetic counselor.<sup>e</sup> Testing may include *NTRK* gene fusion testing.<sup>g</sup> Order does not indicate preference. The choice of treatment modality may depend on extent/location of disease and institutional capabilities.<sup>h</sup> See [Principles of Systemic Therapy \(BIL-C\)](#).<sup>i</sup> See [Principles of Radiation Therapy \(BIL-B\)](#).<sup>l</sup> CEA and CA 19-9 are baseline tests and should not be done to confirm diagnosis.**Note:** All recommendations are category 2A unless otherwise indicated.**Clinical Trials:** NCCN believes that the best management of any patient with cancer is in a clinical trial. Participation in clinical trials is especially encouraged.**Other Clinical Presentations**See [GALL-1](#), [GALL-2](#),  
and [GALL-4](#)**GALL-3**



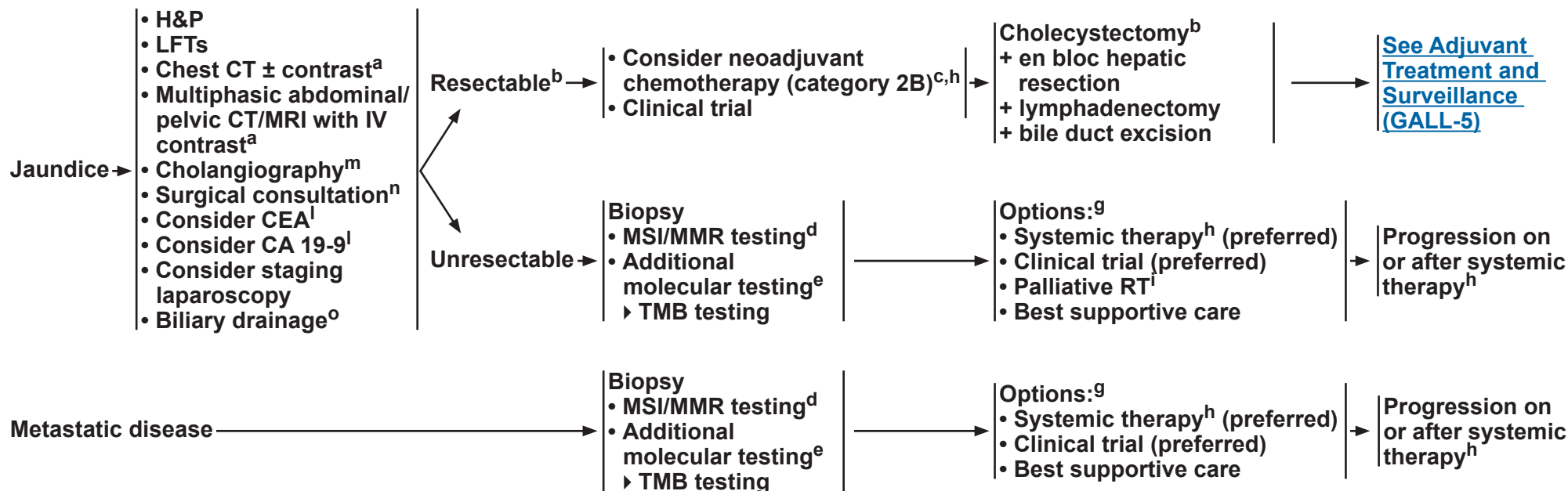


# NCCN Guidelines Version 5.2021

## Biliary Tract Cancers: Gallbladder Cancer

### PRESENTATION AND WORKUP

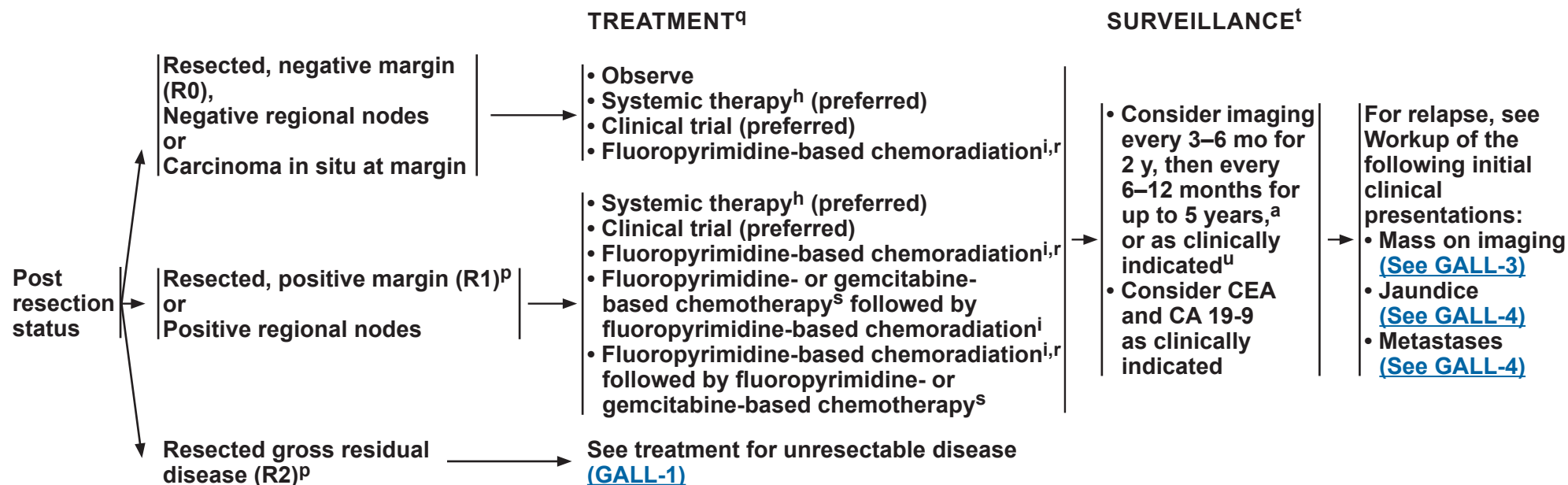
### PRIMARY TREATMENT

<sup>a</sup> [See Principles of Imaging \(BIL-A\).](#)<sup>b</sup> [See Principles of Surgery and Pathology \(GALL-A\).](#)<sup>c</sup> For locoregionally advanced disease, consider neoadjuvant chemotherapy to rule out rapid progression and avoid futile surgery. There are limited clinical trial data to define a standard regimen or definitive benefit. [See Principles of Systemic Therapy \(BIL-C\).](#)<sup>d</sup> For patients with dMMR/MSI-H tumors or a family history suggestive of *BRCA1/2* mutations, consider germline testing and/or referral to a genetic counselor.<sup>e</sup> Testing may include *NTRK* gene fusion testing.<sup>g</sup> Order does not indicate preference. The choice of treatment modality may depend on extent/location of disease and institutional capabilities.<sup>h</sup> [See Principles of Systemic Therapy \(BIL-C\).](#)<sup>i</sup> [See Principles of Radiation Therapy \(BIL-B\).](#)<sup>l</sup> CEA and CA 19-9 are baseline tests and should not be done to confirm diagnosis.<sup>m</sup> Magnetic resonance cholangiopancreatography (MRCP) is preferred. Endoscopic retrograde cholangiopancreatography/percutaneous transhepatic cholangiography (ERCP/PTC) are used more for therapeutic intervention.<sup>n</sup> Consult with a multidisciplinary team.<sup>o</sup> Consider biliary drainage for patients with jaundice prior to resection and systemic therapy. Consider baseline CA 19-9 after biliary decompression.**Note:** All recommendations are category 2A unless otherwise indicated.**Clinical Trials:** NCCN believes that the best management of any patient with cancer is in a clinical trial. Participation in clinical trials is especially encouraged.**Other Clinical  
Presentations**  
See [GALL-2](#)  
and [GALL-3](#)**GALL-4**



# NCCN Guidelines Version 5.2021

## Biliary Tract Cancers: Gallbladder Cancer

<sup>a</sup> See Principles of Imaging (BIL-A).<sup>h</sup> See Principles of Systemic Therapy (BIL-C).<sup>i</sup> See Principles of Radiation Therapy (BIL-B).<sup>p</sup> Management of patients with R1 or R2 resections should be evaluated by a multidisciplinary team.<sup>q</sup> Adjuvant chemotherapy or chemoradiation has been associated with survival benefit in patients with biliary tract cancer (BTC), especially in patients with lymph node-positive disease (Horgan AM, J Clin Oncol 2012;30:1934-1940).<sup>r</sup> There are limited clinical trial data to define a standard regimen or definitive benefit. Clinical trial participation is encouraged. (Macdonald OK, Crane CH. Surg Oncol Clin N Am 2002;11:941-954).<sup>s</sup> For a list of gemcitabine-based regimens and fluoropyrimidine-based regimens to be used before or after chemoradiation, see Adjuvant Chemotherapy (BIL-C, 1 of 3).<sup>t</sup> There are no data to support a specific surveillance schedule or tests for monitoring. Physicians should discuss appropriate follow-up schedules/imaging with patients.<sup>u</sup> Based on surveillance schedule used in the phase III BILCAP trial. Primrose JN, et al. Lancet Oncol 2019;20:663-673.

**Note:** All recommendations are category 2A unless otherwise indicated.

**Clinical Trials:** NCCN believes that the best management of any patient with cancer is in a clinical trial. Participation in clinical trials is especially encouraged.



# NCCN Guidelines Version 5.2021

## Biliary Tract Cancers: Gallbladder Cancer

### PRINCIPLES OF SURGERY AND PATHOLOGY

#### Incidental Finding at Surgery:

- If expertise is unavailable, document all relevant findings and refer the patient to a center with available expertise. If there is a suspicious mass, a biopsy is not necessary as this can result in peritoneal dissemination.
- If expertise is available and there is convincing clinical evidence of cancer, a definitive resection should be performed as written below. If the diagnosis is not clear, frozen section biopsies can be considered in selected cases before proceeding with definitive resection.
- The principles of resection are the same as below consisting of radical cholecystectomy including segments IV B and V and lymphadenectomy and extended hepatic or biliary resection as necessary to obtain a negative margin.

#### Incidental Finding on Pathologic Review:

- Consider pathologic re-review by a hepatobiliary pathology expert and/or speak to surgeon to check for completeness of cholecystectomy, signs of disseminated disease, location of tumor, and any other pertinent information. Review the pathology report for T stage, cystic duct margin status, and other margins.
- Diagnostic laparoscopy can be performed but is of relatively low yield. Higher yields may be seen in patients with T3 or higher tumors, poorly differentiated tumors, or with a margin-positive cholecystectomy. Diagnostic laparoscopy should also be considered in patients with any suspicion of metastatic disease on imaging that is not amenable to percutaneous biopsy.<sup>1</sup>
- Repeat cross-sectional imaging of the chest, abdomen, and pelvis should be performed prior to definitive resection.
- Initial exploration should rule out distant lymph node metastases in the celiac axis or aorto-caval groove as these contraindicate further resection.
- Hepatic resection should be performed to obtain clear margins, which usually consists of segments IV B and V. Extended resections beyond segments IV B and V may be needed in some patients to obtain negative margins.
- Lymphadenectomy should be performed to clear all lymph nodes in the porta hepatis.
- Resection of the bile duct may be needed to obtain negative margins. Routine resection of the bile duct for lymphadenectomy has been shown to increase morbidity without convincing evidence for improved survival.<sup>2,3</sup>
- Port site resection has not been shown to be effective, as the presence of a port site implant is a surrogate marker of underlying disseminated disease and has not been shown to improve outcomes.<sup>4</sup>

<sup>1</sup> Butte JM, Gonen M, Allen PJ, et al. The role of laparoscopic staging in patients with incidental gallbladder cancer. HPB (Oxford) 2011;13:463-472.

<sup>2</sup> Fuks D, Regimbeau JM, Le Treut YP, et al. Incidental gallbladder cancer by the AFC-GBC-2009 Study Group. World J Surg 2011;35:1887-1897.

<sup>3</sup> D'Angelica M, Dalal KM, Dematteo RP, et al. Analysis of extent of resection for adenocarcinoma of gallbladder. Ann Surg Oncol 2009;16:806-816.

<sup>4</sup> Maker AV, Butte JM, Oxenberg J, et al. Is port site resection necessary in the surgical management of gallbladder cancer. Ann Surg Oncol 2012;19:409-417.

**Note:** All recommendations are category 2A unless otherwise indicated.

**Clinical Trials:** NCCN believes that the best management of any patient with cancer is in a clinical trial. Participation in clinical trials is especially encouraged.



# NCCN Guidelines Version 5.2021

## Biliary Tract Cancers: Gallbladder Cancer

### PRINCIPLES OF SURGERY AND PATHOLOGY

#### **Mass on Imaging: Patients Presenting with Gallbladder Mass/Disease Suspicious for Gallbladder Cancer**

- Staging should be carried out with multiphasic cross-sectional imaging of the chest, abdomen, and pelvis.
- If there is a suspicious mass, a biopsy is not necessary and a definitive resection should be carried out.
- Diagnostic laparoscopy is recommended prior to definitive resection.
- In selected cases where the diagnosis is not clear it may be reasonable to perform a cholecystectomy (including intraoperative frozen section) followed by the definitive resection during the same setting if pathology confirms cancer.
- The resection is carried out as per the principles described above.

#### **Gallbladder Cancer and Jaundice**

- The presence of jaundice in gallbladder cancer usually portends a poor prognosis.<sup>5-7</sup> These patients need careful surgical evaluation.
- Although a relative contraindication, in select patients curative intent resection can be attempted for resectable disease in centers with available expertise.

<sup>5</sup> Hawkins WG, DeMatteo RP, Jarnagin WR, et al. Jaundice predicts advanced disease and early mortality in patients with gallbladder cancer. *Ann Surg Oncol* 2004;11:310-315.

<sup>6</sup> Regimbeau JM, Fuks D, Bachellier P, et al. Prognostic value of jaundice in patients with gallbladder cancer by the AFC -GBC-2009 study group. *Eur J Surg Oncol* 2011;37:505-512.

<sup>7</sup> Nishio H, Ebata T, Yokoyama Y, et al. Gallbladder cancer involving the extrahepatic bile duct is worthy of resection. *Ann Surg* 2011;253:953-960.

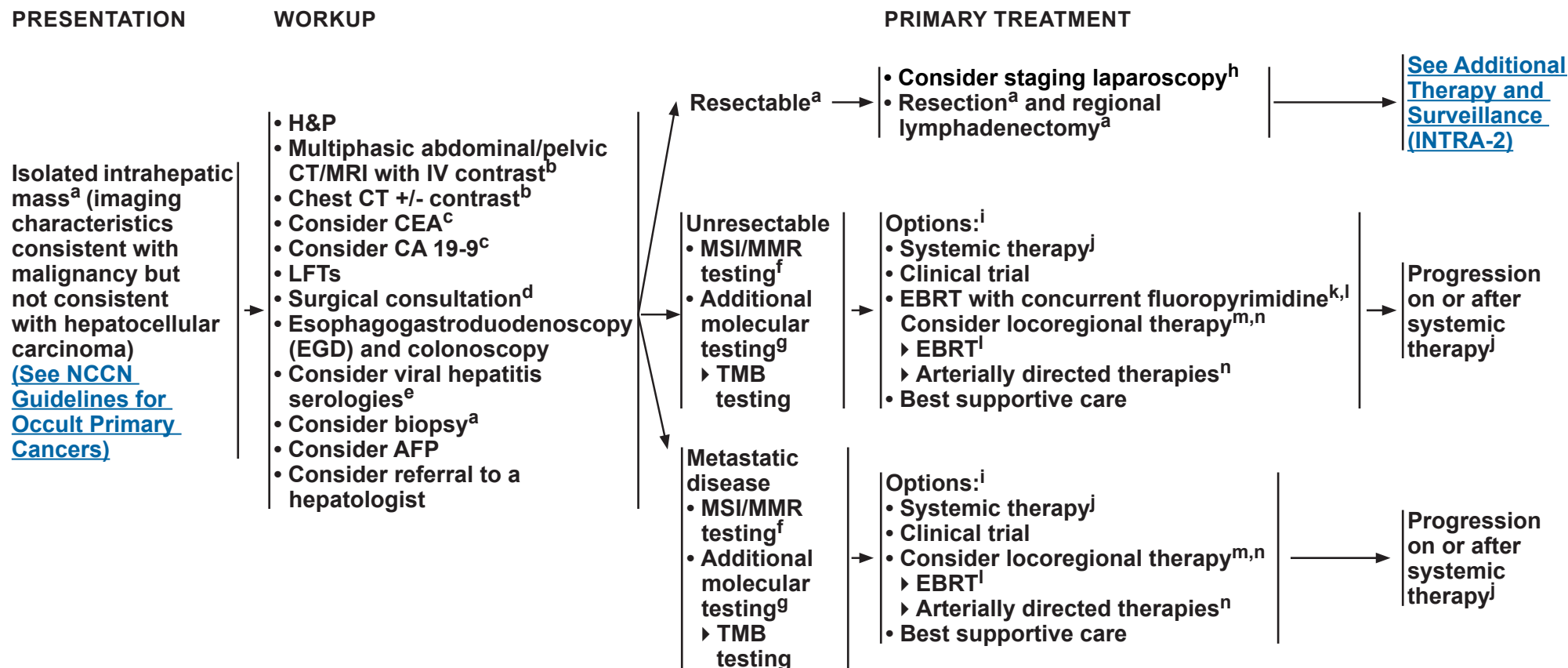
**Note:** All recommendations are category 2A unless otherwise indicated.

**Clinical Trials:** NCCN believes that the best management of any patient with cancer is in a clinical trial. Participation in clinical trials is especially encouraged.



# NCCN Guidelines Version 5.2021

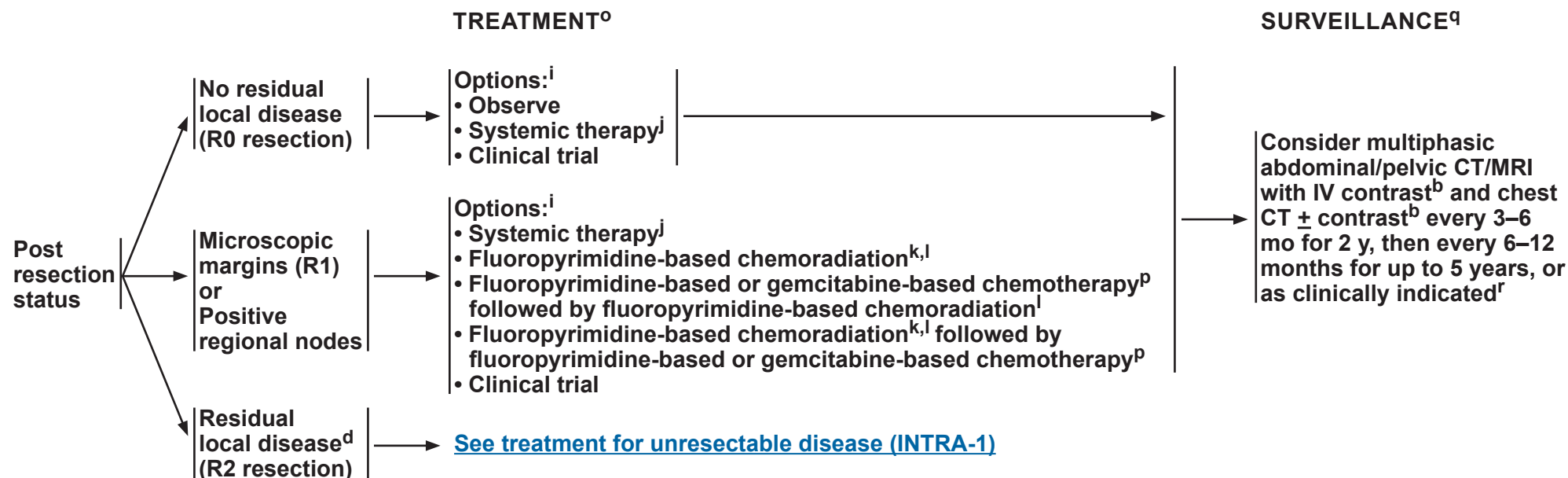
## Biliary Tract Cancers: Intrahepatic Cholangiocarcinoma

<sup>a</sup> [See Principles of Surgery \(INTRA-A\)](#).<sup>b</sup> [See Principles of Imaging \(HCC-A\)](#).<sup>c</sup> CEA and CA 19-9 are baseline tests and should not be done to confirm diagnosis.<sup>d</sup> Consult with multidisciplinary team.<sup>e</sup> ASCO guidelines for management of viral HBV in cancer/chemo patients: <https://www.asco.org/sites/new-www.asco.org/files/content-files/advocacy-and-policy/documents/2020-HBV-PCO-Algorithm.pdf><sup>f</sup> For patients with dMMR/MSI-H tumors or a family history suggestive of *BRCA1/2* mutations, consider germline testing and/or referral to a genetic counselor.<sup>g</sup> Testing may include *NTRK* gene fusion testing.<sup>h</sup> Laparoscopy may be done in conjunction with surgery if no distant metastases are found.<sup>i</sup> Order does not indicate preference. The choice of treatment modality may depend on extent/location of disease and institutional capabilities.<sup>j</sup> [See Principles of Systemic Therapy \(BIL-C\)](#).<sup>k</sup> There are limited clinical trial data to define a standard regimen or definitive benefit. Participation in clinical trials is encouraged (Macdonald OK, Crane CH. Surg Oncol Clin N Am 2002;11:941-954).<sup>l</sup> [See Principles of Radiation Therapy \(BIL-B\)](#).<sup>m</sup> Intra-arterial chemotherapy (with or without systemic chemotherapy) may be used in a clinical trial or at experienced centers.<sup>n</sup> [Principles of Locoregional Therapy \(HCC-E\)](#).**Note:** All recommendations are category 2A unless otherwise indicated.**Clinical Trials:** NCCN believes that the best management of any patient with cancer is in a clinical trial. Participation in clinical trials is especially encouraged.



# NCCN Guidelines Version 5.2021

## Biliary Tract Cancers: Intrahepatic Cholangiocarcinoma

<sup>b</sup> [See Principles of Imaging \(HCC-A\).](#)<sup>d</sup> Consult with multidisciplinary team.<sup>i</sup> Order does not indicate preference. The choice of treatment modality may depend on extent/location of disease and institutional capabilities<sup>j</sup> [See Principles of Systemic Therapy \(BIL-C\).](#)<sup>k</sup> There are limited clinical trial data to define a standard regimen or definitive benefit. Clinical trial participation is encouraged (Macdonald OK, Crane CH. Surg Oncol Clin N Am 2002;11:941-954).<sup>l</sup> [See Principles of Radiation Therapy \(BIL-B\).](#)<sup>o</sup> Adjuvant chemotherapy or chemoradiation has been associated with survival benefit in patients with biliary tract cancer (BTC), especially in patients with lymph node-positive disease (Horgan AM, et al. J Clin Oncol 2012;30:1934-1940).<sup>p</sup> For a list of gemcitabine-based regimens and fluoropyrimidine-based regimens to be used before or after chemoradiation, [see Adjuvant Chemotherapy \(BIL-C, 1 of 3\).](#)<sup>q</sup> There are no data to support a specific surveillance schedule or tests for monitoring. Physicians should discuss appropriate follow-up schedules/imaging with patients.<sup>r</sup> Based on surveillance schedule used in the phase III BILCAP trial. Primrose JN, et al. Lancet Oncol 2019;20:663-673.**Note:** All recommendations are category 2A unless otherwise indicated.**Clinical Trials:** NCCN believes that the best management of any patient with cancer is in a clinical trial. Participation in clinical trials is especially encouraged.





# NCCN Guidelines Version 5.2021

## Biliary Tract Cancers: Intrahepatic Cholangiocarcinoma

### PRINCIPLES OF SURGERY<sup>1,2</sup>

#### General Principles

- A preoperative biopsy is not always necessary before proceeding with a definitive, potentially curative resection. A suspicious mass on imaging in the proper clinical setting should be treated as malignant.
- Diagnostic laparoscopy to rule out unresectable disseminated disease should be considered.
- Initial exploration should assess for multifocal hepatic disease, lymph node metastases, and distant metastases. Lymph node metastases beyond the porta hepatis and distant metastatic disease contraindicate resection.
- Hepatic resection with negative margins is the goal of surgical therapy. While major resections are often necessary, wedge resections and segmental resections are all appropriate given that a negative margin can be achieved.
- A regional lymphadenectomy of the porta hepatis is carried out.
- Multifocal liver disease is generally representative of metastatic disease and is a contraindication to resection. In highly selected cases with limited multifocal disease resection can be considered.
- Gross lymph node metastases to the porta hepatis portend a poor prognosis and resection should only be considered in highly selected cases.

<sup>1</sup> Endo I, Gonen M, Yopp A. Intrahepatic cholangiocarcinoma: Rising frequency, improved survival and determinants of outcome after resection. *Ann Surg* 2008;248:84-96.

<sup>2</sup> de Jong MC, Nathan H, Sotiropoulos GC. Intrahepatic cholangiocarcinoma: an international multi-institutional analysis of prognostic factors and lymph node assessment. *J Clin Oncol* 2011;29:3140-3145.

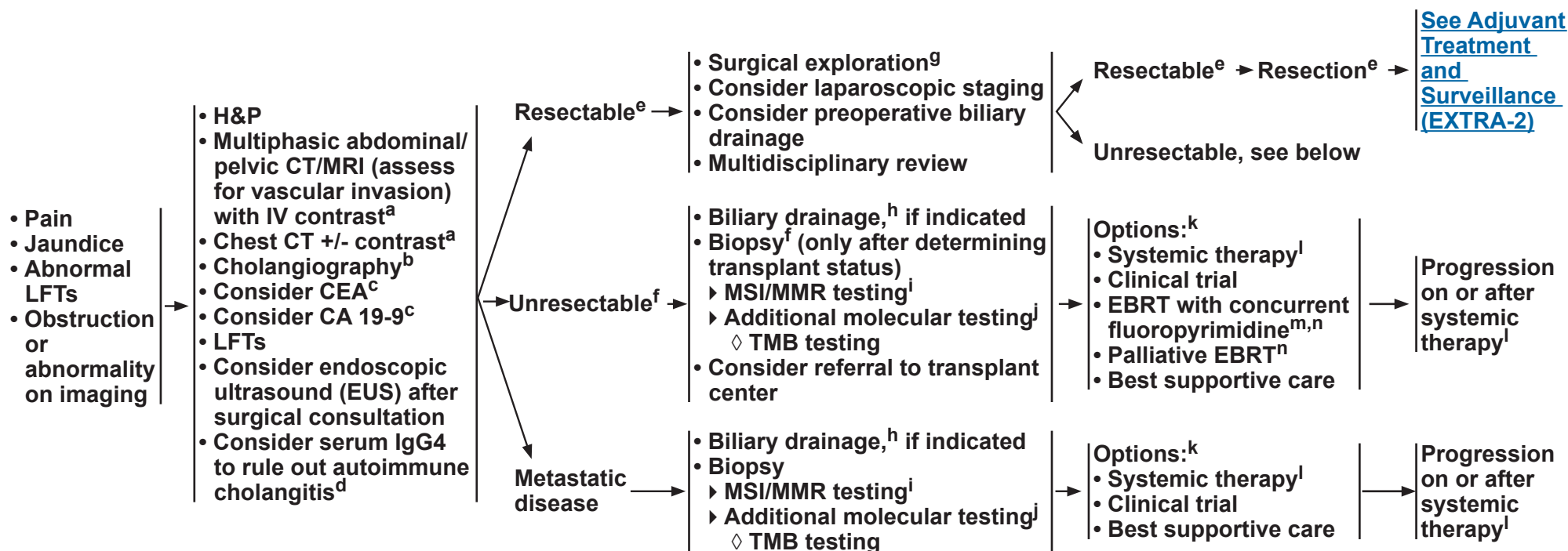
**Note:** All recommendations are category 2A unless otherwise indicated.

**Clinical Trials:** NCCN believes that the best management of any patient with cancer is in a clinical trial. Participation in clinical trials is especially encouraged.



## PRESENTATION AND WORKUP

## PRIMARY TREATMENT

<sup>a</sup> [See Principles of Imaging \(BIL-A\).](#)<sup>b</sup> Magnetic resonance cholangiopancreatography (MRCP) is preferred.

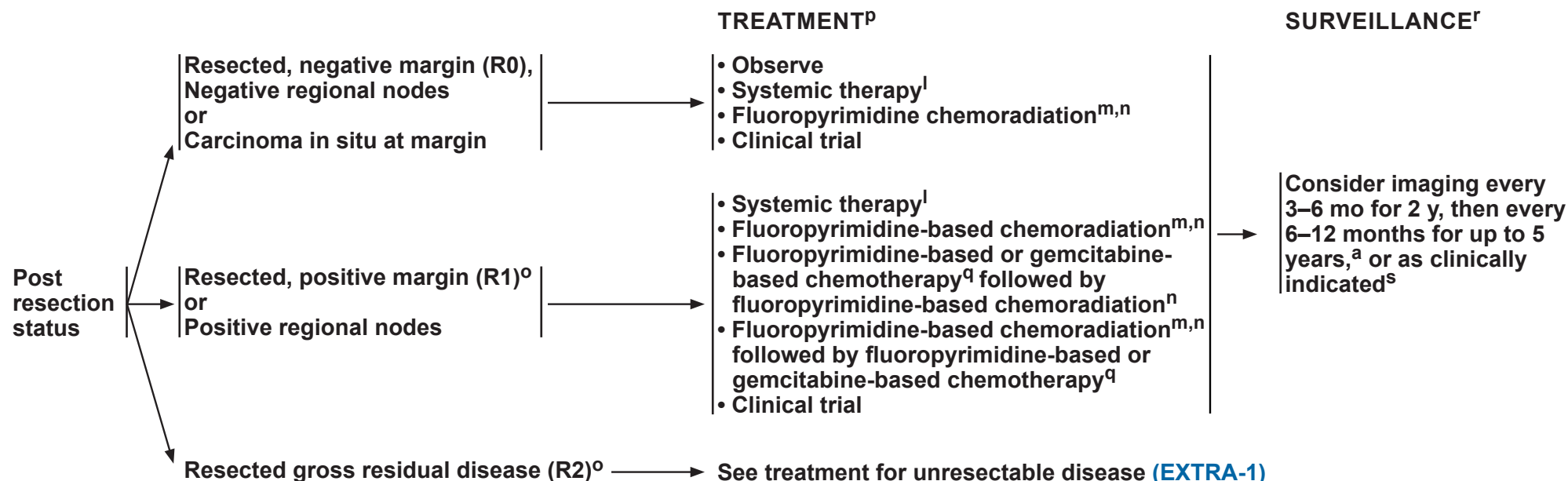
Endoscopic retrograde cholangiopancreatography/percutaneous transhepatic cholangiography (ERCP/PTC) are used more for therapeutic intervention.

<sup>c</sup> CEA and CA 19-9 are baseline tests and should not be done to confirm diagnosis.<sup>d</sup> Patients with IgG-4-related cholangiopathy should be referred to an expert center.<sup>e</sup> [See Principles of Surgery \(EXTRA-A\).](#)<sup>f</sup> Before biopsy, evaluate if patient is a resection or transplant candidate. If patient is a potential transplant candidate, consider referral to transplant center before biopsy. Unresectable perihilar or hilar cholangiocarcinomas that measure ≤3 cm in radial diameter, with the absence of intrahepatic or extrahepatic metastases and without nodal disease, as well as those with primary sclerosing cholangitis, may be considered for liver transplantation at a transplant center that has an UNOS-approved protocol for transplantation of cholangiocarcinoma.<sup>g</sup> Surgery may be performed when index of suspicion is high; biopsy is not required.<sup>h</sup> Consider biliary drainage for patients with jaundice prior to instituting chemotherapy. Consider baseline CA 19-9 after biliary decompression.<sup>i</sup> For patients with dMMR/MSI-H tumors or a family history suggestive of *BRCA1/2* mutations, consider germline testing and/or referral to a genetic counselor.<sup>j</sup> Testing may include *NTRK* gene fusion testing.<sup>k</sup> Order does not indicate preference. The choice of treatment modality may depend on extent/location of disease and institutional capabilities.<sup>l</sup> [See Principles of Systemic Therapy \(BIL-C\).](#)<sup>m</sup> There are limited clinical trial data to define a standard regimen or definitive benefit. Clinical trial participation is encouraged (Macdonald OK, Crane CH. Surg Oncol Clin N Am 2002;11:941-954).<sup>n</sup> [See Principles of Radiation Therapy \(BIL-B\).](#)**Note:** All recommendations are category 2A unless otherwise indicated.**Clinical Trials:** NCCN believes that the best management of any patient with cancer is in a clinical trial. Participation in clinical trials is especially encouraged.



# NCCN Guidelines Version 5.2021

## Biliary Tract Cancers: Extrahepatic Cholangiocarcinoma



<sup>a</sup> See Principles of Imaging (BIL-A).

<sup>l</sup> See Principles of Systemic Therapy (BIL-C).

<sup>m</sup> There are limited clinical trial data to define a standard regimen or definitive benefit. Clinical trial participation is encouraged (Macdonald OK, Crane CH. Surg Oncol Clin N Am 2002;11:941-954).

<sup>n</sup> See Principles of Radiation Therapy (BIL-B).

<sup>o</sup> Management of patients with R1 or R2 resections should be evaluated by a multidisciplinary team.

<sup>p</sup> Adjuvant chemotherapy or chemoradiation has been associated with survival benefit in patients with biliary tract cancers, especially in patients with lymph node-positive disease (Horgan AM, et al. J Clin Oncol 2012;30:1934-1940).

<sup>q</sup> For a list of gemcitabine-based regimens and fluoropyrimidine-based regimens to be used before or after chemoradiation, see Adjuvant Chemotherapy (BIL-C, 1 of 3).

<sup>r</sup> There are no data to support a specific surveillance schedule or tests for monitoring. Physicians should discuss appropriate follow-up schedules/imaging with patients.

<sup>s</sup> Based on surveillance schedule used in the phase III BILCAP trial. Primrose JN, et al. Lancet Oncol 2019;20:663-673.

**Note:** All recommendations are category 2A unless otherwise indicated.

**Clinical Trials:** NCCN believes that the best management of any patient with cancer is in a clinical trial. Participation in clinical trials is especially encouraged.



# NCCN Guidelines Version 5.2021

## Biliary Tract Cancers: Extrahepatic Cholangiocarcinoma

### PRINCIPLES OF SURGERY

#### General Principles

- The basic principle is a complete resection with negative margins and regional lymphadenectomy. This generally requires a pancreaticoduodenectomy for distal bile duct tumors and a major hepatic resection for hilar tumors. Rarely, a mid bile duct tumor can be resected with a bile duct resection and regional lymphadenectomy.
- A preoperative biopsy is not always necessary before proceeding with a definitive, potentially curative resection. A suspicious mass on imaging in the proper clinical setting should be treated as malignant.
- Diagnostic laparoscopy should be considered.
- Occasionally a bile duct tumor will involve the biliary tree over a long distance such that a hepatic resection and pancreaticoduodenectomy will be necessary. These are relatively morbid procedures and should only be carried out in very healthy patients without significant comorbidity. Nonetheless, these can be potentially curative procedures and should be considered in the proper clinical setting. Combined liver and pancreatic resections performed to clear distant nodal disease are not recommended.

#### Hilar Cholangiocarcinoma

- Detailed descriptions of imaging assessment of resectability are beyond the scope of this outline. The basic principle is that the tumor will need to be resected along with the involved biliary tree and the involved hemi-liver with a reasonable chance of a margin-negative resection. The contralateral liver requires intact arterial and portal inflow as well as biliary drainage.<sup>1-3</sup>
- Detailed descriptions of preoperative surgical planning are beyond the scope of this outline but require an assessment of the FLR. This requires an assessment of biliary drainage and volumetrics of the FLR. While not necessary in all cases, the use of preoperative biliary drainage of the FLR and contralateral portal vein embolization should be considered in cases of a small FLR.<sup>4,5</sup>
- Initial exploration rules out distant metastatic disease to the liver, peritoneum, or distant lymph nodes beyond the porta hepatis as these findings contraindicate resection. Further exploration must confirm local resectability.
- Since hilar tumors, by definition, abut or invade the central portion of the liver they require major hepatic resections on the involved side to encompass the biliary confluence and generally require a caudate resection.
- Resection and reconstruction of the portal vein and/or hepatic artery may be necessary for complete resection and require expertise in these procedures.
- Biliary reconstruction is generally through a Roux-en-Y hepaticojejunostomy.
- A regional lymphadenectomy of the porta hepatis is carried out.
- Frozen section assessment of proximal and distal bile duct margins is recommended if further resection can be carried out.

#### Distal Cholangiocarcinoma

- Initial assessment is needed to rule out distant metastatic disease and local resectability.
- The operation generally requires a pancreaticoduodenectomy with typical reconstruction.

<sup>1</sup> Nishio H, Nagino M, Nimura Y. Surgical management of hilar cholangiocarcinoma: the Nagoya experience. HPB (Oxford) 2005;7:259-262.

<sup>2</sup> Matsuo K, Rocha FG, Ito K, et al. The Blumgart preoperative staging system for hilar cholangiocarcinoma: analysis of resectability and outcomes in 380 patients. J Am Coll Surg 2012;215:343-355.

<sup>3</sup> Jarnagin WR, Fong Y, DeMatteo RP, et al. Staging, resectability, and outcome in 225 patients with hilar cholangiocarcinoma. Ann Surg 2001;234:507-517.

<sup>4</sup> Nimura Y. Preoperative biliary drainage before resection for cholangiocarcinoma. HPB (Oxford) 2008;10:130-133.

<sup>5</sup> Kennedy TJ, Yopp A, Qin Y, et al. Role of preoperative biliary drainage of live remnant prior to extended liver resection for hilar cholangiocarcinoma. HPB (Oxford) 2009;11:445-451.

**Note:** All recommendations are category 2A unless otherwise indicated.

**Clinical Trials:** NCCN believes that the best management of any patient with cancer is in a clinical trial. Participation in clinical trials is especially encouraged.

**PRINCIPLES OF IMAGING<sup>1-4</sup>****General Principles**

- CT of the chest with or without contrast and multiphasic contrast-enhanced CT or MRI of the abdomen and pelvis are recommended for follow-up imaging.
- PET/CT has limited sensitivity but high specificity and may be considered when there is an equivocal finding.<sup>5</sup> The routine use of PET/CT in the preoperative setting has not been established in prospective trials.

**Gallbladder Cancer**

- Detection of early-stage gallbladder cancer remains difficult, and is commonly discovered incidentally at surgery or pathologic examination of the gallbladder.
- If gallbladder cancer is suspected preoperatively, multidetector multiphase CT of the abdomen (and pelvis) or contrast-enhanced MRI with magnetic resonance cholangiopancreatography (MRCP) of the abdomen (and pelvis) and chest CT with or without contrast should be performed. MRI is preferred for evaluating masses within the gallbladder and demonstrating bile duct involvement.
- Because lymphatic spread is common, careful attention should be made to evaluate nodal disease, specifically the porta hepatis and left gastric and aorto-caval basins.

**Intrahepatic and Extrahepatic Cholangiocarcinoma**

- Surgical management is based on the location and extent of the tumor.
- Preoperative imaging for accurate staging of extrahepatic cholangiocarcinoma should be done with multidetector multiphase abdominal/pelvic CT or MRI. Contrast-enhanced MRI with MRCP is preferred for evaluating the extent of biliary tract involvement. Imaging with multiphase CT or MRI with thin cuts, or multiphase CT or MRI of the liver and biliary tree should specifically address the anatomy of the biliary tree, hepatic arteries, and portal veins and their relationship to the tumor.
- Chest CT with or without contrast is recommended for staging.
- Imaging for staging ideally should be performed prior to biopsy or biliary drainage.
- EUS or endoscopic retrograde cholangiopancreatography (ERCP) may be helpful in the setting of bile duct dilation if no mass is seen on CT or MRI. EUS or ERCP can also be used to establish tissue diagnosis and provide access to relieve biliary obstruction.
- CT of the chest with or without contrast and CT or MRI of the abdomen and pelvis with contrast may be used for follow-up.
- Delayed phase imaging is preferred when the diagnosis of intrahepatic cholangiocarcinoma is suspected or confirmed.

<sup>1</sup> Srinivasa S, McEntee B, Koea JB. The role of PET scans in the management of cholangiocarcinoma and gallbladder cancer: a systematic review for surgeons. *Int J Diagnostic Imaging* 2015;2.

<sup>2</sup> Corvera CU, Blumgart LH, Akhurst T, et al. 18F-fluorodeoxyglucose positron emission tomography influences management decisions in patients with biliary cancer. *J Am Coll Surg* 2008;206:57-65.

<sup>3</sup> Brandi G, Venturi M, Pantaleo MA, Ercolani G, GICO. Cholangiocarcinoma: Current opinion on clinical practice diagnostic and therapeutic algorithms: A review of the literature and a long-standing experience of a referral center. *Dig Liver Dis* 2016;48:231-241.

<sup>4</sup> Navaneethan U, Njei B, Venkatesh PG, Lourdusamy V, Sanaka MR. Endoscopic ultrasound in the diagnosis of cholangiocarcinoma as the etiology of biliary strictures: a systematic review and meta-analysis. *Gastroenterol Rep (Oxf)* 2015;3:209-215.

<sup>5</sup> Lamarca A, Barriuso J, Chander A, et al. 18F-fluorodeoxyglucose positron emission tomography (18FDG-PET) for patients with biliary tract cancer: Systematic review and meta-analysis. *J Hepatol* 2019;71:115-129.

**Note:** All recommendations are category 2A unless otherwise indicated.

**Clinical Trials:** NCCN believes that the best management of any patient with cancer is in a clinical trial. Participation in clinical trials is especially encouraged.



**PRINCIPLES OF RADIATION THERAPY****General Principles**

- **IGRT is strongly recommended when using EBRT, IMRT, and SBRT to improve treatment accuracy and reduce treatment-related toxicity.**
- **Adjuvant EBRT<sup>1,2</sup>**
  - **Postoperative EBRT using conventional 3D-CRT or IMRT is an option for resected extrahepatic cholangiocarcinoma and gallbladder cancer.<sup>3,4</sup> Target volumes should cover the draining regional lymph nodes to 45 Gy at 1.8 Gy/fraction and 50–60 Gy in 1.8–2 Gy/fraction to the tumor bed depending on margin positivity.**
- **Unresectable**
  - **All tumors irrespective of the location may be amenable to EBRT (3D-CRT, IMRT, or SBRT).**
  - **Conventionally fractionated radiotherapy with concurrent fluoropyrimidine-based chemotherapy<sup>a</sup> to standard or high dose is acceptable for intrahepatic and extrahepatic tumors.**
  - **Hypofractionation with photons<sup>5</sup> or protons<sup>6</sup> is an acceptable option for intrahepatic tumors, though treatment at centers with experience is recommended.**
  - **Palliative EBRT is appropriate for symptom control and/or prevention of complications from metastatic lesions, such as bone or brain.**
- **RT Dosing:**
  - **EBRT:**
    - ◊ **Initial volumes to 45 Gy in 1.8 Gy per fraction**
    - ◊ **Boost to 50 to 60 Gy in 1.8–2 Gy per fraction**
  - **SBRT:**
    - ◊ **30–50 Gy (typically in 3–5 fractions), depending on the ability to meet normal organ constraints and underlying liver function.**
    - ◊ **Other hypofractionated schedules >5 fractions may also be used if clinically indicated**
    - ◊ **For intrahepatic tumors, SBRT (typically 3–5 fractions) is an acceptable option.<sup>5</sup>**

**Footnote**

<sup>a</sup> [See Principles of Systemic Therapy \(BIL-C\).](#)

**References**

- <sup>1</sup> Mallick S, Benson R, Haresh KP, et al. Adjuvant radiotherapy in the treatment of gallbladder carcinoma: What is the current evidence? J Egypt Natl Canc Inst 2016;28:1-6.
- <sup>2</sup> Kim Y, Amini N, Wilson A, et al. Impact of chemotherapy and external-beam radiation therapy on outcomes among patients with resected gallbladder cancer: A multi-institutional analysis. Ann Surg Oncol 2016;23:2998-3008.
- <sup>3</sup> Ben-Josef E, Guthrie KA, El-Khoueiry AB, et al. SWOG S0809: A phase II intergroup trial of adjuvant capecitabine and gemcitabine followed by radiotherapy and concurrent capecitabine in extrahepatic cholangiocarcinoma and gallbladder carcinoma. J Clin Oncol 2015;33:2617-2622.
- <sup>4</sup> Wang SJ, Lemieux A, Kalpathy-Cramer J, et al. Nomogram for predicting the benefit of adjuvant chemoradiotherapy for resected gallbladder cancer. J Clin Oncol 2011;29:4627-4632.
- <sup>5</sup> Tao R, Krishnan S, Bhosale PR, et al. Ablative radiotherapy doses lead to a substantial prolongation of survival in patients with inoperable intrahepatic cholangiocarcinoma: a retrospective dose response analysis. J Clin Oncol 2016;34:219-226.
- <sup>6</sup> Hong TS, Wo JY, Yeap BY, et al. Multi-institutional phase II study of high-dose hypofractionated proton beam therapy in patients with localized, unresectable hepatocellular carcinoma and intrahepatic cholangiocarcinoma. J Clin Oncol 2016;34:460-468.

**Note:** All recommendations are category 2A unless otherwise indicated.

**Clinical Trials:** NCCN believes that the best management of any patient with cancer is in a clinical trial. Participation in clinical trials is especially encouraged.





### PRINCIPLES OF SYSTEMIC THERAPY

#### Neoadjuvant Therapy<sup>a</sup>

##### Preferred Regimens

- None

##### Other Recommended Regimens

- 5-fluorouracil + oxaliplatin
- Capecitabine + oxaliplatin
- Gemcitabine + capecitabine
- Gemcitabine + cisplatin
- Gemcitabine + cisplatin + albumin-bound paclitaxel<sup>1</sup> (category 2B)
- Gemcitabine + oxaliplatin (category 2B)
- Single agents:
  - 5-fluorouracil
  - Capecitabine
  - Gemcitabine

##### Useful in Certain Circumstances

- None

#### Adjuvant Therapy<sup>b,2</sup>

##### Preferred Regimens

- Capecitabine<sup>c,3</sup> (category 1)

##### Other Recommended Regimens

- 5-fluorouracil + oxaliplatin
- Capecitabine + oxaliplatin
- Gemcitabine + capecitabine
- Gemcitabine + cisplatin
- Capecitabine + cisplatin (category 3)
- Single agents:
  - 5-fluorouracil
  - Gemcitabine

##### Useful in Certain Circumstances

- None

#### Agents Used with Concurrent Radiation

- 5-fluorouracil
- Capecitabine

<sup>a</sup> There are limited clinical trial data to define a standard regimen or definitive benefit. Clinical trial participation is encouraged.

<sup>b</sup> Adjuvant chemotherapy or chemoradiation has been associated with survival benefit in patients with biliary tract cancer (BTC), especially in patients with lymph node-positive disease.

<sup>c</sup> The phase III BILCAP study shows improved overall survival for adjuvant capecitabine in the per-protocol analysis, and the overall survival did not reach statistical significance in the intent-to-treat analysis. Primrose JN, Fox RP, Palmer DH, et al. Capecitabine compared with observation in resected biliary tract cancer (BILCAP): a randomised, controlled, multicentre, phase 3 study. *Lancet Oncol* 2019;20:663-673. Ben-Josef E, Guthrie KA, El-Khoueiry AB, et al. SWOG S0809: A phase II intergroup trial of adjuvant capecitabine and gemcitabine followed by radiotherapy and concurrent capecitabine in extrahepatic cholangiocarcinoma and gallbladder carcinoma. *J Clin Oncol* 2015;33:2617-2622.

**Note:** All recommendations are category 2A unless otherwise indicated.

**Clinical Trials:** NCCN believes that the best management of any patient with cancer is in a clinical trial. Participation in clinical trials is especially encouraged.



### PRINCIPLES OF SYSTEMIC THERAPY

#### Primary Treatment for Unresectable and Metastatic Disease

##### Preferred Regimens

- Gemcitabine + cisplatin<sup>4</sup> (category 1)

##### Other Recommended Regimens

- 5-fluorouracil + oxaliplatin
- 5-fluorouracil + cisplatin (category 2B)
- Capecitabine + cisplatin (category 2B)
- Capecitabine + oxaliplatin
- Gemcitabine + albumin-bound paclitaxel
- Gemcitabine + capecitabine
- Gemcitabine + oxaliplatin
- Gemcitabine + cisplatin + albumin-bound paclitaxel<sup>1</sup> (category 2B)
- Single agents:
  - 5-fluorouracil
  - Capecitabine
  - Gemcitabine

##### Useful in Certain Circumstances

- For *NTRK* gene fusion-positive tumors:
  - Entrectinib<sup>5-7</sup>
  - Larotrectinib<sup>8</sup>
- For MSI-H/dMMR tumors:
  - Pembrolizumab<sup>d,e,9</sup>

#### Subsequent-Line Therapy for Biliary Tract Cancers if Disease Progression

##### Preferred Regimens

- FOLFOX<sup>10</sup>

##### Other Recommended Regimens

- FOLFIRI<sup>11</sup> (category 2B)
- Regorafenib<sup>12</sup> (category 2B)
- See also: Preferred and Other Recommended Regimens for Unresectable and Metastatic Disease above<sup>f</sup>

##### Useful in Certain Circumstances<sup>f</sup>

- For *NTRK* gene fusion-positive tumors:
  - Entrectinib<sup>5-7</sup>
  - Larotrectinib<sup>8</sup>
- For MSI-H/dMMR tumors/TMB-H tumors:
  - Pembrolizumab<sup>d,e,g,9,13,14</sup>
- For cholangiocarcinoma with *FGFR2* fusions or rearrangements:
  - Pemigatinib<sup>15</sup>
  - Infigratinib<sup>16</sup>
- For cholangiocarcinoma with *IDH1* mutations
  - Ivosidenib<sup>17</sup>
- For *BRAF*-V600E mutated tumors
  - Dabrafenib + trametinib<sup>18,19</sup>
- Nivolumab<sup>e,g,20</sup> (category 2B)
- Lenvatinib + pembrolizumab<sup>e,g,21</sup> (category 2B)
- For MSI-H/dMMR tumors
  - Dostarlimab-gxly<sup>e,g,h,22,23</sup> (category 2B)

<sup>d</sup> There are limited clinical trial data to support pembrolizumab in this setting. Sicklick JK, Kato S, Okamura R, et al. Molecular profiling of cancer patients enables personalized combination therapy: the I-PREDICT study. Nat Med 2019;25:744-750.

<sup>e</sup> See [NCCN Guidelines for Management of Immunotherapy-Related Toxicities](#).

<sup>f</sup> Treatment selection depends on clinical factors including previous treatment regimen/agent and extent of liver dysfunction.

<sup>g</sup> For patients who have not been previously treated with a checkpoint inhibitor because there is a lack of data for subsequent use of immunotherapy in patients who have previously been treated with a checkpoint inhibitor.

<sup>h</sup> Dostarlimab-gxly is a recommended treatment option for patients with MSI-H/dMMR recurrent or advanced tumors that have progressed on or following prior treatment and who have no satisfactory alternative treatment options.

**Note:** All recommendations are category 2A unless otherwise indicated.

**Clinical Trials:** NCCN believes that the best management of any patient with cancer is in a clinical trial. Participation in clinical trials is especially encouraged.

**PRINCIPLES OF SYSTEMIC THERAPY  
REFERENCES**

- <sup>1</sup> Shroff RT, Javle MM, Xiao L, et al. Gemcitabine, cisplatin, and nab-paclitaxel for the treatment of advanced biliary tract cancers: a phase 2 clinical trial. *JAMA Oncol* 2019;5:824-830.
- <sup>2</sup> Horgan AM, Amir E, Walter T, Knox JJ. Adjuvant therapy in the treatment of biliary tract cancer: a systemic review and meta-analysis. *J Clin Oncol* 2012;30:1934-1940.
- <sup>3</sup> Primrose JN, Fox RP, Palmer DH, et al. Capecitabine compared with observation in resected biliary tract cancer (BILCAP): a randomised, controlled, multicentre, phase 3 study. *Lancet Oncol* 2019;20:663-673.
- <sup>4</sup> Valle JW, Wasan HS, Palmer DH, et al. Cisplatin plus gemcitabine versus gemcitabine for biliary tract cancer. *N Eng J Med* 2010;362:1273-1281.
- <sup>5</sup> Demetri GD, Paz-Ares LG, Farago AF, et al. Efficacy and safety of entrectinib in patients with NTRK fusion-positive (NTRK-fp) tumors: pooled analysis of STARTRK-2, STARTRK-1 and ALKA-372-001. *ESMO Congress* 2018.
- <sup>6</sup> Drilon A, Siena S, Ou SI, et al. Safety and antitumor activity of the multitargeted pan-TRK, ROS1, and ALK inhibitor entrectinib: Combined results from two phase I trials (ALKA-372-001 and STARTRK-1). *Cancer Discov* 2017;7:400-409.
- <sup>7</sup> Doebele RC, Drilon A, Paz-Ares L, et al. Entrectinib in patients with advanced or metastatic NTRK fusion-positive solid tumours: integrated analysis of three phase 1-2 trials. *Lancet Oncol* 2020;21:271-282.
- <sup>8</sup> Drilon A, Laetsch TW, Kummar S, et al. Efficacy of larotrectinib in TRK fusion-positive cancers in adults and children. *N Engl J Med* 2018;378:731-739.
- <sup>9</sup> Le DT, Durham JN, Smith KN, et al. Mismatch repair deficiency predicts response of solid tumors to PD-1 blockade. *Science* 2017;357:409-413.
- <sup>10</sup> Lamarca A, Palmer DH, Wasan HS, et al. ABC-06 | A randomised phase III, multi-centre, open-label study of active symptom control (ASC) alone or ASC with oxaliplatin / 5-FU chemotherapy (ASC+mFOLFOX) for patients (pts) with locally advanced / metastatic biliary tract cancers (ABC) previously-treated with cisplatin/ gemcitabine (CisGem) chemotherapy [abstract]. *J Clin Oncol* 2019; 37(Suppl 15):Abstract 4003.
- <sup>11</sup> Caparica R, Lengele A, Bekolo W, Hendlisz A. FOLFIRI as second-line treatment of metastatic biliary tract cancer patients. *Autops Case Rep* 2019;9:e2019087.
- <sup>12</sup> Sun W, Patel A, Normolle D, et al. A phase 2 trial of regorafenib as a single agent in patients with chemotherapy-refractory, advanced, and metastatic biliary tract adenocarcinoma. *Cancer* 2019;125:902-909.
- <sup>13</sup> Marabelle A, Le DT, Ascierto PA, et al. Efficacy of pembrolizumab in patients with noncolorectal high microsatellite instability/mismatch repair-deficient cancer: Results from the phase II KEYNOTE-158 study. *J Clin Oncol* 2020;38:1-10.
- <sup>14</sup> Merino DM, McShane LM, Fabrizio D, et al. Establishing guidelines to harmonize tumor mutational burden (TMB): in silico assessment of variation in TMB quantification across diagnostic platforms: phase I of the Friends of Cancer Research TMB Harmonization Project. *J Immunother Cancer* 2020;8:e000147
- <sup>15</sup> Abou-Alfa GK, Sahai V, Hollebecque A, et al. Pemigatinib for previously treated, locally advanced or metastatic cholangiocarcinoma: a multicentre, open-label, phase 2 study. *Lancet Oncol* 2020;21:671-684.
- <sup>16</sup> Javle M, Roychowdhury S, Kelley RK, et al. Final results from a phase II study of infigratinib (BGJ398), an FGFR-selective tyrosine kinase inhibitor, in patients with previously treated advanced cholangiocarcinoma harboring an FGFR2 gene fusion or rearrangement. *J Clin Oncol* 2021;39:265-265
- <sup>17</sup> Abou-Alfa GK, Macarulla T, Javle MM, et al. Ivosidenib in *IDH1*-mutant, chemotherapy-refractory cholangiocarcinoma (ClarIDHy): a multicentre, randomised, double-blind, placebo-controlled, phase 3 study. *Lancet Oncol* 2020;21:796-807.
- <sup>18</sup> Subbiah V, Lassen U, Élez E, et al. Dabrafenib plus trametinib in patients with BRAF<sup>V600E</sup>-mutated biliary tract cancer (ROAR): a phase 2, open-label, single-arm, multicentre basket trial. *Lancet Oncol* 2020;21:1234-1243.
- <sup>19</sup> Salama AKS, Li S, Macrae ER, et al. Dabrafenib and trametinib in patients with tumors with *BRAF*<sup>V600E</sup> mutations: Results of the NCI-MATCH trial subprotocol H. *J Clin Oncol* 2020;38:3895-3904.

**Note:** All recommendations are category 2A unless otherwise indicated.**Clinical Trials:** NCCN believes that the best management of any patient with cancer is in a clinical trial. Participation in clinical trials is especially encouraged.



### PRINCIPLES OF SYSTEMIC THERAPY REFERENCES

- <sup>20</sup> Kim RD, Chung V, Alese OB, et al. A Phase 2 Multi-institutional Study of Nivolumab for Patients With Advanced Refractory Biliary Tract Cancer. *JAMA Oncol.* 2020;6:888-894.
- <sup>21</sup> Lwin, Z, Gomez-Roca, C, Saada-Bouazid E, et al. LEAP-005: Phase II study of lenvatinib (len) plus pembrolizumab (pembro) in patients (pts) with previously treated advanced solid tumors. *Ann. Oncol.* 2020;31:S1142-S1215.
- <sup>22</sup> Andre T, Berton D, Curigliano G, et al. Safety and efficacy of anti-PD-1 antibody dostarlimab in patients (pts) with mismatch repair-deficient (dMMR) solid cancers: Results from GARNET study [abstract]. *J Clin Oncol* 2021;39:Abstract 9.
- <sup>23</sup> Berton D, Banerjee SN, Curigliano G, et al. Antitumor activity of dostarlimab in patients with mismatch repair-deficient/microsatellite instability-high tumors: A combined analysis of two cohorts in the GARNET study [abstract]. *J Clin Oncol* 2021;39:Abstract 2564.

**Note:** All recommendations are category 2A unless otherwise indicated.

**Clinical Trials:** NCCN believes that the best management of any patient with cancer is in a clinical trial. Participation in clinical trials is especially encouraged.



### American Joint Committee on Cancer (AJCC) TNM Staging for Hepatocellular Cancer (8th ed., 2017)

**Table 1. Definitions for T, N, M**

<b>T</b>	<b>Primary Tumor</b>
<b>TX</b>	Primary tumor cannot be assessed
<b>T0</b>	No evidence of primary tumor
<b>T1</b>	Solitary tumor ≤2 cm, or >2 cm without vascular invasion
T1a	Solitary tumor ≤2 cm
T1b	Solitary tumor >2 cm without vascular invasion
<b>T2</b>	Solitary tumor >2 cm with vascular invasion, or multiple tumors, none >5 cm
<b>T3</b>	Multiple tumors, at least one of which is >5 cm
<b>T4</b>	Single tumor or multiple tumors of any size involving a major branch of the portal vein or hepatic vein, or tumor(s) with direct invasion of adjacent organs other than the gallbladder or with perforation of visceral peritoneum
<b>N</b>	
<b>Regional Lymph Nodes</b>	
<b>NX</b>	Regional lymph nodes cannot be assessed
<b>N0</b>	No regional lymph node metastasis
<b>N1</b>	Regional lymph node metastasis
<b>M</b>	
<b>Distant Metastasis</b>	
<b>M0</b>	No distant metastasis
<b>M1</b>	Distant metastasis

**Table 2. AJCC Prognostic Groups**

	<b>T</b>	<b>N</b>	<b>M</b>
<b>Stage IA</b>	T1a	N0	M0
<b>Stage IB</b>	T1b	N0	M0
<b>Stage II</b>	T2	N0	M0
<b>Stage IIIA</b>	T3	N0	M0
<b>Stage IIIB</b>	T4	N0	M0
<b>Stage IVA</b>	Any T	N1	M0
<b>Stage IVB</b>	Any T	Any N	M1

### Histologic Grade (G)

<b>GX</b>	Grade cannot be accessed
<b>G1</b>	Well differentiated
<b>G2</b>	Moderately differentiated
<b>G3</b>	Poorly differentiated
<b>G4</b>	Undifferentiated

### Fibrosis Score (F)

The fibrosis score as defined by Ishak is recommended because of its prognostic value in overall survival. This scoring system uses a 0-6 scale.

<b>F0</b>	Fibrosis score 0-4 (none to moderate fibrosis)
<b>F1</b>	Fibrosis score 5-6 (severe fibrosis or cirrhosis)

Used with permission of the American College of Surgeons, Chicago, Illinois. The original source for this information is the AJCC Cancer Staging Manual, Eighth Edition (2017) published by Springer International Publishing.

[Continued](#)



### American Joint Committee on Cancer (AJCC) TNM Staging for Gallbladder Carcinoma (8th ed., 2017)

**Table 3. Definitions for T, N, M**

<b>T</b>	<b>Primary Tumor</b>
<b>TX</b>	Primary tumor cannot be assessed
<b>T0</b>	No evidence of primary tumor
<b>Tis</b>	Carcinoma <i>in situ</i>
<b>T1</b>	Tumor invades lamina propria or muscular layer
T1a	Tumor invades lamina propria
T1b	Tumor invades muscle layer
<b>T2</b>	Tumor invades the perimuscular connective tissue on the peritoneal side, without involvement of the serosa (visceral peritoneum) Or tumor invades the perimuscular connective tissue on the hepatic side, with no extension into the liver
T2a	Tumor invades the perimuscular connective tissue on the peritoneal side, without involvement of the serosa (visceral peritoneum)
T2b	Tumor invades the perimuscular connective tissue on the hepatic side, with no extension into the liver
<b>T3</b>	Tumor perforates the serosa (visceral peritoneum) and/or directly invades the liver and/or one other adjacent organ or structure, such as the stomach, duodenum, colon, pancreas, omentum, or extrahepatic bile ducts
<b>T4</b>	Tumor invades main portal vein or hepatic artery or invades two or more extrahepatic organs or structures

#### **N Regional Lymph Nodes**

<b>NX</b>	Regional lymph nodes cannot be assessed
<b>N0</b>	No regional lymph node metastasis
<b>N1</b>	Metastases to one to three regional lymph nodes
<b>N2</b>	Metastases to four or more regional lymph nodes

#### **M Distant Metastasis**

<b>M0</b>	No distant metastasis
<b>M1</b>	Distant metastasis

**Table 4. AJCC Prognostic Groups**

	<b>T</b>	<b>N</b>	<b>M</b>
<b>Stage 0</b>	Tis	N0	M0
<b>Stage I</b>	T1	N0	M0
<b>Stage IIA</b>	T2a	N0	M0
<b>Stage IIB</b>	T2b	N0	M0
<b>Stage IIIA</b>	T3	N0	M0
<b>Stage IIIB</b>	T1-3	N1	M0
<b>Stage IVA</b>	T4	N0-1	M0
<b>Stage IVB</b>	Any T	N2	M0
	Any T	Any N	M1

#### **Histologic Grade (G)**

<b>GX</b>	Grade cannot be assessed
<b>G1</b>	Well differentiated
<b>G2</b>	Moderately differentiated
<b>G3</b>	Poorly differentiated

Used with permission of the American College of Surgeons, Chicago, Illinois. The original source for this information is the AJCC Cancer Staging Manual, Eighth Edition (2017) published by Springer International Publishing.

[Continued](#)





### American Joint Committee on Cancer (AJCC) TNM Staging for Intrahepatic Bile Duct Tumors (8th ed., 2017)

**Table 5. Definitions for T, N, M**

<b>T</b>	<b>Primary Tumor</b>
<b>TX</b>	Primary tumor cannot be assessed
<b>T0</b>	No evidence of primary tumor
<b>Tis</b>	Carcinoma <i>in situ</i> (intraductal tumor)
<b>T1</b>	Solitary tumor without vascular invasion, ≤5 cm or >5 cm
T1a	Solitary tumor ≤5 cm without vascular invasion
T1b	Solitary tumor >5 cm without vascular invasion
<b>T2</b>	Solitary tumor with intrahepatic vascular invasion or multiple tumors, with or without vascular invasion
<b>T3</b>	Tumor perforating the visceral peritoneum
<b>T4</b>	Tumor involving local extrahepatic structures by direct invasion
<b>N</b>	
<b>Regional Lymph Nodes</b>	
<b>NX</b>	Regional lymph nodes cannot be assessed
<b>N0</b>	No regional lymph node metastasis
<b>N1</b>	Regional lymph node metastasis present
<b>M</b>	
<b>Distant Metastasis</b>	
<b>M0</b>	No distant metastasis
<b>M1</b>	Distant metastasis present

**Table 6. AJCC Prognostic Groups**

	<b>T</b>	<b>N</b>	<b>M</b>
<b>Stage 0</b>	Tis	N0	M0
<b>Stage IA</b>	T1a	N0	M0
<b>Stage IB</b>	T1b	N0	M0
<b>Stage II</b>	T2	N0	M0
<b>Stage IIIA</b>	T3	N0	M0
<b>Stage IIIB</b>	T4	N0	M0
	Any T	N1	M0
<b>Stage IV</b>	Any T	Any N	M1

### Histologic Grade (G)

<b>GX</b>	Grade cannot be assessed
<b>G1</b>	Well differentiated
<b>G2</b>	Moderately differentiated
<b>G3</b>	Poorly differentiated

Used with permission of the American College of Surgeons, Chicago, Illinois. The original source for this information is the AJCC Cancer Staging Manual, Eighth Edition (2017) published by Springer International Publishing.

[Continued](#)



### American Joint Committee on Cancer (AJCC) TNM Staging for Perihilar Bile Duct Tumors (8th ed., 2017)

**Table 7. Definitions for T, N, M**

<b>T</b>	<b>Primary Tumor</b>
<b>TX</b>	Primary tumor cannot be assessed
<b>T0</b>	No evidence of primary tumor
<b>Tis</b>	Carcinoma <i>in situ</i> /high-grade dysplasia
<b>T1</b>	Tumor confined to the bile duct, with extension up to the muscle layer or fibrous tissue
<b>T2</b>	Tumor invades beyond the wall of the bile duct to surrounding adipose tissue, or tumor invades adjacent hepatic parenchyma
<b>T2a</b>	Tumor invades beyond the wall of the bile duct to surrounding adipose tissue
<b>T2b</b>	Tumor invades adjacent hepatic parenchyma
<b>T3</b>	Tumor invades unilateral branches of the portal vein or hepatic artery
<b>T4</b>	Tumor invades main portal vein or its branches bilaterally, or the common hepatic artery; or unilateral second-order biliary radicals bilaterally with contralateral portal vein or hepatic artery involvement
<b>N</b>	<b>Regional Lymph Nodes</b>
<b>NX</b>	Regional lymph nodes cannot be assessed
<b>N0</b>	No regional lymph node metastasis
<b>N1</b>	One to three positive lymph nodes typically involving the hilar, cystic duct, common bile duct, hepatic artery, posterior pancreatoduodenal, and portal vein lymph nodes
<b>N2</b>	Four or more positive lymph nodes from the sites described for N1

<b>M</b>	<b>Distant Metastasis</b>
<b>M0</b>	No distant metastasis
<b>M1</b>	Distant metastasis

**Table 8. AJCC Prognostic Groups**

	<b>T</b>	<b>N</b>	<b>M</b>
<b>Stage 0</b>	Tis	N0	M0
<b>Stage I</b>	T1	N0	M0
<b>Stage II</b>	T2a-b	N0	M0
<b>Stage IIIA</b>	T3	N0	M0
<b>Stage IIIB</b>	T4	N0	M0
<b>Stage IIIC</b>	Any T	N1	M0
<b>Stage IVA</b>	Any T	N2	M0
<b>Stage IVB</b>	Any T	Any N	M1

### Histologic Grade (G)

<b>GX</b>	Grade cannot be assessed
<b>G1</b>	Well differentiated
<b>G2</b>	Moderately differentiated
<b>G3</b>	Poorly differentiated

Used with permission of the American College of Surgeons, Chicago, Illinois. The original source for this information is the AJCC Cancer Staging Manual, Eighth Edition (2017) published by Springer International Publishing.

[Continued](#)



### American Joint Committee on Cancer (AJCC) TNM Staging for Distal Bile Ducts Tumors (8th ed., 2017)

**Table 9. Definitions for T, N, M**

<b>T</b>	<b>Primary Tumor</b>
<b>TX</b>	Primary tumor cannot be assessed
<b>Tis</b>	Carcinoma in situ/high-grade dysplasia
<b>T1</b>	Tumor invades the bile duct wall with a depth less than 5 mm
<b>T2</b>	Tumor invades the bile duct wall with a depth of 5–12 mm
<b>T3</b>	Tumor invades the bile duct wall with a depth greater than 12 mm
<b>T4</b>	Tumor involves the celiac axis, superior mesenteric artery, and/or common hepatic artery
<b>N</b>	
	<b>Regional Lymph Nodes</b>
<b>NX</b>	Regional lymph nodes cannot be assessed
<b>N0</b>	No regional lymph node metastasis
<b>N1</b>	Metastasis in one to three regional lymph nodes
<b>N2</b>	Metastasis in four or more regional lymph nodes
<b>M</b>	
	<b>Distant Metastasis</b>
<b>M0</b>	No distant metastasis
<b>M1</b>	Distant metastasis

**Table 10. AJCC Prognostic Groups**

	<b>T</b>	<b>N</b>	<b>M</b>
<b>Stage 0</b>	Tis	N0	M0
<b>Stage I</b>	T1	N0	M0
<b>Stage IIA</b>	T1	N1	M0
	T2	N0	M0
<b>Stage IIB</b>	T2	N1	M0
	T3	N0	M0
	T3	N1	M0
<b>Stage IIIA</b>	T1	N2	M0
	T2	N2	M0
	T3	N2	M0
<b>Stage IIIB</b>	T4	N0	M0
	T4	N1	M0
	T4	N2	M0
<b>Stage IV</b>	Any T	Any N	M1

### Histologic Grade (G)

<b>GX</b>	Grade cannot be assessed
<b>G1</b>	Well differentiated
<b>G2</b>	Moderately differentiated
<b>G3</b>	Poorly differentiated

Used with permission of the American College of Surgeons, Chicago, Illinois. The original source for this information is the AJCC Cancer Staging Manual, Eighth Edition (2017) published by Springer International Publishing.



### NCCN Categories of Evidence and Consensus

<b>Category 1</b>	Based upon high-level evidence, there is uniform NCCN consensus that the intervention is appropriate.
<b>Category 2A</b>	Based upon lower-level evidence, there is uniform NCCN consensus that the intervention is appropriate.
<b>Category 2B</b>	Based upon lower-level evidence, there is NCCN consensus that the intervention is appropriate.
<b>Category 3</b>	Based upon any level of evidence, there is major NCCN disagreement that the intervention is appropriate.

All recommendations are category 2A unless otherwise indicated.

### NCCN Categories of Preference

<b>Preferred intervention</b>	Interventions that are based on superior efficacy, safety, and evidence; and, when appropriate, affordability.
<b>Other recommended intervention</b>	Other interventions that may be somewhat less efficacious, more toxic, or based on less mature data; or significantly less affordable for similar outcomes.
<b>Useful in certain circumstances</b>	Other interventions that may be used for selected patient populations (defined with recommendation).

All recommendations are considered appropriate.



## Discussion

This discussion corresponds to the NCCN Guidelines for Hepatobiliary Cancers. Last updated: September 21<sup>st</sup>, 2021.

## Table of Contents

<b>Overview .....</b>	<b>MS-2</b>
<b>Literature Search Criteria and Guidelines Update Methodology .....</b>	<b>MS-2</b>
<b>Hepatocellular Carcinoma.....</b>	<b>MS-2</b>
Risk Factors and Epidemiology .....	MS-2
Screening for HCC.....	MS-5
Diagnosis.....	MS-6
Initial Workup.....	MS-9
Pathology and Staging .....	MS-11
Treatment Options .....	MS-13
<b>Biliary Tract Cancers.....</b>	<b>MS-36</b>
Gallbladder Cancer .....	MS-36
Cholangiocarcinomas.....	MS-42
Adjuvant Chemotherapy and Chemoradiation for Biliary Tract Cancers .....	MS-50
Treatment for Advanced Biliary Tract Cancers.....	MS-52
<b>Summary.....</b>	<b>MS-57</b>
<b>Figure 1: Classification of Cholangiocarcinoma.....</b>	<b>MS-59</b>
<b>References.....</b>	<b>MS-60</b>



### Overview

Hepatobiliary cancers are highly lethal cancers including a spectrum of invasive carcinomas arising in the liver (hepatocellular carcinoma; HCC), gall bladder, and bile ducts (intrahepatic and extrahepatic cholangiocarcinoma). Gallbladder cancer and cholangiocarcinomas are collectively known as biliary tract cancers. In 2020, it was estimated that 42,810 people in the United States would be diagnosed with liver cancer and intrahepatic bile duct cancer and an additional 11,980 people would be diagnosed with gallbladder cancer or other biliary tract cancer. Approximately 30,160 deaths from liver or intrahepatic bile duct cancer, and 4,090 deaths due to gallbladder cancer or other biliary tract cancer were anticipated.<sup>1</sup>

The NCCN Guidelines for Hepatobiliary Cancers are the work of the members of the NCCN Hepatobiliary Cancers Guidelines Panel. The types of hepatobiliary cancers covered in these guidelines include: HCC, gallbladder cancer, and intrahepatic and extrahepatic cholangiocarcinoma. Guidelines for HCC are consistent with those offered by the European Association for the Study of the Liver/European Organisation for Research and Treatment of Cancer and the consensus statement from the 2009 Asian Oncology Summit.<sup>2</sup> However, some discrepancies exist regarding treatment and surveillance, largely due to geographical differences such as available resources. By definition, the NCCN Guidelines cannot incorporate all possible clinical variations and are not intended to replace good clinical judgment or individualization of treatments. Although not explicitly stated at every decision point of the guidelines, participation in prospective clinical trials is the preferred option for treatment of patients with hepatobiliary cancers.

### Literature Search Criteria and Guidelines Update Methodology

Prior to the update of this version of the NCCN Guidelines for Hepatobiliary Cancers, an electronic search of the PubMed database was performed to obtain key literature in the field of hepatobiliary cancers, using the following search terms: (hepatocellular carcinoma) OR (liver cancer) OR (biliary tract cancer) OR (gallbladder cancer) OR (cholangiocarcinoma). The PubMed database was chosen because it remains the most widely used resource for medical literature and indexes only peer-reviewed biomedical literature.<sup>3</sup>

The search results were narrowed by selecting studies in humans published in English. Results were confined to the following article types: Clinical Trial, Phase II; Clinical Trial, Phase III; Clinical Trial, Phase IV; Practice Guideline; Guidelines; Randomized Controlled Trial; Meta-Analysis; Systematic Reviews; and Validation Studies.

The data from key PubMed articles and articles from additional sources deemed as relevant to these Guidelines and discussed by the panel have been included in this version of the Discussion section. Recommendations for which high-level evidence is lacking are based on the panel's review of lower-level evidence and expert opinion.

The complete details of the development and update of the NCCN Guidelines are available on the NCCN website ([www.NCCN.org](http://www.NCCN.org)).

### Hepatocellular Carcinoma

#### Risk Factors and Epidemiology

Incidence and mortality rates for most cancers are declining; however, the incidence and mortality rates for liver cancer are increasing.<sup>4-6 7,8</sup> Five-year survival rates (based on SEER data from 2006–2012) are lowest for blacks and American Indian/Alaska Natives who were diagnosed with liver





and intrahepatic bile duct cancer.<sup>7</sup> Forecast analyses predict that rates will be highest in blacks and Hispanics over the next 15 years.<sup>9</sup> These analyses also predict increasing incidence rates in those born between 1950 and 1959, due to high rates of hepatitis C viral infection in this age group.

The major risk factors for the development of HCC are cirrhosis and chronic liver disease, regardless of etiology.<sup>10,11</sup> Specific risk factors include viral infections caused by hepatitis B virus (HBV) and/or hepatitis C virus (HCV), chronic alcohol consumption, particular comorbidities or other conditions such as non-alcoholic fatty liver disease (NAFLD), nonalcoholic steatohepatitis (NASH), genetic hemochromatosis (GH), coinfection with HBV/HCV, and human immunodeficiency virus (HIV).<sup>4,12-18</sup> A retrospective analysis of patients at liver transplantation centers in the United States found that nearly 50% and about 15% of patients were infected with HBV or HCV, respectively, with approximately 5% of patients having markers of both hepatitis B and hepatitis C infection.<sup>19</sup> Seropositivity for hepatitis B e antigen (HBeAg) and hepatitis B surface antigen (HBsAg) are associated with an increased risk for HCC in patients with chronic hepatitis B viral infection.<sup>20,21</sup> Data from large population-based studies have also identified high serum HBV DNA and HCV RNA viral load as independent risk factors for developing HCC in patients with chronic infection.<sup>22-25</sup>

The incidence of HCC is increasing in the United States, particularly in the population infected with HCV. The annual incidence rate of HCC among patients with HCV-related cirrhosis has been estimated to be between 2% and 8%.<sup>6</sup> However, HCV often goes undetected, making these calculations difficult to interpret. Although it has been reported that the number of cases of hepatitis C infection diagnosed per year in the United States is declining, it is likely that the observed increase in the number of cases of HCV-related HCC is associated with the often prolonged period

between viral infection and the manifestation of HCC.<sup>26,27</sup> There is strong evidence that direct-acting antivirals (DAAs) improve sustained virologic response in patients with HCV,<sup>28,29</sup> which in turn may eventually decrease incidence of HCC.<sup>30,31</sup>

Globally, HBV is the leading cause of HCC incidence and mortality.<sup>5</sup> Approximately 1.5 million people in the United States are chronically infected with HBV.<sup>32,33</sup> Results from a prospective controlled study showed the annual incidence of HCC to be 0.5% in carriers of the virus without liver cirrhosis and 2.5% in those with known cirrhosis,<sup>34</sup> although studies have shown wide variation in the annual incidence rate of HCC among individuals with chronic hepatitis B infection.<sup>35</sup> A meta-analysis including 68 studies with 27,854 patients with untreated HBV showed an annual HCC incidence of 0.88 per 100 person-years (95% CI, 0.76–0.99), with higher incidence per 100 person-years for patients with cirrhosis (3.16; 95% CI, 2.58–3.74).<sup>36</sup> An analysis of 634 patients with HBV showed that long-term antiviral therapy was associated with reduced risk of HCC in patients without cirrhosis (standardized incidence ratio [SIR], 0.40; 95% CI, 0.20–0.80).<sup>37</sup> Analyses from universal HBV vaccination programs in Alaska and Taiwan showed that vaccination is associated with decreased HCC incidence in children and young adults.<sup>38-40</sup> Since universal HBV vaccination programs were implemented relatively recently, the potential efficacy of these programs in adults will likely not be seen for at least 10 to 20 years.

Non-viral causes associated with an increased risk for HCC include cirrhosis from any cause (eg, alcoholic cirrhosis); inherited errors of metabolism (relatively rare), such as hereditary hemochromatosis, porphyria cutanea tarda, and alpha-1 antitrypsin deficiency; Wilson's disease; and stage IV primary biliary cirrhosis.<sup>6,12,41</sup>

Alcoholic cirrhosis is a well-known risk factor for HCC,<sup>6</sup> although many of the studies evaluating the incidence rate of HCC in individuals with



# NCCN Guidelines Version 5.2021

## Hepatobiliary Cancers

alcohol-induced cirrhosis have been confounded by the presence of other risk factors such as viral hepatitis infection, which can interact synergistically in the pathogenesis of HCC.<sup>42,43</sup> It has been estimated that 60% to 80% of persons with HCC have underlying cirrhosis, possibly approaching 90% in the United States.<sup>44</sup> Importantly, certain populations chronically infected with HBV have been identified as being at increased risk for HCC in the absence of cirrhosis, especially when other risk factors are present,<sup>35</sup> and it has been estimated that 30% to 50% of patients with chronic hepatitis B viral infection who develop HCC do not have underlying cirrhosis.<sup>45</sup> Some risk factors for the development of HCC in HBV carriers without evidence of liver cirrhosis include active viral replication, high HBV DNA levels, and a family history of HCC.<sup>35,46</sup> Asian males  $\geq 40$  years, Asian females  $\geq 50$  years, and Black/African American men and women with hepatitis B are also at increased risk for HCC.<sup>6</sup> The presence of liver cirrhosis is usually considered to be a prerequisite for development of HCC in individuals with inherited metabolic diseases of the liver or liver disease with an autoimmune etiology.<sup>47-49</sup> Although the mechanism of HCC development differs according to the underlying disease, HCC typically occurs in the setting of a histologically abnormal liver. Hence, the presence of chronic liver disease represents a risk for development of HCC.<sup>12</sup> However, HCC may also develop in patients with normal livers and no known risk factors.<sup>50,51</sup>

GH is a condition characterized by excess iron absorption due to the presence of mutations in the *HFE* gene. A study from the National Center for Health Statistics found that patients with a known diagnosis of hemochromatosis at death were 23 times more likely to have primary liver neoplasms than those without GH. The annual incidence rates of HCC associated with cirrhosis due to GH have been sufficiently high (about 3%–4%), and the American Association for the Study of Liver Diseases (AASLD) guidelines recommend surveillance for this group of patients when cirrhosis is present.<sup>35</sup>

Metabolic disorders (ie, obesity, diabetes, impaired glucose metabolism, metabolic syndrome, NAFLD) are associated with increased risk of HCC.<sup>16,52-54</sup> It is anticipated that sequelae of NAFLD, such as non-alcoholic steatohepatitis (NASH, a spectrum of conditions characterized by histologic findings of hepatic steatosis with inflammation in individuals who consume little or no alcohol) will replace hepatitis as the most common underlying cause of HCC.<sup>55-57</sup> Estimations of the prevalence of NASH in the United States are in the range of 3% to 5%, indicating that this sizable subpopulation is at risk for cirrhosis and development of HCC.<sup>58</sup> In one study, 12.8% of 195 patients with cirrhosis secondary to NASH developed HCC at a median follow-up of 3.2 years, with an annual incidence rate of HCC of 2.6%.<sup>17</sup> Available epidemiologic evidence supports an association between NAFLD or NASH and an increased HCC risk predominantly in individuals with cirrhosis.<sup>16,59</sup> However, several studies suggest that HCC may be somewhat less likely to develop in the setting of NASH-associated cirrhosis compared with cirrhosis due to hepatitis C infection.<sup>60,61</sup> The American Gastroenterological Association clinical practice update recommends that screening for HCC in patients with cirrhosis due to NAFLD be considered.<sup>62</sup> HCC screening should also be considered in patients with NAFLD with noninvasive markers that provide evidence of advanced liver fibrosis or cirrhosis.

Fibrolamellar hepatocellular carcinoma (FLHC) is a variant of HCC that makes up a very small fraction of all HCCs. Patients with FLHC tend to be younger and have a generally better prognosis than those with HCC,<sup>63-65</sup> though recurrences following resection are common.<sup>64</sup> FLHC also is rarely, if ever, associated with hepatitis, cirrhosis, or elevated alpha-fetoprotein (AFP) levels.<sup>64,66</sup> Though cross-sectional imaging results may be strongly suggestive of FLHC, histologic confirmation is needed.<sup>67</sup> A molecular target to identify FLHC, the DNAJB1-PRKACA chimera, has been found,<sup>68</sup> which accurately identifies FLHC in 79% to 100% of cases.<sup>68-71</sup> Complete resection is the only potentially curative option.<sup>67</sup> One clinical trial is



currently investigating systemic therapy for treatment of FLHC (NCT01642186), but no effective regimen has been identified. An unplanned analysis from a phase II study investigating the efficacy of everolimus, combined leuprolide and letrozole, or the combination of all 3 drugs revealed that the primary endpoint of a 6-month progression-free survival (PFS) was not met.<sup>72</sup> Given its rarity, the panel does not provide treatment recommendations for FLHC in these guidelines.

### Screening for HCC

The purpose of a cancer screening test is to identify the presence of a specific cancer in an asymptomatic individual in a situation where early detection has the potential to favorably impact patient outcome. The panel supports the recommendation by the AASLD that HCC screening in patients with risk factors for HCC should consist of a program including standardized screening tests, recall procedures, and quality control procedures in place.<sup>73</sup> The AASLD and EASL-EORTC recommend that ultrasound (US) screening in at-risk patients be done every 6 months.<sup>6,73,74</sup>

Support for enrolling individuals at high risk for HCC in a screening program comes from a large randomized controlled trial (RCT) in China of 18,816 men and women with hepatitis B infection or a history of chronic hepatitis, defined as patients with abnormalities on serum liver tests lasting for 6 months or more. In this study, screening with serum AFP testing and liver US every 6 months was shown to result in a 37% reduction in HCC mortality, despite the fact that less than 60% of individuals in the screening arm completed the screening program.<sup>75</sup>

HCC screening should be carried out in at-risk populations regardless of age. In a prospective observational study of 638 patients with HCC in Singapore carried out over a 9-year period, patients 40 years or younger were more likely than older patients to harbor hepatitis B infection and to have more advanced disease at diagnosis.<sup>76</sup> Although survival did not

differ in the two groups overall, a significant survival benefit was observed for younger patients when the subgroup of patients with early-stage disease was considered.

AFP and liver US are the most widely used methods of screening for HCC.<sup>77</sup> A review of serum protein biomarkers for early detection of HCC showed that an AFP cut-off value of 100 ng/mL was associated with high specificity (99%) but low sensitivity (31%).<sup>78</sup> In a screening study involving a large population of patients in China infected with HBV or those with chronic hepatitis, and using an AFP cut-off of >20 ng/mL, the detection rate, false-positive rate, and positive predictive value with AFP alone were 69%, 5.0%, and 3.3%; with US alone were 84%, 2.9%, and 6.6%; and with the combination of AFP and US were 92%, 7.5%, and 3.0%.<sup>79</sup> These results demonstrate that US combined with AFP is a better modality for HCC screening than AFP testing alone. A study of 333 patients with HCC and HBV/HCV determined that patients with HCC diagnosed after surveillance with US and AFP had significantly longer overall survival (OS) and disease-free survival (DFS), compared to patients who had no surveillance prior to diagnosis.<sup>80</sup> Nevertheless, since US is highly operator dependent, the addition of AFP may increase the likelihood of detecting HCC in a screening setting. However, AFP is frequently normal in patients with early-stage disease and its utility as a screening biomarker is limited.<sup>81-83</sup> A recent meta-analysis including 32 studies with 13,367 patients with cirrhosis who were screened for HCC showed that US with AFP improves sensitivity for detection of HCC, compared to US alone (97% vs. 78%, respectively; relative risk [RR], 0.88; 95% CI, 0.83–0.93).<sup>84</sup> Due to the low cost and ease of use, AFP may have utility for enhancing detection of HCC when used in combination with US for screening at-risk individuals. A progressive elevation rate of ≥7 ng/mL per month may be more useful as a diagnostic tool for HCC, relative to use of a fixed cut point such as 200 ng/mL.<sup>85</sup>



# NCCN Guidelines Version 5.2021

## Hepatobiliary Cancers

In these guidelines, the populations considered to be “at risk” for HCC and likely to benefit from participation in an HCC screening program include patients with liver cirrhosis induced by viral (hepatitis B and C) as well as non-viral causes of cirrhosis (ie, alcoholic cirrhosis, GH, NAFLD or NASH, stage IV primary biliary cholangitis, alpha-1 antitrypsin deficiency) and hepatitis B carriers without cirrhosis, regardless of cause. Other less common causes of cirrhosis include secondary biliary cirrhosis, Wilson’s disease, sclerosing cholangitis, granulomatous disease, type IV glycogen storage disease, drug-induced liver disease, venous outflow obstruction, chronic right-sided heart failure, and tricuspid regurgitation.<sup>86</sup>

The panel recommends screening with US and AFP testing (every 6 months) for patients with established risk factors for HCC. Additional imaging (abdominal multiphasic CT or MRI) is recommended in the setting of a rising serum AFP or following identification of a liver mass nodule  $\geq 10$  mm on US, based on AASLD and LI-RADS (Liver Imaging Reporting and Data System) guidelines.<sup>6,87</sup> It is also reasonable to screen patients with cross-sectional imaging (CT or MRI), and this may be commonly employed, though not well-studied in the United States. Cost and availability limit the widespread use of screening using cross-sectional imaging. Liver masses  $< 10$  mm are difficult to definitively characterize through imaging. If nodules of this size are found, then US and AFP testing should be repeated in 3 to 6 months.

### Diagnosis

Localized HCC is asymptomatic for much of its natural history. Nonspecific symptoms associated with more advanced HCC can include jaundice, anorexia, weight loss, malaise, and upper abdominal pain. Physical signs of HCC can include hepatomegaly and ascites.<sup>56</sup> Paraneoplastic syndromes, although rare, also can occur and include hypercholesterolemia, erythrocytosis, hypercalcemia, and hypoglycemia.<sup>88</sup>

Combined hepatocellular-cholangiocarcinoma (cHCC-CC) is a rare hepatobiliary tumor type. Resection for those with early stage disease is the only potentially curative option.<sup>89-91</sup> Diagnosis of cHCC-CC through imaging is difficult since imaging characteristics consist of varying features of both HCC and cholangiocarcinoma.<sup>89,90,92</sup> Therefore, misdiagnosis may occur.<sup>90,93</sup> Further, though AFP levels may be elevated in patients with cHCC-CC, levels tend to not differ significantly from that of patients with HCC.<sup>94</sup> cHCC-CC may also be characterized by elevated serum CA 19-9, similar to intrahepatic cholangiocarcinoma.<sup>92,95</sup> If cHCC-CC is suspected, thorough pathology review is recommended. It should be noted that needle biopsies will not necessarily show both elements of the malignancy.

### Imaging

HCC lesions are characterized by arterial hypervascularity and “wash out” on portal venous phases, since they derive most of their blood supply from the hepatic artery. This is unlike the surrounding liver, which receives its blood supply from both the portal vein and hepatic artery.<sup>96</sup> Diagnostic HCC imaging involves the use of multiphasic liver protocol CT with multiphasic (eg, precontrast, arterial phase, portal venous phase, delayed) intravenous contrast-enhanced MRI.<sup>6,73</sup> The classic imaging profile associated with an HCC lesion is characterized by intense arterial uptake or enhancement followed by contrast washout or hypointensity in the delayed nonperipheral venous phase.<sup>6,87,97-101</sup> LI-RADS also considers enhancing capsule appearance and threshold growth compared to previous imaging as part of diagnosis using CT or MRI imaging.<sup>87</sup> The LI-RADS criteria are applicable only to those with cirrhosis and a biopsy may be necessary in patients without any history of liver disease.

Though contrast-enhanced ultrasound (CEUS) may be used at centers of expertise as a problem-solving tool for characterization of indeterminate nodules, it is not recommended by the panel for whole-liver assessment,





surveillance, or staging.<sup>102</sup> A meta-analysis including 241 studies showed that CT and MRI are more sensitive than US without contrast for detection of HCC.<sup>103</sup> Another meta-analysis that included only studies of patients with cirrhosis or chronic hepatitis ( $N = 30$ ) also showed that US is less sensitive than CT and MRI (60%, 68%, and 81%, respectively) for diagnosis of HCC, though it is the most specific (97%, 93%, and 85%, respectively).<sup>104</sup> A meta-analysis including 22 studies with 1721 patients with HCC showed that PET/CT may be useful for predicting prognosis (ie, OS and DFS,  $P < .001$ ),<sup>105</sup> but it is associated with low sensitivity for HCC detection.<sup>106,107</sup>

Multiple meta-analyses have shown that MRI is more sensitive for HCC diagnosis than CT.<sup>103,108,109</sup> However, one meta-analysis including 19 comprehensive comparisons did not find a statistically significant difference in specificity or in the positive likelihood ratio.<sup>109</sup> When comparing imaging modalities, it is important to keep in mind the quality of the images being compared, which likely differ between studies.

Contrast-enhanced MRI for detection of lesions up to 2 cm has acceptable sensitivity (78%) and excellent specificity (92%) when criteria are applied in appropriate clinical context in patients with known liver disease.<sup>110</sup> The results of a prospective study evaluating the accuracy of CEUS and dynamic contrast-enhanced MRI for the diagnosis of liver nodules 2 cm or smaller observed on screening US demonstrated that the diagnosis of HCC can be established without biopsy confirmation if both imaging studies are conclusive.<sup>99</sup> Comparing MRI to CEUS, the sensitivity was 61.7% versus 51.7%, the specificity was 96.6% versus 93.1%, the positive predictive value was 97.4% versus 93.9%, and the negative predictive value was 54.9% versus 50.9%.<sup>99</sup> However, as noted earlier, CEUS is not commonly utilized in the United States. Other investigators have suggested that a finding of classical arterial enhancement using a single imaging technique is sufficient to diagnose HCC in patients with cirrhosis

and liver nodules between 1 and 2 cm detected during surveillance, thereby reducing the need for a biopsy.<sup>111</sup> In the updated AASLD guidelines, the algorithms for liver nodules between 1 and 2 cm have been changed to reflect these considerations. LI-RADS also offers some guidance regarding the use of CEUS for the diagnosis of HCC.<sup>112</sup>

The NCCN Guidelines' recommendations for diagnostic imaging in the setting of high clinical suspicion for HCC (eg, following identification of a liver nodule on US or in the setting of a rising serum AFP level) apply only to patients with known risk factors for HCC and are adapted from the AASLD guidelines.<sup>6</sup> For these patients, as well as patients with an incidental liver mass or nodule found on US or on another imaging exam, the guidelines recommend evaluation using multiphasic abdominal contrast-enhanced CT or MRI to determine the enhancement characteristics, extent and number of lesions, vascular anatomy, and extrahepatic disease. Gadolinium contrast is preferred for MRI as hepatobiliary agents such as gadolinium ethoxybenzyl diethylenetriamine pentaacetic acid that require more subspecialized experience to interpret hepatobiliary phase imaging are not currently included in AASLD or LI-RADS interpretation. The quality of MRI is dependent on patient compliance, since some patients may be unable to hold their breath. If no mass is detected using multiphasic contrast-enhanced imaging, or if the observed lesion is definitely benign, then the patients should return to a screening program (ie, US and AFP in 6 months). If there is suspicion that the diagnostic imaging test yielded a false negative, then a different imaging method with or without AFP may be considered. If the observation is inconclusive (ie, not definitely HCC but not definitely benign), then multidisciplinary discussion and individualized workup may be pursued, including additional imaging or biopsy. Multidisciplinary team management has been associated with improved outcomes in HCC, including higher rates of treatment, higher rates of curative treatments in early stages, and prolonged survival in advanced disease.<sup>113-116</sup>



### **Serum Biomarkers**

Although serum AFP has long been used as a marker for HCC, it is not a sensitive or specific diagnostic test for HCC. Serum AFP levels >400 ng/mL are observed only in a small percentage of patients with HCC. In a series of 1158 patients with HCC, only 18% of patients had values >400 ng/mL and 46% of patients had normal serum AFP levels <20 ng/mL.<sup>117</sup> In patients with chronic liver disease, an elevated AFP could be more indicative of HCC than in non-infected patients.<sup>118</sup> Furthermore, AFP can also be elevated in pregnancy, and other cancers such as intrahepatic cholangiocarcinoma, some metastases from colon cancer, lymphoma, and germ cell tumors.<sup>35,119</sup> AFP testing can be useful in conjunction with other test results to guide the management of patients for whom a diagnosis of HCC is suspected. An elevated AFP level in conjunction with imaging results showing the presence of a growing liver mass has been shown to have a high positive predictive value for HCC in two retrospective analyses involving small numbers of patients.<sup>120,121</sup> However, the diagnostic accuracy of an absolute AFP cutoff value has not been validated in this setting, and such values may vary by institution and patient population.

Since the level of serum AFP may be elevated in those with certain nonmalignant conditions such as chronic HBV<sup>122</sup> or HCV or be within normal limits in up to 30% of patients with HCC,<sup>123</sup> the panel considers an imaging finding of classic enhancement to be more definitive in the diagnostic setting compared to AFP alone. Additional imaging studies (CT or MRI) are recommended for patients with a rising serum AFP level in the absence of a liver mass. If no liver mass is detected following measurement of an elevated AFP level, the patient should be followed with AFP testing and liver imaging. Further, assessment of AFP levels may be helpful in monitoring treatment response as appropriate (see *Surveillance* below).

Other serum biomarkers being studied in this setting include des-gamma-carboxy prothrombin (DCP), also known as protein induced by vitamin K absence or antagonist-II (PIVKA-II), and lens culinaris agglutinin-reactive AFP (AFP-L3), an isoform of AFP.<sup>44,124,125</sup> Although AFP was found to be more sensitive than DCP or AFP-L3 in detecting early-stage and very-early-stage HCC in a retrospective case-control study, none of these biomarkers was considered optimal in this setting.<sup>126</sup> A case-control study involving patients with hepatitis C enrolled in the large, randomized HALT-C trial who developed HCC showed that a combination of AFP and DCP is superior to either biomarker alone as a complementary assay to screening.<sup>82</sup>

The GALAD model, which accounts for gender, age, AFP-L3, AFP, and des-carboxy-prothrombin, is a serum biomarker model used to assess the risk of HCC in patients with chronic liver disease.<sup>127</sup> In validation studies, the GALAD model identified HCC cases in patients with chronic liver disease or nonalcoholic steatohepatitis with a high degree of accuracy.<sup>128-130</sup> The GALADUS score, which combines the GALAD score and US, was found to improve the performance of the GALAD score.<sup>129</sup>

### **Biopsy**

A diagnosis of HCC can often be made noninvasively by imaging in patients with established risk factors for HCC with diagnostic imaging findings on multiphase imaging as described above. However, there are a few clinical scenarios in which biopsy of a suspected HCC may be considered. First, biopsy may be considered when a lesion is suspicious for malignancy, but multiphasic CT or MRI results do not meet imaging criteria for HCC.<sup>6,74,81,100,131</sup> AASLD describes the limitations of biopsy in this scenario, specifically the cost, emotional distress for the patient, risk of complications, and potential sampling error for small lesions.<sup>73</sup> Second, biopsy may be done in patients who are not considered high risk for developing HCC (ie, patients who do not have cirrhosis, chronic HBV, or a





previous history of HCC). Third, biopsy may be indicated in patients with conditions associated with formation of nonmalignant nodules that may be confused with HCC during imaging. These conditions include cardiac cirrhosis, congenital hepatic fibrosis, or cirrhosis due to a vascular disorder such as Budd-Chiari syndrome, hereditary hemorrhagic telangiectasia, or nodular regenerative hyperplasia.<sup>132</sup> Finally, biopsy may be considered in patients with elevated CA 19-9 or carcinoembryonic antigen (CEA), in order to rule out intrahepatic cholangiocarcinoma or mixed HCC-cholangiocarcinoma<sup>133,134</sup> or in patients with history of another primary malignancy at risk for metastatic disease. If transplant or resection is a consideration, patients should be referred to a transplant center and/or hepatic surgeon before biopsy since biopsy may not be necessary in certain patients with resectable malignant-appearing masses.

Both core needle biopsy and fine-needle aspiration biopsy (FNAB) have advantages and disadvantages in this setting. For example, FNAB may be associated with a lower complication rate when sampling deeply situated lesions or those located near major blood vessels. In addition, the ability to rapidly stain and examine cytologic samples can provide for immediate determinations of whether a sufficient sample has been obtained, as well as the possibility of an upfront tentative diagnosis.<sup>135</sup> However, FNAB is highly dependent on the skill of the cytopathologist,<sup>136</sup> and there are reports of high false-negative rates<sup>99,137</sup> as well as the possibility of false-positive findings with this procedure.<sup>138</sup> Although a core needle biopsy is a more invasive procedure, it has the advantage of providing pathologic information on both cytology and tissue architecture. Furthermore, additional histologic and immunohistochemical tests can be performed on the paraffin wax-embedded sample.<sup>81,135,137</sup> However, some evidence indicates that a core needle biopsy does not provide an accurate determination of tumor grade.<sup>139</sup>

Nevertheless, the use of biopsy to diagnose HCC is limited by sampling error, particularly when lesions are <1 cm.<sup>35,44</sup> Patients with a nondiagnostic biopsy result should be followed closely, and subsequent additional imaging and/or biopsy is recommended if a change in nodule size is observed. The guidelines emphasize that a growing mass with a negative biopsy does not rule out HCC. Continual monitoring with a multidisciplinary review including surgeons is recommended since definitive resection may be considered.

### Initial Workup

The foundation of initial workup for patients with suspected HCC is a multidisciplinary evaluation including investigations of the etiologic origin of liver disease, a hepatitis panel for detection of hepatitis B and/or C viral infection (ie, HBsAg, hepatitis B surface antibody, hepatitis B core antibody [HBcAb], HBcAb IgM [recommended only in patients with acute viral hepatitis], and HCV antibodies), an assessment of the presence of comorbidity; imaging studies to detect the presence of metastatic disease, and an evaluation of hepatic function, including a determination of whether portal hypertension is present. The guidelines recommend confirmation of viral load in patients who test positive for HBsAg, HBcAb IgG (since an isolated HBcAb IgG may still indicate chronic HBV infection), and HCV antibodies. If viral load is positive, patients should be evaluated by a hepatologist for consideration of antiviral therapy.<sup>45,140</sup>

Common sites of HCC metastasis include the lung, adrenal glands, peritoneum, and bone.<sup>141,142</sup> Hence, routine chest CT is recommended since lung metastases are typically asymptomatic. Bone scan and/or additional bone imaging may be considered as clinically indicated if suspicious bone pain is present or cross-sectional imaging raises the possibility of bone metastases.<sup>143</sup> Multiphasic contrast-enhanced CT or MRI of the abdomen, CT of the chest, and CT/MRI of the pelvis is also used in the evaluation of the HCC tumor burden to detect the presence of



metastatic disease, nodal disease, and vascular invasion; to assess whether evidence of portal hypertension is present; to provide an estimate of the size and location of HCC and the extent of chronic liver disease; and, in the case of patients being considered for resection, to provide an estimate of the future liver remnant (FLR).<sup>98</sup> Enlarged lymph nodes are commonly seen in patients with viral hepatitis, primary biliary cirrhosis, and other underlying liver disorders that predispose patients to HCC.<sup>144</sup> Detection of nodal disease by cross-sectional imaging is non-specific and can be challenging in patients with hepatitis.

### **Assessment of Liver Function**

An initial assessment of hepatic function involves liver function testing including measurement of serum levels of bilirubin, aspartate aminotransferase (AST), alanine transaminase (ALT), alkaline phosphatase (ALP), measurement of prothrombin time (PT) expressed as international normalized ratio (INR), albumin, and platelet count (surrogate for portal hypertension). Other recommended tests include complete blood count (CBC), blood urea nitrogen (BUN), and creatinine to assess kidney function; creatinine is also an established prognostic marker in patients with liver disease.<sup>145</sup> Further assessment of hepatic functional reserve prior to hepatic resection in patients with cirrhosis may be performed with different tools such as US and MRI elastography (which may provide and quantify the degree of cirrhosis-related fibrosis), non-focal liver biopsy, and transjugular liver biopsy with pressure measurements.

The Child-Pugh classification has been traditionally used for the assessment of hepatic functional reserve in patients with cirrhosis.<sup>146,147</sup> The Child-Pugh score incorporates laboratory measurements (ie, serum albumin, bilirubin, PT) as well as more subjective clinical assessments of encephalopathy and ascites. It provides a general estimate of the liver function by classifying patients as having compensated (class A) or decompensated (classes B and C) cirrhosis. Advantages of the Child-Pugh

score include ease of performance (ie, can be done at the bedside) and the inclusion of clinical parameters.

An important additional assessment of liver function not included in the Child-Pugh score is an evaluation of signs of clinically significant portal hypertension (ie, esophagogastric varices, splenomegaly, splenorenal shunts and recanalization of the umbilical vein, thrombocytopenia). Evidence of portal hypertension may be evident on CT/MRI.<sup>98 146-149</sup> Esophageal varices may be evaluated using esophagogastroduodenoscopy (EGD) or contrast-enhanced cross-sectional imaging.

Model for End-Stage Liver Disease (MELD) is another system for the evaluation of hepatic reserve. MELD is a numerical scale ranging from 6 (less ill) to 40 (gravely ill) for individuals 12 years or older. It is derived using three laboratory values (serum bilirubin, creatinine, and INR) and was originally devised to provide an assessment of mortality for patients undergoing transjugular intrahepatic portosystemic shunts.<sup>150,151</sup> The MELD score has since been adopted by the United Network for Organ Sharing (UNOS; [www.unos.org](http://www.unos.org)) to stratify patients on the liver transplantation waiting list according to their risk of death within 3 months.<sup>152</sup> The MELD score has sometimes been used in place of the Child-Pugh score to assess prognosis in patients with cirrhosis. Advantages of the MELD score include the inclusion of a measurement of renal function and an objective scoring system based on widely available laboratory tests, although clinical assessments of ascites and encephalopathy are not included. It is currently unclear whether the MELD score is superior to the Child-Pugh score as a predictor of survival in patients with liver cirrhosis. The MELD score has not been validated as a predictor of survival in patients with cirrhosis who are not on a liver transplantation waiting list.<sup>153</sup> While the MELD model is used to stratify organ access for transplantation, it also favors patients with renal



dysfunction. Serum creatinine, an important component of the MELD score, can be an unreliable marker of renal dysfunction, especially in patients with cirrhosis.<sup>154</sup>

Albumin and bilirubin are objectively measured, while ascites and encephalopathy, other scoring parameters used to calculate the Child-Pugh score, are subjective. Therefore, another alternative to the Child-Pugh score is the Albumin-Bilirubin (ALBI) grade, a model proposed by Johnson et al that takes into account only serum bilirubin and albumin levels.<sup>155</sup> It has been shown to be especially helpful in predicting the survival outcome of patients with stable decompensated cirrhosis.<sup>156,157</sup> An analysis of almost 6000 patients from Europe, the United States, Japan, and China showed that the ALBI grade, which stratifies patients into three risk categories, performs as well as the Child-Pugh score.<sup>155</sup> Further, patients scored as Child-Pugh grade A were categorized into either ALBI grade 1 or 2.

The indocyanine green (ICG) clearance test is extensively used in Asia for the assessment of liver function prior to hepatic resection in patients with cirrhosis.<sup>158-159</sup> The Japanese evidence-based clinical guidelines for HCC recommend the ICG retention rate at 15 minutes (ICGR-15) after intravenous injection for the assessment of liver function prior to surgery.<sup>160</sup> However, this test is not widely used in Western countries.

## Pathology and Staging

### Pathology

Three gross morphologic types of HCC have been identified: nodular, massive, and diffuse. Nodular HCC is often associated with cirrhosis and is characterized by well-circumscribed nodules. The massive type of HCC, usually associated with a non-cirrhotic liver, occupies a large area with or without satellite nodules in the surrounding liver. The less common diffuse

type is characterized by diffuse hepatic involvement with many small indistinct tumor nodules throughout the liver.

### Staging

Clinical staging systems for the patient with cancer can provide a more accurate prognostic assessment before and after a particular treatment intervention, and they may be used to guide treatment decision-making including enrollment in clinical trials. Therefore, staging can have a critical impact on treatment outcome by facilitating appropriate patient selection for specific therapeutic interventions, and by providing risk stratification information following treatment. The key factors affecting prognosis in patients with HCC are the clinical stage, growth rate of the tumor, the general health of the patient, the liver function of the patient, and the treatments administered.<sup>161</sup> Many staging systems for patients with HCC have been devised.<sup>162,163</sup> Each of the staging systems includes variables that evaluate one or more of the factors listed above. For example, the Child-Pugh<sup>164</sup> and MELD scores<sup>150</sup> can be considered to be staging systems that evaluate aspects of liver function.

The AJCC staging system provides information on the pathologic characteristics of resected specimens only,<sup>165</sup> whereas the Okuda system incorporates aspects of liver function and tumor characteristics.<sup>166</sup> The French classification (GRETCH) system incorporates the Karnofsky performance score as well as measurements of liver function and serum AFP.<sup>167</sup> Several staging systems include all parameters from other staging systems as well as additional parameters. For example, the Chinese University Prognostic Index (CUPI) system<sup>168</sup> and the Japanese Integrated Staging (JIS)<sup>169</sup> scores incorporate the TNM staging system, and the Cancer of the Liver Italian Program (CLIP),<sup>170</sup> Barcelona Clinic Liver Cancer (BCLC),<sup>171</sup> SLiDe (stage, liver damage, DCP),<sup>172</sup> and JIS systems include the Child-Pugh score (with modified versions of CLIP and JIS substituting the MELD score for the Child-Pugh score).<sup>173-175</sup> In addition,



the BCLC system also incorporates the Okuda system, as well as other tumor characteristics, measurements of liver function, and patient performance status.<sup>176</sup>

Although some of these systems have been found to be applicable for all stages of HCC (eg, BCLC),<sup>44,176,177</sup> limitations of all of these systems have been identified. For example, the AJCC staging system has limited usefulness since most patients with HCC do not undergo surgery. An analysis from the SEER database (1998–2013) questioned the AJCC definition of T2 disease (solitary tumor >2 cm with vascular invasion; multiple tumors <5 cm).<sup>178</sup> Specifically, survival was significantly different for patients with solitary tumors >2 cm than multifocal tumors <5 cm ( $P < .001$ ), and, for patients with multifocal tumors <5 cm, survival was significantly associated with vascular invasion ( $P < .001$ ). A number of studies have shown that particular staging systems perform well for specific patient populations likely related to differing etiologies. Furthermore, staging systems may be used to direct treatment and/or to predict survival outcomes following a particular type of therapeutic intervention. For example, the AJCC staging system has been shown to accurately predict survival for patients who underwent orthotopic liver transplantation.<sup>179</sup> The CLIP, CUPI, and GRETCH staging systems have been shown to perform well in predicting survival in patients with advanced disease.<sup>180</sup>

The CLIP system has been specifically identified as being useful for staging patients who underwent transarterial chemoembolization (TACE) and those treated in a palliative setting.<sup>181,182</sup> The utility of the BCLC staging system with respect to stratifying patients with HCC according to the natural history of the disease has been demonstrated in a meta-analysis of untreated patients with HCC enrolled in RCTs.<sup>183</sup> In addition, an advantage of the BCLC system is that it attempts to stratify patients into treatment groups, although the type of treatment is not

included as a staging variable.<sup>163</sup> Furthermore, the BCLC staging system was shown to be very useful for predicting outcome in patients following liver transplantation or radiofrequency ablation (RFA).<sup>184,185</sup> In a multicenter cohort study of 1328 patients with HCC eligible for liver transplantation, survival benefit for liver transplantation was seen in patients with advanced liver cirrhosis and in those with intermediate tumors (BCLC stage D and stages B–C, respectively), regardless of the number and size of the lesions, provided there was no macroscopic vascular invasion and extrahepatic disease. However, treatment recommendations may vary.

A novel staging system based on a nomogram of particular clinicopathologic variables, including patient age, tumor size and margin status, postoperative blood loss, the presence of satellite lesions and vascular invasion, and serum AFP level, that was developed has been shown to perform well in predicting postoperative outcome for patients undergoing liver resection for HCC.<sup>186</sup> In addition, another study showed tumor size >2 cm, multifocal tumors, and vascular invasion to be independent predictors of poor survival in patients with early HCC following liver resection or liver transplantation.<sup>187</sup> This staging system has been retrospectively validated in a population of patients with early HCC.<sup>188</sup>

Due to the unique characteristics of HCC that vary with geographic region, many of the existing staging systems are specific to the region in which they are developed and there is no universally accepted staging system that could be used across all institutions in different countries. The BCLC and the Hong Kong Liver Cancer staging systems are amongst the most widely used. Although no particular staging system (with the exception of the Child-Pugh score and TNM staging system) is currently used in these guidelines, following an initial workup, patients are stratified into one of the following four categories:





- Potentially resectable or transplantable, operable by performance status or comorbidity
- Unresectable disease
- Liver-confined disease, inoperable by performance status, comorbidity, or with minimal or uncertain extrahepatic disease
- Metastatic disease

### Treatment Options

All patients with HCC should be carefully evaluated by an experienced multidisciplinary team for the many available treatment options. It is important to reiterate that the management of patients with HCC is complicated by the presence of underlying liver disease. Furthermore, different etiologies of HCC and their effects on the host liver may impact treatment response and outcome. These complexities make treatment decisions in patients with HCC challenging and are the reason for multidisciplinary care with the involvement of hepatologists, diagnostic radiologists, interventional radiologists, surgeons, medical oncologists and pathologists with hepatobiliary cancer expertise, thereby requiring careful coordination of care.<sup>44</sup> Given the comorbidities associated with this disease, patients need careful consideration of treatment choice given the risk of potential toxicities from treatment and potential benefits.

### Surgery

Partial hepatectomy is a potentially curative therapy for patients with a solitary tumor of any size with no evidence of gross vascular invasion.<sup>189</sup> Partial hepatectomy for well-selected patients with HCC can now be performed with low operative morbidity and mortality ( $\leq 5\%$ ).<sup>190,191</sup> Results of large retrospective studies have shown 5-year survival rates of  $>50\%$  for patients undergoing liver resection for HCC,<sup>191-193</sup> and some studies suggest that for selected patients with preserved liver function and early-stage HCC, liver resection is associated with a 5-year survival rate of

approximately 70%.<sup>193-195</sup> However, recurrence rates at 5 years following liver resection have been reported to exceed 70%.<sup>176,192</sup>

Since liver resection for patients with HCC includes removal of functional liver parenchyma in the setting of underlying liver disease, careful patient selection, based on patient characteristics as well as characteristics of the liver and the tumor(s), is essential. Assessments of patient performance status must be considered; the presence of comorbidity has been shown to be an independent predictor of perioperative mortality.<sup>196</sup> Likewise, estimates of overall liver function and the size and function of the putative FLR, as well as technical considerations related to tumor and liver anatomy, must be taken into account before a patient is determined to have potentially resectable disease. Univariate analyses from a database study including 141 patients with HCC and liver cirrhosis who underwent resection at a German hospital showed that patient age greater than 70 years ( $P < .05$ ), Clavien grade of complications ( $P < .001$ ), positive lymph vessels ( $P < .001$ ), mechanical ventilation ( $P < .001$ ), and body mass index (BMI) ( $P < .05$ ) were significantly associated with survival.<sup>197</sup>

Resection is recommended only in the setting of preserved liver function. The Child-Pugh score provides an estimate of liver function, although it has been suggested that it is more useful as a tool to rule out patients for liver resection (ie, serving as a means to identify patients with substantially decompensated liver disease).<sup>198</sup> An evaluation of the presence of significant portal hypertension is also an important part of the surgical assessment. A meta-analysis including 11 studies showed that clinically significant portal hypertension is associated with increased 3- and 5-year mortality (pooled odds ratio [OR], 2.09; 95% CI, 1.52–2.88 for 3-year mortality; pooled OR, 2.07; 95% CI, 1.51–2.84 for 5-year mortality), as well as postoperative clinical decompensation (pooled OR, 3.04; 95% CI, 2.02–4.59).<sup>199</sup> In general, evidence of optimal liver function in the setting of liver resection is characterized by a Child-Pugh class A score and absence of



portal hypertension. However, in highly selected cases, patients with a Child-Pugh class B score may be considered for limited liver resection, particularly if liver function tests are normal and clinical signs of portal hypertension are absent. Further, limited resection may be feasible in cases where portal hypertension is mild. A prospective observational study of 223 cirrhotic patients with HCC showed that, though portal hypertension was significantly associated with liver-related morbidity following resection, it was only associated with worse survival when there was biochemical evidence of liver decompensation. A multivariate analysis showed that albumin, but not portal hypertension, was significantly associated with survival following resection.<sup>200</sup>

With respect to tumor characteristics and estimates of the FLR following resection, preoperative imaging is essential for surgical planning.<sup>98</sup> CT/MRI can be used to facilitate characterization of the number and size of the HCC lesions in order to detect the presence of satellite nodules, extrahepatic metastasis, and tumor invasion of the portal vein or the hepatic veins/inferior vena cava, and to help establish the location of the tumors with respect to vascular and biliary structures.

Optimal tumor characteristics for liver resection are solitary tumors without major vascular invasion. Although no limitation on the size of the tumor is specified for liver resection, the risk of vascular invasion and dissemination increases with size.<sup>190,201</sup> However, in one study no evidence of vascular invasion was seen in approximately one-third of patients with single HCC tumors  $\geq 10$  cm.<sup>190</sup> Nevertheless, the presence of macro- or microscopic vascular invasion is a strong predictor of HCC recurrence.<sup>190,202,203</sup> The role of liver resection for patients with limited and resectable multifocal disease and/or signs of major vascular invasion is controversial, as the recurrence rates are extremely high.<sup>189,202,204</sup> A systematic review including 23 studies with 2412 patients showed that predicted 5-year OS and DFS rates for patients with multinodular disease who underwent resection were 35%

and 22%, respectively.<sup>205</sup> The authors also examined survival rates of patients with macrovascular invasion who underwent resection (29 studies with 3659 patients). The 5-year predicted OS and DFS rates were 20% and 16%, respectively. Results of a retrospective analysis showed a 5-year OS rate of 81% for selected patients with a single tumor  $\leq 5$  cm, or 3 or fewer tumors  $\leq 3$  cm undergoing liver resection.<sup>206</sup>

Another critical preoperative assessment includes evaluation of the postoperative FLR volume, which serves as an indicator of postoperative liver function. Cross-sectional imaging is used to measure the FLR and total liver volume. The ratio of future remnant/total liver volume (subtracting tumor volume) is then determined.<sup>207</sup> The panel recommends that this ratio be at least 20% in patients without cirrhosis and at least 30% to 40% in patients with chronic liver disease and a Child-Pugh A score.<sup>208,209</sup> For patients with an estimated FLR/total liver volume ratio below recommended values who are otherwise suitable candidates for liver resection, preoperative portal vein embolization (PVE) should be considered. PVE is a safe and effective procedure for redirecting blood flow toward the portion of the liver that will remain following surgery.<sup>210</sup> Hypertrophy is induced in these segments of the liver while the embolized portion of the liver undergoes atrophy.<sup>211</sup> There are some investigational methods focused on improving FLR growth, such as PVE combined with hepatic vein embolization or with arterial embolization. The estimated future liver remnant function (eFLRF), which accounts for individual differences in body surface area, can also be calculated.<sup>212</sup> A comparison of the two methods showed that the eFLRF deviated from the FLR by  $\geq 5\%$  in 32% of 116 patients enrolled.<sup>213</sup>

In one analysis, Roayaie et al categorized 8656 patients with HCC from Asia, Europe, and North America into one of four groups: 1) met standard criteria for resection and underwent resection (n = 718); 2) met standard criteria for resection but did not undergo resection (n = 144); 3) did not





meet standard criteria for resection but underwent resection ( $n = 1624$ ); and 4) did not meet standard criteria for resection and did not undergo resection ( $n = 6170$ ).<sup>214</sup> For patients who met criteria for resection (including those who did not actually undergo resection), receiving a treatment other than resection was associated with an increased risk of mortality (hazard ratio [HR], 2.07; 95% CI, 1.35–3.17;  $P < .001$ ). For patients who did not meet criteria for resection (including those who underwent resection), resection was associated with greater survival, relative to embolization (HR, 1.43; 95% CI, 1.27–1.61;  $P < .001$ ) and other treatments (eg, yttrium-90 (Y-90) radioembolization, external beam radiation therapy [EBRT], systemic therapy) (HR, 1.78; 95% CI, 1.36–2.34,  $P < .001$ ). However, survival rates for resection in these patients were worse than those for ablation (HR, 0.85; 95% CI, 0.74–0.98,  $P = .022$ ) and transplantation (HR, 0.20; 95% CI, 0.14–0.27,  $P < .001$ ). Despite the fact that these study results are powerfully influenced by selection bias, the study investigators suggest that criteria for resection could potentially be expanded, since patients who are not considered candidates for resection based on current criteria may still benefit.

### *Postoperative Adjuvant Therapy*

The phase III STORM trial examined sorafenib, an antiangiogenic agent approved for treating unresectable HCC, for use in the adjuvant setting for patients who underwent hepatic resection or ablation with curative intent. This international trial accrued 1114 patients, 62% of whom were Asian.<sup>215</sup> Patients were randomized to receive sorafenib (800 mg daily) or placebo until progression or for a maximum duration of 4 years. Treatment-emergent adverse events were high in both study groups, and sorafenib was not well tolerated at the intended study dose (median dose achieved was 578 mg daily [72.3% of the intended dose]). No significant between-group differences were observed in OS, recurrence-free survival (RFS), and time to recurrence (TTR). The panel does not recommend sorafenib as adjuvant therapy.

A study of 200 patients with microvascular invasion-HCC (MVI-HCC) found that adjuvant TACE after resection led to significantly higher OS ( $P = 0.03$ ), especially in patients with tumor diameter  $>5$  cm or multinodular tumors.<sup>216</sup> DFS was also improved in these patients. A meta-analysis of 12 studies and 2,190 patients found similar results. However, more studies are needed to validate these findings.<sup>217</sup>

Historically, postoperative prognosis for patients with HBV-related HCC has been poor. In a two-stage longitudinal study that enrolled 780 patients with HBV infection and HCC, viral load above 10,000 copies per milliliter was correlated with poor outcomes.<sup>218</sup> Adjuvant antiviral therapy in a postoperative setting may improve outcomes. In a randomized trial including 163 patients, antiviral therapy with lamivudine, adefovir, dipivoxil, or entecavir significantly decreased HCC recurrence (HR, 0.48; 95% CI, 0.32–0.70) and HCC-related death (HR, 0.26; 95% CI, 0.14–0.50), and improved liver function at 6 months after surgery ( $P = .001$ ).<sup>218</sup> In another RCT including 200 patients who received R0 resection for HBV-related HCC, adefovir improved RFS ( $P = .026$ ) and OS ( $P = .001$ ), relative to those who did not receive adefovir.<sup>219</sup> The RR of mortality with adefovir after resection was 0.42 (95% CI, 0.27–0.65;  $P < .001$ ), and results indicated that antiviral therapy may protect against late tumor recurrence (HR, 0.35; 95% CI, 0.18–0.69;  $P = .002$ ).

With the recent availability of newer potent antiviral therapies for chronic hepatitis C viral infection, similar trials are anticipated. Two meta-analyses showed that antiviral therapy for HBV or HCV after curative HCC treatment may improve outcomes including survival.<sup>220,221</sup> A recent meta-analysis including 10 studies with 1794 patients with HCV showed that sustained viral response is associated with improved OS (HR, 0.18; 95% CI, 0.11–0.29) and better RFS (HR, 0.50; 95% CI, 0.40–0.63) following resection or locoregional therapy for HCC.<sup>222</sup> There is some concern that the rising use of DAAs might increase HCC recurrence or progression



following treatment.<sup>223-225</sup> This is an area of controversy, and well-designed trials are needed to determine the mechanism through which HCC incidence increases.<sup>223,224</sup> The panel recommends that providers discuss the potential use of antiviral therapy with a hepatologist to individualize postoperative therapy.

A meta-analysis including five studies (two RCTs and three case-control studies) with 334 patients showed that I<sup>131</sup> lipiodol injected into the hepatic artery following resection may improve DFS (Peto OR, 0.47; 95% CI, 0.37–0.59) and OS (Peto OR, 0.50; 95% CI, 0.39–0.64).<sup>226</sup> However, more randomized studies with long follow-up are needed to determine the benefit of this treatment in patients with resected HCC.

Immunotherapy, or using the immune system to treat cancer, is beginning to be investigated as adjuvant HCC treatment. A systematic review of adjuvant treatment options for HCC including 14 studies (two immunotherapy studies with 277 patients) showed that immunotherapy may prevent recurrence in resected HCC.<sup>227</sup> In a Korean phase III randomized trial, the efficacy and safety of activated cytokine-induced killer cells was examined as adjuvant immunotherapy for HCC.<sup>228</sup> Patients ( $N = 230$ ) who received the adjuvant immunotherapy had greater RFS relative to patients in the control group (HR, 0.63; 95% CI, 0.43–0.94;  $P = .01$ ). Data are currently too preliminary for the panel to provide specific recommendations regarding immunotherapy treatment in an adjuvant setting.

### **Liver Transplantation**

Liver transplantation is a potentially curative therapeutic option for patients with early HCC. It is especially appealing since it removes both detectable and undetectable tumor lesions, treats underlying liver cirrhosis, and avoids surgical complications associated with a small FLR. However, there is also a risk of potential complications such as early mortality and issues related to chronic immunosuppression.<sup>229</sup> In a landmark study published in

1996, Mazzaferro et al proposed the Milan criteria (single tumors  $\leq 5$  cm in diameter or no more than three nodules  $\leq 3$  cm in diameter in patients with multiple tumors and no macrovascular invasion) for patients with unresectable HCC and cirrhosis.<sup>230</sup> The 4-year OS and RFS rates were 85% and 92%, respectively, when liver transplantation was restricted to a subgroup of patients meeting the Milan selection criteria. These results have been supported by studies in which patient selection for liver transplantation was based on these criteria.<sup>231</sup> These selection criteria were adopted by UNOS, because they identify a subgroup of patients with HCC whose liver transplantation results are similar to those who underwent liver transplantation for end-stage cirrhosis without HCC.

The UNOS criteria (radiologic evidence of a single lesion  $\geq 2$  cm and  $\leq 5$  cm in diameter, or 2–3 lesions  $\geq 1$  cm and  $\leq 3$  cm in diameter, and no evidence of macrovascular involvement or extrahepatic disease) specify that patients eligible for liver transplantation should not be candidates for liver resection.<sup>232</sup> Therefore, liver transplantation has been generally considered to be the initial treatment of choice for well selected patients with early-stage HCC and moderate-to-severe cirrhosis (ie, patients with Child-Pugh class B and C scores), with partial hepatectomy generally accepted as the best option for the first-line treatment of patients with early-stage HCC and Child-Pugh class A scores when tumor location is amenable to resection. Retrospective studies have reported similar survival rates for hepatic resection and liver transplantation in patients with early-stage HCC when accounting for the fallout while on waiting lists for transplantation.<sup>193,233-236</sup> However, there are no prospective randomized studies that have compared the effectiveness of liver resection and liver transplantation for this group of patients.

The MELD score as a measure of liver function is also used as a measure of pre-transplant mortality.<sup>150</sup> The MELD score was adopted by UNOS in 2002 to provide an estimate of risk of death within 3 months for patients on



the waiting list for cadaveric liver transplant. MELD score is also used by UNOS to assess the severity of liver disease and prioritize the allocation of the liver transplants. According to the current Organ Procurement and Transplantation Network (OPTN) policy, patients with AFP levels  $\leq 1000$  ng/mL and with T2 tumors are eligible for a standardized MELD exception.<sup>237</sup> In a retrospective analysis of data provided by UNOS of 15,906 patients undergoing first-time liver transplantation during 1997 to 2002 and 19,404 patients undergoing the procedure during 2002 to 2007, 4.6% of liver transplant recipients had HCC compared with 26% in 2002 to 2007, with most patients in the latter group receiving an “HCC MELD exception.”<sup>238</sup> From 2002 to 2007, patients with an “HCC MELD-exemption” had similar survival to patients without HCC. Important predictors of poor post-transplantation survival for patients with HCC were a MELD score of  $\geq 20$  and serum AFP level of  $\geq 455$  ng/mL,<sup>238</sup> although the reliability of the MELD score as a measure of post-transplantation mortality is controversial. Survival was also significantly lower for the subgroup of patients with HCC tumors between 3 and 5 cm.

Expansion of the Milan/UNOS criteria to provide patients who have marginally larger HCC tumors with liver transplant eligibility is an active area of debate, with exceptional cases frequently prompting analysis and revisions.<sup>176,231,239,240</sup> An expanded set of criteria including patients with a single HCC tumor  $\leq 6.5$  cm, with a maximum of 3 total tumors with no tumor larger than 4.5 cm (and cumulative tumor size  $< 8$  cm) as liver transplant candidates has been proposed by Yao et al at the University of California at San Francisco (UCSF).<sup>241,242</sup> Studies evaluating the post-transplantation survival of patients who exceed the Milan criteria but meet the UCSF criteria show wide variation in 5-year survival rates (range of 38%–93%).<sup>239-241,243-245</sup> An argument in favor of expanding the Milan/UNOS criteria includes the general recognition that many patients with HCC tumors exceeding the Milan criteria can be cured by liver transplant. Opponents of an expansion of the Milan/UNOS criteria cite the

increased risk of vascular invasion and tumor recurrence associated with larger tumors and higher HCC stage, the shortage of donor organs, and taking organs away from patients with liver failure who do not have HCC.<sup>231,239,243</sup> Some support for the former objection comes from a large retrospective analysis of the UNOS database showing significantly lower survival for the subgroup of patients with tumors between 3 and 5 cm compared with those who had smaller tumors.<sup>238</sup>

There is a risk of tumor recurrence following liver transplantation. A group from France argued that the Milan criteria may be overly restrictive and thus developed a predictive model of HCC recurrence that combines AFP value with tumor size and number.<sup>246</sup> Analyses from samples of patients from France and Italy who underwent liver transplantation showed that this AFP model predicted an increase in 5-year risk of recurrence and decreased survival.<sup>246,247</sup> The panel does not provide specific recommendations regarding whether or not AFP should be considered a transplant criterion, and this may depend on local practice. Another analysis of patients who underwent liver transplantation ( $N = 1061$ ) showed that MVI, AFP at time of transplant, and sum of the largest diameter of viable tumor plus number of viable tumors on explant were associated with HCC recurrence.<sup>248</sup>

Resection or liver transplantation can be considered for patients with Child-Pugh Class A liver function who meet UNOS criteria ([www.unos.org/](http://www.unos.org/)) and are resectable. Controversy exists over which initial strategy is preferable to treat such patients. The guidelines recommend that these patients be evaluated by a multidisciplinary team when deciding an optimal treatment approach. The OPTN has proposed imaging criteria for patients with HCC who may be candidates for transplant.<sup>131</sup> Specifically, they propose a classification system for nodules identified by well-defined imaging from contrast-enhanced CT or MRI. OPTN also provides guidance on equipment specifications and use of a standardized



# NCCN Guidelines Version 5.2021

## Hepatobiliary Cancers

protocol. While the panel does not have a recommendation regarding liver transplantation in older adults with HCC, some centers report transplant in highly selected patients older than 70 years.<sup>249,250</sup> A systematic review of 50 studies with 4,169 elderly patients and 13,158 young patients with HCC found that while old age increased the risk of mortality after resection (3.0% vs. 1.2%), the 5-year OS was only marginally lower (51% vs. 56%).<sup>251</sup>

### *Bridge Therapy*

Bridge therapy is used to decrease tumor progression and the dropout rate from the liver transplantation waiting list.<sup>252</sup> It is considered for patients who meet the transplant criteria. An analysis including 205 patients from a transplant center registry who had HCC showed that bridging locoregional therapy was associated with survival following transplant ( $P = .005$ ).<sup>253</sup> A number of studies have investigated the role of locoregional therapies as a bridge to liver transplantation in patients on a waiting list.<sup>254,255</sup> These studies included RFA/microwave ablation (MWA);<sup>256-259</sup> transarterial embolization (TAE);<sup>260,261</sup> TACE;<sup>258,262</sup> including conventional TACE<sup>258,263,264</sup> and TACE with drug-eluting beads (DEB-TACE);<sup>265</sup> selective internal radiotherapy (SIRT) or radioembolization (TARE) with Y-90 microspheres;<sup>266</sup> EBRT;<sup>267</sup> and TACE followed by EBRT,<sup>268</sup> as “bridge” therapies.

A recent meta-analysis showed that bridge therapy did not significantly impact post-transplantation mortality, survival, and recurrence rates, compared to transplant alone.<sup>269</sup> The small size and retrospective methodology of studies in this area, as well as the heterogeneous nature of the study populations, and the absence of RCTs evaluating the utility of bridge therapy for reducing the liver transplantation waiting list drop-out rate, limit the conclusions that can be drawn.<sup>269-271</sup> Nevertheless, the use of bridge therapy in this setting is increasing, and it is administered at most

NCCN Member Institutions, especially in areas where there are long wait times for a transplant.

### *Downstaging Therapy*

Downstaging therapy is used to reduce the tumor burden in selected patients with more advanced HCC (without distant metastasis) who are beyond the accepted transplant criteria with the goal of future transplant.<sup>252,272,273</sup> A meta-analysis including three studies showed that downstaging therapy was associated with increased 1- (RR, 1.11; 95% CI, 1.01–1.23) and 5-year survival (RR, 1.17; 95% CI, 1.03–1.32) post-transplant, compared to transplant alone.<sup>269</sup> Downstaging therapy did not significantly increase RFS. However, the three studies included in these analyses were heterogeneous and biased by the fact that outcomes were measured in patients who responded well to therapy. A systematic review including 13 studies with 950 patients showed that downstaging decreased tumor burden to within Milan criteria (pooled success rate of 0.48; 95% CI, 0.39–0.58), with recurrence rates after transplantation at 16% (95% CI, 0.11–0.23).<sup>274</sup> Candidates are eligible for a standardized MELD exception if, before completing locoregional therapy, they have lesions that meet one of the following: 1) one lesion >5 cm and ≤8 cm, 2) two or three lesions that meet all of the following: each lesion ≤5 cm, with at least one lesion >3 cm and a total diameter of all lesions ≤8 cm, and 3) four or five lesions each <3 cm, and a total diameter of all lesions ≤8 cm.<sup>237</sup> The UCSF criteria can be used as the current limit for consideration of downstaging and potential candidates for this therapy should be assessed by a transplant center.

Prospective studies have demonstrated that downstaging (prior to transplant) with percutaneous ethanol injection (PEI),<sup>275</sup> RFA,<sup>275,276</sup> TACE,<sup>275-279</sup> TARE with Y-90 microspheres,<sup>278</sup> and transarterial chemoinfusion<sup>280</sup> is associated with improved outcomes such as DFS and recurrence following transplant. However, such studies have used different





selection criteria for the downstaging therapy and different transplant criteria after successful downstaging. In some studies, response to locoregional therapy has been associated with good outcomes after transplantation.<sup>281-283</sup> In a phase IIb/III randomized trial, patients underwent downstaging with locoregional, surgical, or systemic therapies. Liver transplantation was then performed in one group.<sup>284</sup> The results showed that transplantation improved the 5-year tumor-free survival (77% vs. 18%) and the 5-year OS (78% vs. 31%) compared to non-transplantation. Further validation is needed to define the endpoints for successful downstaging prior to transplant.<sup>273</sup>

The NCCN Guidelines recommend that patients meeting the UNOS criteria be considered for transplantation using either cadaveric or living donation. Patients with tumor characteristics that are marginally outside of the UNOS guidelines may be considered for transplantation at select institutions. For patients with initial tumor characteristics beyond the Milan criteria who have undergone successful downstaging therapy (ie, tumor currently meeting Milan criteria), transplantation can also be considered.

### **Locoregional Therapies**

Locoregional therapies are directed toward inducing selective tumor necrosis, and are broadly classified into ablation, arterially directed therapies, and radiation therapy (RT). Tumor necrosis induced by locoregional therapy is typically estimated by the extent to which contrast uptake on dynamic CT/MRI is diminished at a specified time following the treatment when compared with pretreatment imaging findings. The absence of contrast uptake within the treated tumor is believed to be an indication of tumor necrosis. A number of factors are involved in measuring the effectiveness of locoregional therapies, and the criteria for evaluating tumor response are evolving.<sup>161,285-288</sup> A few studies have shown that the use of modified RECIST (mRECIST) is more suitable than RECIST.<sup>289,290</sup> AFP response after locoregional therapy has also been

reported to be a reliable predictor of tumor response, time to progression (TTP), PFS, and OS.<sup>291</sup>

### **Ablation**

In an ablative procedure, tumor necrosis can be induced either by thermal ablation (RFA or MWA), or cryoablation. Ablative procedures can be performed by percutaneous, laparoscopic, or open approaches. RFA and MWA have largely replaced PEI, although PEI is used in select patients.

The safety and efficacy of RFA and PEI in the treatment of Child-Pugh class A patients with early-stage HCC tumors (either a single tumor ≤5 cm or multiple tumors [up to 3 tumors] each ≤3 cm) has been compared in a number of RCTs.<sup>292-299</sup> Both RFA and PEI were associated with relatively low complication rates. RFA was shown to be superior to PEI with respect to complete response (CR) rate (65.7% vs. 36.2%, respectively;  $P = .0005$ )<sup>297</sup> and local recurrence rate (3-year local recurrence rates were 14% and 34%, respectively;  $P = .012$ ).<sup>295</sup> Local tumor progression rates were also significantly lower for RFA than for PEI (4-year local tumor progression rates were 1.7% and 11%, respectively;  $P = .003$ ).<sup>296</sup>

In addition, in two studies, patients in the RFA arm were shown to require fewer treatment sessions.<sup>293,296</sup> However, an OS benefit for RFA over PEI was demonstrated in three randomized studies performed in Asia,<sup>294-296</sup> whereas three European randomized studies failed to show a significant difference in the OS between the two treatment arms.<sup>293,297,298</sup> In an Italian randomized trial of 143 patients with HCC, the 5-year survival rates were 68% and 70%, respectively, for PEI and RFA groups; the corresponding RFS rates were 12.8% and 11.7%, respectively.<sup>298</sup> Nevertheless, independent meta-analyses of randomized trials that have compared RFA and PEI have concluded that RFA is superior to PEI with respect to OS and tumor response in patients with early-stage HCC, particularly for tumors larger than 2 cm.<sup>300-302</sup> Results of some long-term studies show



survival rates of greater than 50% at 5 years for patients with early HCC treated with RFA.<sup>303-306</sup>

The reported OS and recurrence rates vary widely across the studies for patients treated with RFA, which is most likely due to differences in the size and number of tumors and, perhaps more importantly, tumor biology and the extent of underlying liver function in the patient populations studied. In a multivariate analysis, Child-Pugh class, tumor size, and tumor number were independent predictors of survival.<sup>304-306</sup>

RFA and PEI have also been compared with resection in randomized studies. In the only randomized study that compared PEI with resection in 76 patients without cirrhosis, with one or two tumors 3 cm or smaller, PEI was equally as effective as resection.<sup>307</sup> On the other hand, studies that have compared RFA and resection have failed to provide conclusive evidence (reviewed by Weis et al<sup>299</sup>). RFA and liver resection in the treatment of patients with HCC have been compared in randomized prospective studies.<sup>308-312</sup> The results of one randomized trial showed a significant survival benefit for resection over RFA in 235 patients with small HCC conforming to the Milan criteria.<sup>309</sup> The 5-year OS rates were 54.8% and 75.6%, respectively, for the RFA group and resection. The corresponding RFS rates for the two groups were 28.7% and 51.3%, respectively. However, more patients in the resection group were lost to follow-up than the RFA group. Conversely, other randomized studies demonstrated that percutaneous local ablative therapy with RFA is as effective as resection for patients with early-stage disease (eg, small tumors).<sup>308,310-312</sup> These studies failed to show statistically significant differences in OS and DFS between the two treatment groups. In addition, in one of the studies, tumor location was an independent risk factor associated with survival.<sup>310</sup> These studies, however, were limited by the small number of patients (180 patients and 168 patients, respectively) and the lack of a non-inferiority design. Nevertheless, results from these

studies support ablation as an alternative to resection in patients with small (<3 cm), properly located tumors.

RFA has been compared to resection in some meta-analyses, which have shown that resection is generally associated with better survival outcomes than RFA<sup>313-315</sup> but is associated with more complications and morbidity from complications.<sup>313,315</sup> Subgroup analyses from one meta-analysis showed no significant differences in 1-year mortality and disease recurrence when including only studies with patients who had solitary or small tumors (>3 cm).<sup>314</sup> One meta-analysis comparing RFA to resection in recurrent HCC (including 6 retrospective comparative studies) showed that 3- and 5-year DFS rates were greater for resection, relative to RFA (OR, 2.25; 95% CI, 1.37–3.68;  $P = .001$ ; OR, 3.70; 95% CI, 1.98–6.93;  $P < .001$ , respectively).<sup>316</sup>

Subgroup analyses from some retrospective studies suggest that tumor size is a critical factor in determining the effectiveness of RFA or resection.<sup>256,257,317-319</sup> Mazzaferro et al reported findings from a prospective study of 50 consecutive patients with liver cirrhosis undergoing RFA while awaiting liver transplantation (the rate of overall complete tumor necrosis was 55% [63% for tumors ≤3 cm and 29% for tumors ≥3 cm]).<sup>257</sup> In a retrospective analysis, Vivarelli et al reported that OS and DFS were significantly higher with surgery compared to percutaneous RFA. The advantage of surgery was more evident for Child-Pugh class A patients with single tumors >3 cm in diameter, and the results were similar in 2 groups for Child-Pugh class B patients.<sup>318</sup> In another retrospective analysis of 40 Child-Pugh class A or B patients with HCC treated with percutaneous ablative procedures, the overall rate of complete necrosis was 53%, which increased to 62% when considering only the subset of tumors <3 cm treated with RFA.<sup>256</sup> In a propensity case-matched study that compared liver resection and percutaneous ablative therapies in 478 patients with Child-Pugh A cirrhosis, survival was not different between





resection and ablation for tumors that met the Milan criteria; however, resection was associated with significantly improved long-term survival for patients with single HCC tumors larger than 5 cm or multiple tumors (up to 3 tumors) larger than 3 cm.<sup>319</sup> Median survival for the resection group was 80 months and 83 months, respectively, compared to 21.5 months and 19 months, respectively, for patients treated with ablative procedures.

Some investigators consider RFA as the first-line treatment in highly selected patients with HCC tumors that are  $\leq 2$  cm in diameter in an accessible location and away from major vascular and biliary structures and adjacent organs.<sup>320,321</sup> In one study, RFA as the initial treatment in 218 patients with a single HCC lesion  $\leq 2.0$  cm induced complete necrosis in 98% of patients (214 of 218 patients).<sup>320</sup> After a median follow-up of 31 months, the sustained CR rate was 97% (212 of 218 patients). In a retrospective comparative study, Peng et al reported that percutaneous RFA was better than resection in terms of OS and RFS, especially for patients with central HCC tumors  $< 2$  cm.<sup>321</sup> The 5-year OS rates in patients with central HCC tumors were 80% for RFA compared to 62% for resection ( $P = .02$ ). The corresponding RFS rates were 67% and 40%, respectively ( $P = .033$ ).

MWA is an alternative to RFA for the treatment of patients with small or unresectable HCC.<sup>322-326</sup> So far, only two randomized trials have compared MWA with resection and RFA.<sup>322,326</sup> In the RCT that compared RFA with percutaneous microwave coagulation, no significant differences were observed between these two procedures in terms of therapeutic effects, complication rates, and the rates of residual foci of untreated disease.<sup>322</sup> In a randomized study that evaluated the efficacy of MWA and resection in the treatment of HCC conforming to Milan criteria, MWA was associated with lower DFS rates than resection with no differences in OS rates.<sup>326</sup>

Irreversible electroporation (IRE) is an emerging modality for tumor ablation.<sup>327</sup> It targets tumor tissue by delivering non-thermal high-voltage

electric pulses. By doing so, it increases permeability of the cell membrane, disrupting cellular homeostasis and triggering apoptosis. IRE has some advantages over RFA, notably the lack of “heat sink” effect and the ability to treat near vessels, bile ducts, and other critical structures.<sup>328,329</sup> However, IRE can cause cardiac arrhythmias and uncontrolled muscle contractions.<sup>330</sup> Some small studies have shown that IRE treatment for unresectable HCC is safe and feasible.<sup>331-333</sup> In a small nonrandomized trial including 30 patients with malignant liver tumors, none of the eight patients with HCC experienced a recurrence through 6-month follow-up.<sup>333</sup> Recurrences have been reported following IRE for larger tumors.<sup>330,332</sup> Larger studies are needed to determine the effectiveness of IRE for local HCC treatment.

Although inconclusive, available evidence suggests that the choice of ablative therapy for patients with early-stage HCC should be based on tumor size and location, underlying liver function, as well as available local radiologist expertise and experience. Ablative therapies are most effective for tumors  $< 3$  cm that are in an appropriate location away from other organs and major vessels/bile ducts, with the best outcomes in tumors  $< 2$  cm.

### *Arterially Directed Therapies*

Arterially directed therapy involves the selective catheter-based infusion of particles targeted to the arterial branch of the hepatic artery feeding the portion of the liver in which the tumor is located.<sup>334</sup> Arterially directed therapy is made possible by the dual blood supply to the liver; whereas the majority of the blood supply to normal liver tissue comes from the portal vein, blood flow to liver tumors is mainly from the hepatic artery.<sup>96</sup> Furthermore, HCC tumors are hypervascular resulting from increased blood flow to tumor relative to normal liver tissue. Arterially directed therapies that are currently in use include TAE, conventional TACE, DEB-TACE, and SIRT/TARE with Y-90 microspheres.



# NCCN Guidelines Version 5.2021

## Hepatobiliary Cancers

The principle of TAE is to reduce or eliminate blood flow to the tumor, resulting in tumor ischemia followed by tumor necrosis. Gelatin sponge particles, polyvinyl alcohol particles, and polyacrylamide microspheres have been used to block arterial flow. TAE has been shown to be an effective treatment option for patients with unresectable HCC.<sup>335-338</sup> In a multicenter retrospective study of 476 patients with unresectable HCC, TAE was associated with prolonged survival compared to supportive care ( $P = .0002$ ). The 1-, 2-, and 5-year survival rates were 60.2%, 39.3%, and 11.5%, respectively, for patients who underwent TAE. The corresponding survival rates were 37.3%, 17.6%, and 2%, respectively, for patients who underwent supportive care.<sup>336</sup> In a multivariate analysis, tumor size <5 cm and earlier CLIP stage were independent factors associated with a better survival. In another retrospective analysis of 322 patients undergoing TAE for the treatment of unresectable HCC in which a standardized technique (including small particles to cause terminal vessel blockade) was used, 1-, 2-, and 3-year OS rates of 66%, 46%, and 33%, respectively, were observed. The corresponding survival rates were 84%, 66%, and 51%, respectively, when only the subgroup of patients without extrahepatic spread or portal vein involvement was considered.<sup>337</sup> In multivariate analysis, tumor size 5 cm or larger, 5 or more tumors, and extrahepatic disease were identified as predictors of poor prognosis following TAE.

TACE is distinguished from TAE in that, in addition to arterial blockade, the goal is to also deliver a highly concentrated dose of chemotherapy to tumor cells, prolong the contact time between the chemotherapeutic agents and the cancer cells, and minimize systemic toxicity of chemotherapy.<sup>339</sup> The results of two RCTs and one retrospective case-control study have shown a survival benefit for TACE compared with supportive care in patients with unresectable HCC.<sup>340-342</sup> In one study that randomized patients with unresectable HCC to TACE or best supportive care, the actuarial survival was significantly better in the TACE group (1 year, 57%; 2 years, 31%; 3 years, 26%) than in the control group (1 year,

32%; 2 years, 11%; 3 years, 3%;  $P = .002$ ).<sup>340</sup> Although death from liver failure was more frequent in patients who received TACE, the liver function of the survivors was not significantly different between the two groups. In the other randomized study, which compared TAE and TACE with supportive care for patients with unresectable HCC, the 1- and 2-year survival rates were 82%; 63%, 75%, and 50%; and 63% and 27% for patients in the TACE, TAE, and supportive care arms, respectively.<sup>341</sup> The majority of the patients in the study had liver function classified as Child-Pugh class A, a performance status of 0, and a main tumor nodule size of about 5 cm. For the group of evaluable patients receiving TACE or TAE, partial response (PR) and CR rates sustained for at least 6 months were observed in 35% (14/40) and 43% (16/37), respectively. However, this study was terminated early due to an obvious benefit associated with TACE. Although this study demonstrated that TACE was significantly more effective than supportive care ( $P = .009$ ), there were insufficient patients in the TAE group to make any statement regarding its effectiveness compared to either TACE or supportive care. In a randomized trial, the effectiveness of TAE was compared to that of doxorubicin-based TACE in 101 patients with HCC.<sup>343</sup> Study investigators did not find statistically significant differences in response, PFS, and OS between the two groups. Some institutions prefer the use of bland embolization using particles without chemotherapy.<sup>343</sup>

A retrospective analysis of patients with advanced HCC who had undergone embolization in the past 10 years revealed that TACE (with doxorubicin plus mitomycin C) is significantly associated with prolonged PFS and TTP but not OS, as compared to TAE.<sup>344</sup> In a multivariable analysis, the type of embolization and CLIP score were significant predictors of PFS and TTP, whereas CLIP score and AFP were independent predictors of OS.



Many of the clinical studies evaluating the effectiveness of TAE and/or TACE in the treatment of patients with HCC are confounded by use of a wide range of treatment strategies, including type of embolic particles, type of chemotherapy and type of emulsifying agent (for studies involving TACE), and number of treatment sessions. In a randomized trial, the effectiveness of TAE was compared to that of doxorubicin-based TACE in 101 patients with HCC.<sup>343</sup> Study investigators did not find statistically significant differences in response, PFS, and OS between the two groups.

Complications common to TAE and TACE include non-target embolization, liver failure, pancreatitis, and cholecystitis. Additional complications following TACE include acute portal vein thrombosis (PVT), bone marrow suppression, and pancreatitis (very rare), although the reported frequencies of serious adverse events vary across studies.<sup>77,345</sup> Reported rates of treatment-related mortality for TAE and TACE are usually well under 5%.<sup>77,337,341,345</sup> A transient post-embolization syndrome involving fever, abdominal pain, and intestinal ileus is relatively common in patients undergoing these procedures.<sup>77,345</sup> A retrospective study from a single institution in Spain showed that PVT and liver function categorized as Child-Pugh class C were significant predictors of poor prognosis in patients treated with TACE.<sup>346</sup> However, TACE has since been shown to be safe and feasible in highly selected patients with HCC and PVT,<sup>347</sup> and results of a meta-analysis (5 prospective studies with 600 patients) showed that TACE may improve survival in these patients, compared to patients who received control treatments.<sup>348</sup> Therefore, the panel considers TACE to be safe in highly selected patients who have limited tumor invasion of the portal vein. TACE is not recommended in those with liver function characterized as Child-Pugh class C (absolute contraindication). Because TAE can increase the risk of liver failure, hepatic necrosis, and liver abscess formation in patients with biliary obstruction, the panel recommends that a total bilirubin level >3 mg/mL should be considered as a relative contraindication for TACE or TAE

unless segmental treatment can be performed. Furthermore, patients with previous biliary enteric bypass have an increased risk of intrahepatic abscess following TACE and should be considered for prolonged antibiotic coverage at the time of the procedure.<sup>349,350</sup>

TACE causes increased hypoxia leading to an up-regulation of vascular endothelial growth factor receptor (VEGFR) and insulin-like growth factor receptor 2 (IGFR-2).<sup>351</sup> Increased plasma levels of VEGFR and IGFR-2 have been associated with the development of metastasis after TACE.<sup>352,353</sup> These findings have led to the evaluation of TACE in combination with sorafenib in patients with residual or recurrent tumor not amenable to additional locoregional therapies.<sup>354-361</sup>

DEB-TACE has also been evaluated in patients with unresectable HCC.<sup>362-369</sup> A randomized study (PRECISION V) of 212 patients with localized, unresectable HCC with Child-Pugh class A or B cirrhosis and without nodal involvement, showed no difference in CR, objective response, and disease control between DEB TACE with doxorubicin-eluting embolic beads and conventional TACE with doxorubicin.<sup>364</sup> Overall, DEB-TACE was not superior to conventional TACE with doxorubicin ( $P = .11$ ) in this study. In a subgroup analysis, DEB-TACE was associated with a significant increase in objective response ( $P = .038$ ) compared to conventional TACE in patients with Child-Pugh class B, ECOG performance status 1, bilobar disease, and recurrent disease. DEB-TACE was also associated with improved tolerability with a significant reduction in serious liver toxicity and a significantly lower rate of doxorubicin-related side effects, compared to conventional TACE.<sup>364</sup> In another small prospective randomized study ( $n = 83$ ), Malagari et al also showed that DEB-TACE resulted in higher response rates, lower recurrences, and longer TTP compared to TAE in patients with intermediate-state HCC; however, this study also did not show any OS benefit for DEB-TACE.<sup>365</sup> A randomized study comparing



DEB-TACE to conventional TACE in 177 patients with intermediate stage, unresectable, persistent, or recurrent HCC revealed no significant efficacy or safety differences between the two approaches; however, DEB-TACE was associated with less post-procedural abdominal pain.<sup>369</sup> Conversely, Dhanasekaran et al reported a survival advantage for DEB-TACE over conventional TACE in a prospective randomized study of 71 patients with unresectable HCC.<sup>366</sup> However, these results are from underpowered studies and need to be confirmed in large prospective studies. The findings from a meta-analysis of 28 studies suggest that DEB-TACE led to longer OS compared to TARE and conventional TACE.<sup>370</sup> However, there were lower complications associated with TARE.

Sorafenib following arterially directed therapies may be appropriate in patients with adequate liver function once bilirubin returns to baseline, if there is evidence of residual or recurrent tumor not amenable to additional locoregional therapies.<sup>356-358</sup> Results from non-randomized phase II studies and a retrospective analysis suggest that concurrent administration of sorafenib with TACE or DEB-TACE may be a treatment option for patients with unresectable HCC.<sup>355-361,371</sup> A meta-analysis including 14 studies with 1670 patients with advanced HCC examined the efficacy and safety of TACE combined with sorafenib.<sup>372</sup> Results showed that this combination was associated with greater 1-year OS, compared to TACE alone (OR, 1.88; 95% CI, 1.39–2.53;  $P < .001$ ), but combination therapy also resulted in greater frequency of some adverse events (hand-foot skin reaction, diarrhea, hypertension, fatigue, hepatotoxicity, and rash). This meta-analysis is limited by lack of an evaluation of a longer follow-up period. One meta-analysis of 13 studies with 2,538 patients found that the combination of TACE with sorafenib improved OS in the Asian regions but not in non-Asian areas<sup>373</sup> while another did not find a difference in OS in either region but noted a longer time to disease progression in the Asian population but not the European population.<sup>374</sup> In a phase III randomized trial, sorafenib, when given following treatment

with TACE did not significantly prolong TTP or OS in patients with unresectable HCC that responded to TACE.<sup>361</sup> Another phase III trial determined that the combination of sorafenib with DEB-TACE did not improve PFS.<sup>375</sup> Currently, the panel does not recommend sorafenib following TACE, given the lack of evidence to support this treatment sequence.

TARE is a method that involves internal delivery of high-dose beta radiation to the tumor-associated capillary bed, thereby sparing the normal liver tissue.<sup>334,376</sup> TARE is accomplished through the catheter-based administration of microspheres (glass or resin microspheres) embedded with Y-90, an emitter of beta radiation. There is a growing body of literature to suggest that radioembolization might be an effective treatment option for patients with liver-limited, unresectable disease,<sup>377-382</sup> though additional RCTs are needed to determine the relative risks and benefits of TARE with Y-90 microspheres in patients with unresectable HCC and long-term impact on liver function.<sup>383</sup> Delivery of 205 Gy or greater to the tumor may be associated with increased OS.<sup>384</sup> Although radioembolization with Y-90 microspheres, like TAE and TACE, involves some level of particle-induced vascular occlusion, it has been proposed that such occlusion is more likely to be microvascular than macrovascular, and that the resulting tumor necrosis is more likely to be induced by radiation rather than ischemia.<sup>377</sup> RCTs have shown that Y-90 is not superior to sorafenib for treating advanced HCC.<sup>385,386</sup> Radioembolization may be appropriate in some patients with advanced HCC,<sup>385,386</sup> specifically patients with segmental or lobar portal vein, rather than main PVT.<sup>377</sup>

Reported complications of TARE include cholecystitis/bilirubin toxicity, gastrointestinal ulceration, radiation-induced liver disease, and abscess formation.<sup>377,379,387</sup> A PR rate of 42.2% was observed in a phase II study of 108 patients with unresectable HCC with and without PVT treated with TARE and followed for up to 6 months.<sup>377</sup> Grade 3/4 adverse events were





more common in patients with main PVT. However, patients with branch PVT experienced a similar frequency of adverse events related to elevated bilirubin levels as patients without PVT. Results from a single-center, prospective longitudinal cohort study of 291 patients with HCC treated with TARE showed a significant difference in median survival times based on liver function level (17.2 months for Child-Pugh class A patients and 7.7 months for Child-Pugh class B patients;  $P = .002$ ).<sup>379</sup> Median survival for Child-Pugh class B patients and those with PVT was 5.6 months. A meta-analysis including 17 studies with 722 patients with HCC and PVT showed that median TTP, CR rate, PR rate, stable disease (SD) rate, progressive disease rate, and OS were 5.6 months, 3.2%, 16.5%, 31.3%, 28%, and 9.7 months, respectively.<sup>388</sup> Median OS for patients with Child-Pugh Class B liver function (6.1 months) was lower than for patients with Child-Pugh Class A liver function (12.1 months), and lower for patients with main PVT (6.1 months) than for patients with branch PVT (13.4 months). Toxicities reported in these studies included fatigue (2.9%–67%), abdominal pain (2.9%–57%), and nausea/vomiting (5.7%–28%). Results from this meta-analysis suggest that TARE is safe and effective for patients with HCC who have PVT.

A multicenter study analyzed radiation segmentectomy, a selective TARE approach that limits radioembolization to two or fewer hepatic segments. This technique was evaluated in 102 patients with solitary unresectable HCC not amenable to RFA treatment due to tumor proximity to critical structures. The procedure resulted in CR, PR, and SD in 47%, 39%, and 12% of patients, respectively.<sup>382</sup>

In a meta-analysis including five studies, patients with unresectable HCC ( $N = 553$ ) treated with TACE or TARE with Y-90 microspheres had similar survival times and response rates.<sup>389</sup> However, TARE resulted in a longer TTP, less toxicity, and less post-treatment pain than TACE.<sup>389</sup> Further, TACE requires a one-day hospital stay, while TARE is usually an

outpatient procedure.<sup>389</sup> Another meta-analysis including 14 studies compared DEB-TACE to TARE with Y-90 microspheres in patients with HCC and found that DEB-TACE had a superior 1-year OS rate (79% vs. 55%, respectively; OR, 0.57; 95% CI, 0.36–0.92;  $P = .02$ ), though this difference is no longer statistically significant for 2-year and 3-year OS.<sup>390</sup> These findings need to be confirmed in large RCTs.

Two recent phase III RCTs compared the efficacy and safety of TARE with Y-90 microspheres to sorafenib in patients with locally advanced HCC.<sup>385,386</sup> In both trials, OS rates were not significantly different between the two treatment groups. However, adverse events grade 3 or higher (eg, diarrhea, fatigue, hand-foot skin reaction) were more frequent in patients randomized to receive sorafenib than in patients randomized to receive TARE.

### *Radiation Therapy*

Radiation therapy options for patients with unresectable or inoperable HCC include EBRT and stereotactic body radiation therapy (SBRT). EBRT allows focal administration of high-dose radiation to liver tumors while sparing surrounding liver tissue, thereby limiting the risk of radiation-induced liver damage in patients with unresectable or inoperable HCC.<sup>391,392</sup> Advances in EBRT, such as intensity-modulated radiation therapy (IMRT) and image-guided radiotherapy, have allowed for enhanced delivery of higher radiation doses to the tumor while sparing surrounding critical tissue. SBRT is an advanced technique of EBRT that delivers large ablative doses of radiation. There is growing evidence (primarily from non-RCTs) supporting the usefulness of SBRT for patients with unresectable, locally advanced, or recurrent HCC.<sup>393-397</sup>

In a phase II trial of 50 patients with inoperable HCC treated with SBRT after incomplete TACE, SBRT induced CRs and PRs in 38.3% of patients within 6 months of completing SBRT.<sup>396</sup> The 2-year local control rate, OS, and PFS rates were 94.6%, 68.7%, and 33.8%, respectively. In another



study that evaluated the long-term efficacy of SBRT for patients with primarily small HCC ineligible for local therapy or surgery (42 patients), SBRT induced an overall CR rate of 33%, with 1- and 3-year OS rates of 92.9% and 58.6%, respectively.<sup>393</sup> In patients with recurrent HCC treated with SBRT, tumor size, recurrent stage, and Child-Pugh were identified as independent prognostic factors for OS in multivariate analysis.<sup>395</sup> In a report from Princess Margaret Cancer Centre on 102 patients treated with SBRT for locally advanced HCC in sequential phase I and phase II trials, Bujold et al reported a 1-year local control rate of 87% and a median survival of 17 months. The majority of these patients were at high risk with relatively advanced-stage tumors (55% of patients had tumor vascular thrombosis, and 61% of patients had multiple lesions with a median sum of largest diameter of almost 10 cm and a median diameter of 7.2 cm for the largest lesion).<sup>397</sup> A retrospective analysis comparing RFA and SBRT in 224 patients with inoperable, nonmetastatic HCC showed that SBRT may be a preferred option for tumors 2 cm or larger.<sup>398</sup> However, another retrospective analysis from the National Cancer Database including 3980 patients with stage I or II HCC showed that 5-year OS was greater for patients who received RFA, compared to patients who received SBRT (30% vs. 19%,  $P < .001$ ).<sup>399</sup> SBRT has also been shown to be an effective bridging therapy for patients with HCC and cirrhosis awaiting liver transplant.<sup>400-402</sup>

Most tumors, irrespective of their location, may be amenable to SBRT, IMRT, or conformal EBRT. SBRT dosing is usually 30 to 50 Gy in 3 to 5 fractions, depending on the ability to meet normal organ constraints and underlying liver function.<sup>393,394,398,403,404</sup> Hypofractionated schedules may also be considered.<sup>405</sup> SBRT is often used for patients with 1 to 3 tumors with minimal or uncertain extrahepatic disease. There is no strict size limit, so SBRT may be used for larger lesions if there is sufficient uninvolved liver and liver radiation dose constraints can be respected. The majority of safety and efficacy data on the use of SBRT are available for patients with

HCC and Child-Pugh A liver function; limited safety data are available for the use of SBRT in patients with Child-Pugh B or poorer liver function.<sup>394,397,403,405,406</sup> Those with Child-Pugh B cirrhosis may require dose modifications and strict dose constraint adherence to increase safety in this population. The safety of SBRT for patients with Child-Pugh C cirrhosis has not been established, as there are not likely to be clinical trials available for this group of patients with a very poor prognosis.

In 2014, ASTRO (American Society for Radiation Oncology) released a model policy supporting the use of proton beam therapy (PBT) in some oncology populations.<sup>407</sup> In a phase II study, 94.8% of patients with unresectable HCC who received high-dose hypofractionated PBT demonstrated >80% local control after two years, as defined by RECIST criteria.<sup>408</sup> In a meta-analysis including 70 studies, charged particle therapy (mostly including PBT) was compared to SBRT and conventional radiotherapy.<sup>409</sup> OS (RR, 25.9; 95% CI, 1.64–408.5;  $P = .02$ ), PFS (RR, 1.86; 95% CI, 1.08–3.22;  $P = .013$ ), and locoregional control (RR, 4.30; 95% CI, 2.09–8.84;  $P < .001$ ) through 5 years were greater for charged particle therapy than for conventional radiotherapy. There were no significant differences between charged particle therapy and SBRT for these outcomes. In a comparison of PBT and IMRT, PBT was linked with higher OS (31 months vs. 14 months), which could be due to decreased occurrence of liver decompensation.<sup>410</sup> Analyses from a prospective RCT including 69 patients with HCC showed that PBT tended to be associated with improved 2-year local control ( $P = .06$ ), better PFS ( $P = .06$ ), and fewer hospitalization days following treatment ( $P < .001$ ), relative to patients who received TACE.<sup>411</sup> The panel advises that PBT may be considered and appropriate in select settings for treating HCC. Several ongoing studies are continuing to investigate the impact of hypofractionated PBT on HCC outcomes (eg, NCT02632864), including randomized trials comparing PBT to RFA (NCT02640924) and PBT to TACE (NCT00857805). Hypofractionated PBT was evaluated in a phase





II study with 45 patients with HCC.<sup>412</sup> At 3 years, the local PFS and OS were 95.2% (95% CI, 89.1%–100%) and 86.4% (95% CI, 72.9%–99.9%) respectively.

### *Combinations of Locoregional Therapies*

Results from retrospective analyses suggest that the combination of TACE with RFA is more effective (both in terms of tumor response and OS) than TACE or RFA alone or resection in patients with single or multiple tumors fulfilling the UNOS or Milan criteria<sup>206,413</sup> or in patients with single tumors up to 7 cm.<sup>414,415</sup> The principle behind the combination of RFA and embolization is that the focused heat delivery of RFA may be enhanced by vessel occlusion through embolization since blood circulation inside the tumor may interfere with the transfer of heat to the tumor.

However, randomized trials that have compared the combination of ablation and embolization with ablation or embolization alone have shown conflicting results. Combination therapy with TACE and PEI resulted in superior survival compared to TACE or PEI alone in the treatment of patients with small HCC tumors, especially for patients with HCC tumors measuring <2 cm.<sup>416,417</sup> In another randomized study, Peng et al reported that the combination of TACE and RFA was superior to RFA alone in terms of OS and RFS for patients with tumors <7 cm, although this study had several limitations (small sample size and the study did not include TACE alone as one of the treatment arms, thus making it difficult to assess the relative effectiveness of TACE alone compared to the combination of TACE and RFA).<sup>418</sup> In a prospective randomized study, Shibata et al reported that the combination of RFA and TACE was equally as effective as RFA alone for the treatment of patients with small (≤3 cm) tumors.<sup>419</sup> Conversely, results from other randomized trials indicate that the survival benefit associated with the combination approach is limited only to patients with tumors that are between 3 cm and 5 cm.<sup>420,421</sup> In the randomized prospective trial that evaluated sequential TACE and RFA

versus RFA alone in 139 patients with recurrent HCC ≤5 cm, the sequential TACE and RFA approach was better than RFA in terms of OS and RFS only for patients with tumors between 3.1 and 5.0 cm ( $P = .002$  and  $P < .001$ ) but not for those with tumors 3 cm or smaller ( $P = .478$  and  $P = .204$ ).<sup>421</sup> In a small RCT including 50 patients with an unresectable single HCC lesion (ie, larger than 4 cm, serum bilirubin >1.2 mg/dL, and/or presence of esophageal varices), patients received either TACE alone, TACE following RFA, or TACE following MWA.<sup>422</sup> Patients who received TACE alone had a greater recurrence rate one month after intervention completion, compared to patients who received TACE with RFA or MWA (30% vs. 5% vs. 0%, respectively;  $P = .027$ ). However, at 3- and 6-month follow-up, recurrence rates between the three groups were no longer statistically significant.

The results of a meta-analysis of 10 RCTs comparing the outcomes of TACE plus percutaneous ablation with those of TACE or ablation alone suggest that while there is a significant OS benefit for the combination of TACE and PEI compared to TACE alone for patients with large HCC tumors, there was no survival benefit for the combination of TACE and RFA in the treatment of small lesions as compared with that of RFA alone.<sup>423</sup>

Therefore, available evidence suggests that the combination of TACE with RFA or PEI may be effective, especially for patients with larger lesions that do not respond to either procedure alone. A meta-analysis including 25 studies with 2577 patients with unresectable HCC showed that TACE combined with RT (eg, 3D-CRT, SBRT) was associated with a complete tumor response (OR, 2.73; 95% CI, 1.95–3.81) and survival through 5 years (OR, 3.98; 95% CI, 1.89–8.50), compared with TACE delivered alone.<sup>424</sup> However, this combination was also associated with increased gastroduodenal ulcers (OR, 12.80; 95% CI, 1.57–104.33), levels of ALT



(OR, 2.46; 95% CI, 1.30–4.65), and total bilirubin (OR, 2.16; 95% CI, 1.05–4.45).

A Cochrane review including nine RCTs with 879 patients with unresectable HCC showed that EBRT combined with TACE is associated with lower 1-year mortality (RR, 0.51; 95% CI, 0.41–0.62;  $P < .001$ ) and a better response rate (CR or PR; RR, 1.58; 95% CI, 1.40–1.78;  $P < .001$ ), compared to TACE alone.<sup>425</sup> However, patients who received the combination treatment had increased toxicity compared to patients who received TACE alone, as illustrated by elevated alanine aminotransferase (RR, 1.41; 95% CI, 1.08–1.84;  $P = .01$ ) and bilirubin (RR, 2.69; 95% CI, 1.34–5.40;  $P = .005$ ). The investigators who conducted the review cautioned that the quality of evidence for these findings was low to very low. In a recent RCT, 90 patients with HCC confined to the liver and with macroscopic vascular invasion were randomized to receive first-line sorafenib or TACE combined with EBRT.<sup>426</sup> The TACE/EBRT arm had better median OS (55 weeks vs. 43 weeks, respectively;  $P = .04$ ), 12-week PFS (86.7% vs. 34.3%, respectively;  $P < .001$ ), radiologic response (33.3% vs. 2.2%, respectively;  $P < .001$ ), and median TTP (31 weeks vs. 12 weeks, respectively;  $P < .001$ ) compared to the sorafenib arm.

### *NCCN Recommendations for Locoregional Therapies*

The relative effectiveness of locoregional therapies compared to resection or liver transplantation in the treatment of patients with HCC has not been established. The consensus of the panel is that liver resection or transplantation, if feasible, is preferred for patients who meet surgical or transplant selection criteria since these are established potentially curative therapies. Locoregional therapy (eg, ablation, arterially directed therapies, EBRT/SBRT) is the preferred treatment approach for patients who are not amenable to surgery or liver transplantation.

All tumors considered for ablation should be amenable to complete treatment with a margin of normal tissue around the tumor. Tumors should

be in a location accessible for percutaneous, laparoscopic, or open approaches. Lesions abutting key structures such as the bile ducts, stomach, bowel, gallbladder, or diaphragm may be difficult locations for ablation although hydrodissection techniques can be used to safely treat in some instances. The panel emphasizes that caution should be exercised when ablating lesions near these structures to decrease complications. Similarly, ablative treatment of tumors located on the liver capsule may cause tumor rupture with track seeding, especially with direct puncture techniques. Tumor seeding along the needle track has been reported in  $<1\%$  of patients with HCC treated with RFA.<sup>427–429</sup> Lesions with subcapsular location and poor differentiation seem to be at higher risk for this complication.<sup>427</sup> During an ablation procedure, major vessels in close proximity to the tumor can absorb large amounts of heat (known as the “heat sink effect”), which can decrease the effectiveness and significantly increase local recurrence rates.

The consensus of the panel is that ablation alone may be a curative treatment for tumors  $\leq 3$  cm. In well-selected patients with small, properly located tumors ablation should be considered as definitive treatment in the context of a multidisciplinary review.<sup>308,310</sup> Tumors between 3 and 5 cm may be treated with a combination of MWA and/or arterially directed therapies to prolong survival, as long as the tumor location is favorable to ablation and underlying liver function is adequate.<sup>420,421,430</sup> The panel recommends that patients with unresectable or inoperable lesions larger than 5 cm should be considered for treatment using arterially directed therapies, EBRT, or systemic therapy.

All HCC tumors, irrespective of location in the liver, may be amenable to arterially directed therapies, provided that the arterial blood supply to the tumor can be isolated.<sup>337,341,377,414</sup> An evaluation of the arterial anatomy of the liver, patient’s performance status, and liver function is necessary prior to the initiation of arterially directed therapy. In addition, more



individualized patient selection that is specific to the particular arterially directed therapy being considered is necessary to avoid significant treatment-related toxicity. General patient selection criteria for arterially directed therapies include unresectable or inoperable tumors not amenable to ablation therapy only, and the absence of large-volume extrahepatic disease. Minimal extrahepatic disease is considered a “relative” contraindication for arterially directed therapies.

All arterially directed therapies are relatively contraindicated in patients with bilirubin >3 mg/dL unless segmental treatment can be performed. Outside of segmental therapy, TARE with Y-90 microspheres has an increased risk of radiation-induced liver disease in patients with bilirubin >2 mg/dL.<sup>379</sup> Arterially directed therapies are safe to use in patients with limited tumor invasion of the portal vein but are contraindicated in Child-Pugh Class C patients, unless the goal of therapy is to bridge the patient to transplant. It is also important to note that the contrast agent used may be nephrotoxic, and, thus, these therapies should not be used if creatinine clearance is elevated.

The panel recommends that EBRT or SBRT be considered as an alternative to ablation and/or embolization techniques when these therapies have failed or are contraindicated (in patients with unresectable disease characterized as extensive or otherwise not suitable for liver transplantation and those with local disease but who are not considered candidates for surgery due to performance status or comorbidity). Radiotherapy should be guided by imaging to improve treatment accuracy and reduce toxicity. Palliative EBRT is appropriate for symptom control and/or prevention of complications from metastatic HCC lesions in bone or brain.<sup>431</sup> The panel encourages prospective clinical trials evaluating the role of SBRT in patients with unresectable, locally advanced, or recurrent HCC.

### Systemic Therapy

The majority of patients diagnosed with HCC have advanced disease, and only a small percentage are eligible for potentially curative therapies. Furthermore, with the wide range of locoregional therapies available to treat patients with unresectable HCC confined to the liver, systemic therapy has often been a treatment of last resort for those patients with very advanced disease. Until recently, sorafenib has been the only systemic therapy option for patients with advanced disease. However, from a number of recent clinical trials, there is one new systemic therapy option for upfront treatment of advanced or unresectable HCC and a number of active agents for HCC that has progressed on or after previous systemic treatment. In the 2021 update, combined atezolizumab and bevacizumab was listed as a preferred regimen while sorafenib and lenvatinib were listed as other recommended regimens.

### Sorafenib

Sorafenib, an oral multikinase inhibitor that suppresses tumor cell proliferation and angiogenesis, was evaluated in two randomized, placebo-controlled, phase III trials for the treatment of patients with advanced or metastatic HCC.<sup>432,433</sup>

In one of these phase III trials (SHARP trial), 602 patients with advanced HCC were randomly assigned to sorafenib or best supportive care. In this study, advanced HCC was defined as patients not eligible for or those who had disease progression after surgical or locoregional therapies.<sup>432</sup> The majority of the patients had preserved liver function (≥95% of patients classified as Child-Pugh class A) and good performance status (>90% of patients had ECOG performance status of 0 or 1). Median OS was significantly longer in the sorafenib arm (10.7 months in the sorafenib arm vs. 7.9 months in the placebo group; HR, 0.69; 95% CI, 0.55–0.87;  $P < .001$ ).<sup>432</sup> In the Asia-Pacific study, another phase III trial with a similar design to the SHARP study, 226 patients were randomly assigned to



sorafenib or placebo arms (150 and 76 in sorafenib and placebo arms, respectively).<sup>433</sup> While the HR for the sorafenib arm compared with the placebo arm (HR, 0.68; CI, 0.50–0.93;  $P = .014$ ) was nearly identical to that reported for the SHARP study, the median OS was strikingly lower in both treatment and placebo groups in the Asia-Pacific study (6.5 months vs. 4.2 months).

Data on the efficacy of sorafenib in patients with C-P class B liver function are limited since only patients with preserved liver function (C-P class A) were to be included in those trials.<sup>434,435</sup> However, approximately 28% of the 137 patients enrolled in a phase 2 trial evaluating sorafenib in the treatment of HCC had C-P class B liver function.<sup>436</sup> A subgroup analysis of these patients demonstrated a median OS for patients in the C-P class B group of only 3.2 months compared to 9.5 months for those in the C-P class A group.<sup>437</sup> Other investigators have also reported lower median OS for patients with C-P class B liver function.<sup>438–442</sup> In the GIDEON registry, the safety profile of sorafenib was generally similar for C-P class A and C-P class B, although OS was shorter in the patients with C-P class B liver function.<sup>441</sup> In the final analysis of the trial, in the intent-to-treat population (3213 patients), the median OS was 13.6 months for the C-P class A group compared to 5.2 months for the C-P class B group,<sup>443</sup> however, the TTP was similar for the two groups (4.7 months and 4.4 months, respectively). These unsurprising results reflect the balance between cancer progression and worsening liver disease as competing causes of death for patients with unresectable HCC and forms the basis for the exclusion of patients with poorer liver function from these and other clinical trials.

In addition to clinical outcome, impaired liver function may impact the dosing and toxicity of sorafenib. Abou-Alfa et al found higher levels of hyperbilirubinemia, encephalopathy, and ascites in the group with C-P class B liver function, although it is difficult to separate the extent to which

treatment drug and underlying liver function contributed to these disease manifestations.<sup>437</sup> A pharmacokinetic and phase I study of sorafenib in patients with hepatic and renal dysfunction showed an association between elevated bilirubin levels and possible hepatic toxicity.<sup>444</sup> Finally, it is important to mention that sorafenib induces only rare objective volumetric tumor responses, and this has led to a search for other validated criteria to evaluate tumor response (such as RECIST<sup>289,290</sup> or EASL criteria<sup>176</sup>).<sup>434</sup>

Sorafenib combined with erlotinib for patients with advanced HCC was assessed in a phase III RCT ( $N = 720$ ).<sup>445</sup> Results showed that this combination did not significantly improve survival, relative to sorafenib delivered with a placebo. Further, disease control rate was significantly lower for patients who received the sorafenib/erlotinib combination, relative to those in the comparison group ( $P = .021$ ). Treatment duration was shorter for those receiving the sorafenib/erlotinib combination (86 vs. 123 days).

### *Lenvatinib*

Lenvatinib is an inhibitor of VEGFR, fibroblast growth factor receptor, platelet-derived growth factor receptor (PDGFR), and other growth signaling kinases. In the phase III randomized REFLECT trial, patients with unresectable HCC ( $N = 954$ ) were randomized to receive either lenvatinib or sorafenib as first-line treatment.<sup>446</sup> The trial was designed to demonstrate non-inferiority or superiority of lenvatinib; the prespecified boundary for non-inferiority was met with median OS of 13.6 months in the lenvatinib arm compared to 12.3 months for sorafenib (HR, 0.92; 95% CI, 0.79–1.06). Based on results of the REFLECT trial, the FDA approved lenvatinib in 2018 as first-line treatment of patients with unresectable HCC.

The combination of lenvatinib and pembrolizumab, an anti-PD-1 antibody, was investigated in a phase Ib study with 104 patients with unresectable





# NCCN Guidelines Version 5.2021

## Hepatobiliary Cancers

HCC.<sup>447</sup> Using mRECIST criteria, the ORR was 46.0% (95% CI, 36.0%-56.3%). The median PFS and OS were 9.3 months and 22 months respectively. This combination is under investigation in a randomized phase III trial against lenvatinib alone for the frontline treatment of unresectable or metastatic HCC (NCT03713593).

### *Atezolizumab and Bevacizumab*

Bevacizumab, a VEGF inhibitor, has modest clinical activity as a single agent or in combination with erlotinib or chemotherapy in phase II studies in patients with advanced HCC.<sup>448-452</sup> A published abstract reported that atezolizumab combined with bevacizumab showed an ORR of 34% in the first-line treatment option for patients with unresectable or metastatic HCC in a phase 1b trial.<sup>453</sup> The IMbrave150 phase III trial enrolled 501 patients with unresectable HCC and Child Pugh A liver function, with randomization to either the combination of atezolizumab and bevacizumab or sorafenib as first-line treatment. All patients were required to have an upper endoscopy within 6 months prior to enrollment due to risk of upper gastrointestinal bleeding observed in prior phase 2 studies of bevacizumab in HCC.<sup>449,454</sup> The IMbrave150 study showed that the combination of atezolizumab plus bevacizumab significantly improved outcomes compared to sorafenib, with the 12-month OS (67.2% vs. 54.6%; HR, 0.58,  $P < .001$ ) and median PFS (6.8 months vs. 4.3 months; HR, 0.59).<sup>455</sup> Analyses from an independent reviewer (using HCC RECIST criteria) comparing the atezolizumab and bevacizumab combination to sorafenib showed an ORR of 27.3% versus 11.9% (5.5% vs. 0% CR, 21.8% vs. 11.9% PR), with SD in 46.3% versus 43.4% of patients and progressive disease in 19.6% versus 24.5%. Duration of response was >6 months was estimated to be 87.6% in the atezolizumab and bevacizumab arm and 59.1% in the sorafenib arm. Updated data from a published abstract revealed a median OS of 19.2 months for patients in the atezolizumab and bevacizumab group versus 13.4 months for patients in the sorafenib group (HR, 0.66;  $P = .0009$ ).<sup>456</sup> Prior to the initiation of the

atezolizumab plus bevacizumab regimen, patients should have adequate endoscopic evaluation and management for esophageal varices within approximately 6 months prior to treatment or according to institutional practice and based on the assessment of bleeding risk.

### *Subsequent-Line Therapy if Disease Progression*

Until recently, there have been no subsequent-line systemic therapy options for patients with HCC who have disease progression on or after sorafenib. Recent advancements have produced some effective systemic therapy options for these patients. However, it should be noted that it is unclear what the benefits of these systemic therapy options are for patients who receive the atezolizumab and bevacizumab regimen as a first-line treatment option and what subsequent agents to use if the disease progresses. The first drug to get approved for HCC after sorafenib was regorafenib, an oral multi-kinase inhibitor with activity against VEGFR1-3, PDGFRB, KIT, RET, RAF-1, and other growth signaling kinases. The randomized, double-blind, placebo-controlled, international phase III RESORCE trial assessed the efficacy and safety of regorafenib in 573 patients with HCC and C-P A liver function who progressed on sorafenib and who tolerated sorafenib at a dose of 400 mg per day for at least 20 of the prior 28 days of treatment.<sup>457</sup> Compared to the placebo, regorafenib improved median OS (10.6 months vs. 7.8 months, respectively; HR, 0.63; 95% CI, 0.50–0.79;  $P < .001$ ), median PFS by mRECIST (3.1 months vs. 1.5 months; HR, 0.46; 95% CI, 0.37–0.56;  $P < .001$ ), TTP by mRECIST (3.2 months vs. 1.5 months; HR, 0.44; 95% CI, 0.36–0.55;  $P < .001$ ), objective response (11% vs. 4%;  $P = .005$ ), and disease control (65% vs. 36%;  $P < .001$ ). Adverse events were universal among patients randomized to receive regorafenib ( $n = 374$ ), with the most frequent grade 3 or 4 treatment-related events being hypertension (15%), hand-foot skin reaction (13%), fatigue (9%), and diarrhea (3%). Seven deaths that occurred were considered by the investigators to have been related to treatment with regorafenib. Based on the results of this





trial, the FDA approved regorafenib in 2017 for patients with HCC who progressed on or after sorafenib.

Cabozantinib, another oral multikinase inhibitor with potent activity against VEGFR1-3 and MET among other targets, was assessed in the phase III randomized CELESTIAL trial including 707 patients with advanced HCC who have progressed on or after sorafenib, with 7.6% of the sample having received more than one line of previous treatment.<sup>458</sup> Median OS and PFS were significantly greater in patients randomized to receive cabozantinib (10.2 months and 5.2 months, respectively), compared to patients randomized to receive a placebo (8.0 and 1.9 months, respectively) (HR, 0.76; 95% CI, 0.63–0.92;  $P = .005$  for OS; HR, 0.44; 95% CI, 0.36–0.52;  $P < .001$  for PFS) as was the ORR (4% vs. 0.4%,  $P = .009$ ). A subsequent analysis showed that the benefits of cabozantinib spanned across a range of AFP levels.<sup>459</sup> The on-treatment AFP response was higher in the cabozantinib arm, which was linked to longer OS and PFS. Cabozantinib was approved by the FDA in 2019 for patients with C-P A liver function who have disease progression on or after sorafenib.

In a phase III randomized REACH trial, the monoclonal antibody against VEGFR2, ramucirumab, was assessed as second-line therapy following sorafenib in patients with advanced HCC ( $N = 565$ ).<sup>460,461</sup> Though this regimen did not improve median OS (9.2 months vs. 7.6 months; HR, 0.87), median PFS (HR, 0.63; 95% CI, 0.52–0.75;  $P < .001$ ) and TTP (HR, 0.59; 95% CI, 0.49–0.72;  $P < .001$ ) were improved, relative to the placebo group. A subgroup analysis in patients with a baseline AFP level of  $\geq 400$  ng/mL ( $n = 250$ ) showed that the median OS and PFS were 7.8 months (HR, 0.67) and 2.7 months, respectively, for patients in the ramucirumab arm, and 4.2 months and 1.5 months, respectively, for patients in the placebo arm. Analyses of patient-focused outcomes showed that deterioration of symptoms was not significantly different in patients randomized to receive ramucirumab, compared to the placebo group.<sup>461</sup>

Based on these findings, the REACH-2 randomized phase III trial assessed the efficacy of ramucirumab in patients with HCC who had disease progression on or after sorafenib who had a baseline AFP level of  $\geq 400$  ng/mL ( $N = 292$ ).<sup>462</sup> OS and PFS were greater in patients who received ramucirumab with best supportive care, compared to patients randomized to receive a placebo with best supportive care (median OS 8.5 months vs. 7.3 months, respectively; HR, 0.71; 95% CI, 0.53–0.95;  $P = .0199$ ; median PFS 2.8 months vs. 1.6 months, respectively; HR, 0.45; 95% CI, 0.34–0.60;  $P < .0001$ ). A pooled analysis of results from REACH and REACH-2, including 542 patients with disease progression on or after sorafenib who had a baseline AFP level of  $\geq 400$  ng/mL, showed that median OS was greater for patients who received ramucirumab, compared to patients who received the placebo (8.1 months vs. 5.0 months, respectively; HR, 0.69; 95% CI, 0.57–0.84;  $P = .0002$ ).<sup>462</sup> Post hoc analyses of the REACH and REACH-2 trials revealed the importance of AFP as a prognostic factor as the AFP response was significantly higher in patients treated with ramucirumab compared to placebo ( $P < .0001$ ).<sup>463</sup> An AFP response was associated with significantly improved survival (13.6 months vs. 5.6 months; HR, 0.45;  $P < .0001$ ).<sup>463</sup>

Based on the results from the CheckMate 040 trial, the FDA gave accelerated approval for nivolumab in 2017 for patients with HCC who progressed on or after sorafenib.<sup>464</sup> These preliminary data led to the confirmatory CheckMate 459, a randomized phase III trial comparing nivolumab to sorafenib in the frontline treatment of advanced HCC.<sup>465</sup> In the published abstract by Yau et al,<sup>465</sup> the median OS with nivolumab versus sorafenib was 16.4 versus 14.7 months, respectively (HR, 0.85;  $P = .075$ ) but the ORR was 15% versus 7%. The median PFS was 3.7 months for nivolumab versus 3.8 months for sorafenib. In 2021, the FDA's Oncologic Drugs Advisory Committee voted against maintaining the accelerated approval of nivolumab as a single agent for patients with advanced HCC who were previously treated with sorafenib.<sup>466</sup> Based on



the FDA decision, the panel removed nivolumab as a subsequent-line treatment option for patients with C-P A disease. As treatment options are limited for patients with C-P B disease, the panel voted to maintain nivolumab as a subsequent-line treatment option for these patients.

Combination treatment with nivolumab and the CTLA-4 antibody ipilimumab in 148 patients with advanced HCC who were previously treated with sorafenib led to improved clinical responses.<sup>467</sup> The results showed a response rate of 32%, per RECIST version 1.1 as assessed by blinded independent central review, and a median OS of 22.8 months. The results from a long-term follow-up of at least 44 months, published in an abstract, demonstrated that durable responses were achieved and the median OS was maintained at 22.2 months.<sup>468</sup>

Pembrolizumab, a anti-PD-1 antibody, was assessed in the non-randomized, open-label, phase II KEYNOTE-224 trial, which included 104 patients with HCC who progressed on or were intolerant to sorafenib.<sup>469</sup> About 17% of patients had an objective response (all PRs except for 1 patient who had a CR), 44% had SD, and 33% had progressive disease. Median duration of response was not reached, and, at the time of publication, assessment was ongoing in 12 of the 18 responders. The safety profile was similar to that seen for this drug in other tumor types. Based on these results, the FDA granted accelerated approval for pembrolizumab for patients with HCC who were previously treated with sorafenib. However, the phase 3 KEYNOTE-240 trial comparing pembrolizumab to a placebo in second-line HCC did not meet its primary endpoints (OS and PFS) based on the rigorous statistical plan.<sup>470</sup> Updated data from the KEYNOTE-240 trial, published in an abstract, showed that the median OS with pembrolizumab versus placebo was 13.9 vs. 10.6 months, respectively (HR, 0.77) and the median PFS was 3.3 vs. 2.8 months, respectively (HR, 0.70).<sup>471</sup> Also, a clinically meaningful difference in ORR was seen favoring pembrolizumab (18.3% vs. 4.4%), and the

median duration of response on pembrolizumab was 13.9 months. Pembrolizumab has maintained its accelerated approval in patients previously treated with sorafenib.

Dostarlimab-gxly, another anti-PD-1 antibody, was assessed in an open-label phase I study with 2 cohorts.<sup>472</sup> One cohort had 103 patients with advanced or recurrent microsatellite instability-high (MSI-H)/deficient mismatch repair (dMMR) endometrial cancer and another had 106 patients with advanced or recurrent MSI-H/dMMR or POLE-hypermutated non-endometrial solid tumors (comprising mostly gastrointestinal tumors [93.4%] with 65.1% colorectal tumors). An interim analysis, published in an abstract, revealed an ORR of 41.6% (95% CI, 34.9%–48.6%), per RECIST v1.1. The ORR for the cohort with non-endometrial cancer was 38.7% (95% CI, 29.4%–48.6%). The median duration of response was not reached (median follow-up of 16.3 months for the cohort with endometrial cancer and 12.4 months for the cohort with non-endometrial cancer). The most frequent grade 3 or higher treatment-related adverse events were anemia (2.2%), elevated lipase (1.9%), elevated alanine aminotransferase (1.1%), and diarrhea (1.1%). Another published abstract demonstrated that among the cohort with non-endometrial cancer, patients with colorectal cancer had an ORR of 36.2% (95% CI, 25.0%–48.7%).<sup>473</sup> The cohort also included two patients with liver cancer. One patient had a partial response while the other had progressive disease.

### *Other Agents and Emerging Therapies*

FOLFOX4 (infusional fluorouracil, leucovorin, and oxaliplatin) was compared to doxorubicin in a phase III trial including 371 Asian patients with advanced HCC.<sup>474</sup> The primary OS endpoint was not met, but PFS was greater for FOLFOX4, relative to doxorubicin (HR, 0.62; 95% CI, 0.49–0.79;  $P < .001$ ). Subgroup analyses from this trial including patients from China ( $n = 279$ ) showed both an OS and a PFS benefit of FOLFOX4 over doxorubicin (HR, 0.74; 95% CI, 0.55–0.98;  $P = .03$  and HR, 0.55;



95% CI, 0.45–0.78;  $P < .001$ , respectively), with median OS and PFS of 5.7 and 2.4 months, respectively, for patients randomized to receive FOLFOX4, and 4.3 and 1.7 months, respectively, for patients randomized to receive doxorubicin.<sup>475</sup> Though none of the patients in this sample had a CR, 8.6% of patients who received FOLFOX4 had a PR, compared to 1.4% of patients who received doxorubicin ( $P = .006$ ). In a phase II multicenter trial including 40 patients with advanced HCC, FOLFOX4 combined with sorafenib showed a median TTP of 7.7 months, an ORR of 18%, and a median OS of 15.1 months.<sup>476</sup> Grade 3 and 4 adverse events included elevated AST (28%) and ALT (15%), diarrhea (13%), hyperbilirubinemia (10%), hand-foot syndrome (8%), and bleeding (8%).

In a phase III trial, linifanib, a VEGF and PDGF receptor inhibitor, was compared to sorafenib in patients with advanced HCC ( $N = 1035$ ).<sup>477</sup> Patients who were randomized to receive linifanib had a greater objective response rate ( $P = .018$ ), but also a greater rate of serious adverse events ( $P < .001$ ) and adverse events leading to dose reduction and drug discontinuation ( $P < .001$ ), compared to patients randomized to receive sorafenib. Overall, survival did not significantly differ between the two drugs.

An oral MET inhibitor, tivantinib, was compared to a placebo in a phase III trial including 340 patients with HCC that was previously treated with sorafenib and had high MET expression,<sup>478</sup> based on encouraging results from a randomized phase II trial.<sup>479</sup> OS did not significantly differ between patients randomized to receive tivantinib or placebo.

Data from a phase II trial have demonstrated potential activity of axitinib and tolerability for patients with intermediate/advanced Child Pugh class A disease as a second-line therapy.<sup>480</sup> In a phase III study, patients previously treated with at least one line of systemic therapy were randomized to receive apatinib or placebo.<sup>481</sup> The results, only published in an abstract, showed that compared to the placebo arm, patients treated

with apatinib had significantly improved median OS (8.7 months vs. 6.8 months; HR, 0.785; 95% CI, 0.617–0.998;  $P = .0476$ ), median PFS (4.5 months vs. 1.9 months; HR, 0.471; 95% CI, 0.369–0.601;  $P < .0001$ ), and ORR (10.7% vs. 1.5%).

For patients with advanced disease, providers may wish to consider molecular profiling to determine eligibility for clinical trials of new molecular targeted agents (ie, for agents targeting mutated versions of isocitrate dehydrogenase 1 [*IDH1*], *IDH2*, *FGF*, and *KRAS*, among others).<sup>478,482,483</sup>

### Management of Resectable Disease

Results of an RCT ( $N = 200$ ) showed that partial hepatectomy was associated with better OS and RFS, relative to combination TACE and RFA.<sup>484</sup> In a meta-analysis of 18 studies with 5986 patients comparing TACE to resection, the survival benefits were significantly higher in the hepatectomy study arm.<sup>485</sup> The consensus of the panel is that initial treatment with either partial hepatectomy or transplantation should be considered for patients with liver function characterized by a Child-Pugh class A score, lack of portal hypertension, and who fit UNOS criteria. In addition, patients must have operable disease on the basis of performance status and comorbidity.

Hepatic resection is a potentially curative treatment option and is the preferred treatment for patients with the following disease characteristics: adequate liver function (Child-Pugh class A and selected Child-Pugh class B patients without portal hypertension), solitary mass without major vascular invasion, and adequate liver remnant.<sup>486,487</sup> Ablation may be considered in patients with tumors <3 cm in diameter who are not resection candidates due to age or comorbidity.<sup>326</sup> The presence of extrahepatic metastasis is considered to be a contraindication for resection. Hepatic resection is controversial in patients with limited multifocal disease as well as those with major vascular invasion. Liver



resection in patients with major vascular invasion should only be performed in highly selected situations by experienced teams.

Transplantation should be considered for patients who meet the UNOS criteria (AFP level  $\leq 1000$  ng/mL and radiologic evidence of either a single lesion  $\geq 2$  cm and  $\leq 5$  cm in diameter, or 2–3 lesions  $\geq 1$  cm and  $\leq 3$  cm in diameter and no evidence of macrovascular involvement or extrahepatic disease) or can be downstaged to within Milan Criteria. Transplant also provides a curative intent option for patients with Child-Pugh class B and C cirrhosis who would not otherwise be surgical candidates. The guidelines have included consideration of bridge therapy as clinically indicated for patients eligible for liver transplant. Patients with tumor characteristics that are marginally outside of the UNOS guidelines may be considered for transplantation at select institutions. Additionally, transplantation can be considered for patients who have undergone successful downstaging therapy (ie, tumor currently meeting Milan criteria). If transplant is not feasible, the panel recommends hepatic resection for this group of patients.

### Surveillance

Although data on the role of surveillance in patients with resected HCC are very limited, recommendations are based on the consensus that earlier identification of disease, primary or recurrent, may facilitate patient eligibility for investigational studies or other forms of life-prolonging treatment. The panel recommends ongoing surveillance—specifically, multiphasic, high-quality, cross-sectional imaging of the chest, abdomen, and pelvis every 3 to 6 months for 2 years, then every 6 to 12 months. Multiphasic cross-sectional imaging (ie, CT or MRI) is the preferred method for surveillance following treatment because of its reliability in assessing arterial vascularity,<sup>74</sup> which is associated with increased risk of HCC recurrence following treatment.<sup>488,489</sup> Elevated AFP levels are associated with poor prognosis following treatment<sup>241,490,491</sup> and should be

measured every 3 months for 2 years, then every 6 to 12 months.

Re-evaluation according to the initial workup should be considered in the event of disease recurrence. Early imaging per local protocol can be considered.

### Management of Advanced Disease

Locoregional therapy (ablation, arterially directed therapies, or EBRT) is the preferred treatment option for selected patients with unresectable or inoperable liver-confined disease. Based on clinical experience with non-transplant candidates, the panel considers locoregional therapy to be the preferred approach for treating patients with unresectable liver-confined disease, or for those patients with localized tumors who are medically inoperable due to comorbidity. This may include older patients, particularly those with comorbidities or compromised performance status.<sup>250,492,493</sup>

Systemic therapy is also recommended for patients with advanced disease, especially for those progressing on locoregional therapies and for those with extrahepatic metastatic disease. Biopsy may be considered for histologic confirmation prior to initiation of treatment. The combination of atezolizumab plus bevacizumab is the preferred category 1 first-line systemic therapy option for patients with Child Pugh A liver function based upon significant survival improvement in the IMBrave150 trial.<sup>455</sup> Sorafenib and lenvatinib are listed as other recommended options for first-line systemic therapy. Sorafenib is recommended as a category 1 option (for selected patients with Child-Pugh class A liver function) and as a category 2A option (for selected patients with Child-Pugh class B7 liver function) with disease characterized as: unresectable (liver-confined) and extensive/not suitable for liver transplantation; local disease only in patients who are not operable due to performance status or comorbidity; or metastatic disease. The panel recommends caution when considering use of sorafenib in patients with elevated bilirubin levels.<sup>444</sup> First-line lenvatinib is also included as a category 1 option for patients with C-P





# NCCN Guidelines Version 5.2021

## Hepatobiliary Cancers

class A liver function only. Nivolumab and FOLFOX are listed as “useful in certain circumstances”. Nivolumab<sup>465</sup> is a first-line option (category 2B) for patients with Child-Pugh Class A or B liver function who are ineligible for tyrosine kinase inhibitors or other anti-angiogenic agents. FOLFOX is another first-line option, but this is a category 2B option due to the panel’s concern regarding the control arm used in this study (doxorubicin) and lack of significant survival benefit in final analysis.<sup>474</sup>

The panel now recommends several subsequent-line therapy options for disease progression following first-line systemic therapy. However, it should be noted that it is unclear what the benefits of these systemic therapy options are for patients who receive the atezolizumab and bevacizumab regimen as a first-line treatment option and what subsequent agents to use if the disease progresses. Category 1 targeted therapy options include regorafenib, cabozantinib, and ramucirumab. Regorafenib and cabozantinib are recommended only for patients with C-P A liver function, while ramucirumab is recommended only for patients with a baseline AFP level of 400 ng/mL or greater. Checkpoint inhibitors options include nivolumab monotherapy, pembrolizumab monotherapy, and combination therapy with nivolumab and ipilimumab. Combined nivolumab and ipilimumab are recommended for patients with Child-Pugh A. Pembrolizumab is a recommended treatment option for patients with or without MSI-H tumors who have not been previously treated with a checkpoint inhibitor.<sup>469,494</sup> Based on data from the negative phase III KEYNOTE-240 trial showing that pembrolizumab did not meet its primary endpoints (OS and PFS), the panel changed its recommendation of this drug from category 2A to category 2B for patients with C-P Class A liver function.<sup>470</sup> The NCCN Guidelines include combined nivolumab and ipilimumab as well as pembrolizumab as “other recommended regimens.” Nivolumab is a treatment option (category 2B, useful in certain circumstances) for patients with C-P B liver disease progression following first-line systemic therapy who have not been previously treated with a

checkpoint inhibitor.<sup>495-497</sup> Dostarlimab-gxly is a recommended treatment option (category 2B, useful in certain circumstances) for patients with MSI-H/dMMR recurrent or advanced tumors that have progressed on or following prior treatment, who have no satisfactory alternative treatment options, and who have not been previously treated with a checkpoint inhibitor.<sup>472</sup>

The relatively rapid development of these numerous treatment options has made it difficult to address the important question of sequencing them, other than for those that have been approved for use in patients with disease progression on or following sorafenib. Sorafenib may be used in patients with disease progression on or following first-line lenvatinib (C-P Class A or B7 liver function only), but there are currently no data to support the use of lenvatinib for patients with disease progression after sorafenib.

For all patients with advanced stages of HCC treated with systemic therapies, the panel recommends periodic response assessment with cross-sectional imaging of sites at risk for metastatic progression, including chest, multiphase abdomen, and pelvis. In patients with elevated AFP tumor marker at start of therapy, AFP changes on treatment have shown association with treatment response and survival.<sup>459,463,498</sup>

The panel recommends that best supportive care measures be administered to patients with unresectable or metastatic disease, alongside cancer-directed therapies.

## Biliary Tract Cancers

### Gallbladder Cancer

Gallbladder cancer is the most common biliary tract cancer. The vast majority of gallbladder cancers are adenocarcinomas.<sup>499</sup> Incidence steadily increases with age, women are more likely to be diagnosed with





gallbladder cancer than men, and incidence and mortality rates in the United States are highest among American Indian and Alaska Native men and women.<sup>500</sup> However, the incidence of gallbladder cancer has decreased in women but has gone up in the black population and those younger than 45 years of age.<sup>500,501</sup> Globally, there are pockets of increased incidence in Korea; Japan; some areas of Eastern Europe and South America, especially Bolivia, Chile, and Spain; and in women in India, Pakistan, and Ecuador.<sup>502-504</sup> Gallbladder cancer is characterized by local and vascular invasion, extensive regional lymph node metastasis, and distant metastases. Gallbladder cancer is also associated with shorter median survival duration, a much shorter TTR, and shorter survival duration after recurrence than hilar cholangiocarcinoma.<sup>505</sup>

### **Risk Factors**

Cholelithiasis with the presence of chronic inflammation is the most prevalent risk factor for gallbladder cancer, and the risk increases with stone size.<sup>506,507</sup> Calcification of the gallbladder wall (porcelain gallbladder), a result of chronic inflammation of the gallbladder, has also been regarded as a risk factor for gallbladder cancer, with historical estimates of cancer in up to 22% of gallbladders with calcification.<sup>506</sup> More recent reports, however, suggest that the risk of developing gallbladder cancer in patients with gallbladder calcification is lower than anticipated, with gallbladder cancer being present in 7% to 15% of these patients.<sup>508-510</sup> Other risk factors include anomalous pancreaticobiliary duct junction, gallbladder polyps (>1 cm), chronic typhoid infection, primary sclerosing cholangitis, and inflammatory bowel disease.<sup>507,511-513</sup> Adenomyomatosis of the gallbladder is also a potential, albeit somewhat controversial, risk factor. Prophylactic cholecystectomy is probably beneficial for patients who are at high risk of developing gallbladder cancer (eg, porcelain gallbladder, polyps > 1 cm).<sup>506</sup> Patients with a history of chronic cholecystitis or pancreaticobiliary maljunction have a greater prevalence of gallbladder cancers that are microsatellite instability-high,<sup>514</sup> and

HER2/neu overexpression has been found in 13% of gallbladder cancer cases.<sup>515</sup>

### **Staging and Prognosis**

In the AJCC staging system, gallbladder cancer is classified into four stages based on the depth of invasion into the gallbladder wall and the extent of spread to surrounding organs and lymph nodes. In the revised 8<sup>th</sup> edition of the AJCC staging system, T2 gallbladder carcinoma was divided into two groups: tumors on the peritoneal side (T2a) and tumors on the hepatic side (T2b).<sup>165</sup> This revision is supported by two retrospective studies showing that gallbladder tumors located on the hepatic side is associated with worse prognosis, compared to tumors located on the peritoneal side.<sup>516,517</sup> However, it is important to note that it can be difficult to determine the location of the tumor, and gallbladder cancer can spread beyond the visible tumor, contributing to difficulty in predicting tumor location. Regional lymph node involvement is now staged according to number of positive nodes, as opposed to staging based on anatomic location of involved lymph nodes.

Tumor stage is the strongest prognostic factor for patients with gallbladder cancer.<sup>518,519</sup> Results from a retrospective analysis of 435 patients treated at a single center showed a median OS of 10.3 months for the entire cohort of patients.<sup>519</sup> The median survival was 12.9 months and 5.8 months for those presenting with stage IA–III and stage IV disease, respectively. It is important to note, however, that this retrospective analysis did not control well for treatment-related variables.<sup>520</sup>

### **Diagnosis**

Gallbladder cancer is often diagnosed at an advanced stage because it is often asymptomatic in its early stages and has an aggressive nature that can spread rapidly. Another factor contributing to late diagnosis of gallbladder cancer is a clinical presentation that mimics that of biliary colic or chronic cholecystitis. Hence, it is common for a diagnosis of gallbladder



cancer to be an incidental finding at cholecystectomy for presumed benign gallbladder disease or, more frequently, on pathologic review following cholecystectomy for symptomatic cholelithiasis. In a retrospective review of 435 patients diagnosed and treated with curative resection at a single center during the period of 1995 to 2005, 123 patients (47%) were diagnosed with gallbladder cancer as an incidental finding after laparoscopic cholecystectomy.<sup>519</sup> Other possible clinical presentations of gallbladder cancer include a suspicious mass detected on US or biliary tract obstruction with jaundice or chronic right upper quadrant abdominal pain. The presence of jaundice in patients with gallbladder cancer is associated with a poor prognosis; patients with jaundice are more likely to have advanced-stage disease (96% vs. 60%;  $P < .001$ ) and significantly lower disease-specific survival (6 months vs. 16 months;  $P < .0001$ ) than those without jaundice.<sup>521</sup> In a sample of 82 patients with gallbladder cancer who presented with jaundice, the resectability rate was low (7%), with even fewer having negative surgical margins (5%) and no disease-free survivors at 2 years.<sup>521</sup>

### Workup

The initial workup of patients presenting with a gallbladder mass or disease suspicious for gallbladder cancer should include liver function tests and an assessment of hepatic reserve. High-quality contrast-enhanced cross-sectional imaging (CT and/or MRI) of the chest, abdomen, and pelvis is recommended to evaluate tumor penetration through the wall of the gallbladder and the presence of nodal and distant metastases, and to detect the extent of direct tumor invasion of other organs/biliary system or major vascular invasion.<sup>522</sup> CT is more useful than US for the detection of lymph node involvement, adjacent organ invasion, and distant metastasis; MRI may be useful for distinguishing benign conditions from gallbladder cancer.<sup>499</sup> However, both techniques were unreliable in the detection of lymph node metastases that were smaller than 10 mm.<sup>523</sup> Although the role of PET scan has not been established in

the evaluation of patients with gallbladder cancer, emerging evidence from retrospective studies indicates that it may be useful for the detection of radiologically occult regional lymph node and distant metastatic disease in patients with otherwise potentially resectable disease.<sup>524,525,526,527</sup> However, false positives related to an inflamed gallbladder are problematic.

For patients presenting with jaundice, additional workup should include cholangiography to evaluate for hepatic and biliary invasion of tumor. Noninvasive magnetic resonance cholangiography (MRCP) is preferred over endoscopic retrograde cholangiopancreatography (ERCP) or percutaneous transhepatic cholangiography (PTC), unless a therapeutic intervention is planned.<sup>522</sup>

CEA and CA 19-9 testing could be considered as part of initial workup (in conjunction with imaging studies). Elevated serum CEA levels ( $>4.0$  ng/mL) or CA 19-9 levels ( $>20.0$  units/mL) could be suggestive of gallbladder cancer.<sup>528</sup> While CA 19-9 tends to have higher specificity (92.7% vs. 79.2% for CEA), its sensitivity tends to be lower (50% vs. 79.4% for CEA). However, these markers are not specific for gallbladder cancer and CA 19-9 could also be elevated in patients with jaundice from other causes. Therefore, the panel recommends carrying out these tests as part of a baseline assessment, and not for diagnostic purposes.

### Surgical Management

The surgical approach for the management of all patients with resectable gallbladder cancer is the same, with the exception that in patients with an incidental finding of gallbladder cancer on pathologic review, the gallbladder has been removed. Complete resection with negative margins remains the only potentially curative treatment for patients with gallbladder cancer.<sup>529</sup> The optimal resection consists of cholecystectomy with a limited hepatic resection (typically segments IVB and V) and portal lymphadenectomy to encompass the tumor with negative margins.<sup>530</sup>



Lymphadenectomy should include lymph nodes in the porta hepatis, gastrohepatic ligament, and retroduodenal regions without routine resection of the bile duct. Extended hepatic resections (beyond segments IV B and V) and resection of the bile duct may be necessary in some patients to obtain negative margins, depending on the stage and location of the tumor, depth of tumor invasion, proximity to adjacent organs, and expertise of the surgeon.

A simple cholecystectomy is an adequate treatment for patients with T1a tumors, with the long-term survival rate approaching 100%.<sup>531</sup>

Cholecystectomy combined with hepatic resection and lymphadenectomy is associated with an improved survival for patients with T2 or higher tumors. There is some controversy regarding the benefit of radical resection over simple cholecystectomy for patients with T1b tumors, and there is some risk of finding residual nodal or hepatic disease when re-resecting these patients.<sup>532-537</sup> Some studies have demonstrated an associated improvement in cancer-specific survival for patients with T1b and T2 tumors and no improvement in survival for patients with T3 tumors.<sup>533-535</sup> Other reports suggest that survival benefit associated with extended resection and lymphadenectomy is seen only in patients with T2 tumors and some T3 tumors with localized hepatic invasion and limited regional node involvement.<sup>536,537</sup> One meta-analysis noted that regional lymphadenectomy was associated with prolonged survival in patients with T1b, T2, and T3 tumors.<sup>538</sup>

Empiric major hepatic resection and bile duct resection have been shown to increase morbidity without any demonstrable difference in survival.<sup>530,539</sup> Bile duct resection was also not associated with a higher lymph node yield.<sup>540</sup> A retrospective analysis of prospective data collected on 104 patients undergoing surgery for gallbladder cancer from 1990 to 2002 showed that in a multivariate analysis, higher T and N stage, poor differentiation, and common bile duct involvement were independent

predictors of poor disease-specific survival.<sup>539</sup> Major hepatectomy and common bile duct excision significantly increased overall perioperative morbidity (53%) and were not independently associated with long-term survival.<sup>539</sup> Fuks et al from the AFS-GBC-2009 study group also reported that bile duct resection resulted in a postoperative morbidity rate of 60% in patients with an incidental finding of gallbladder cancer.<sup>530</sup> However, for these patients, it has been suggested that common duct resection should be performed at the time of re-resection for those with positive cystic duct margins due to the presence of residual disease.<sup>541</sup> However, occasionally the cystic duct stump can be re-resected to a negative margin.

With these data in mind, the guidelines recommend that extended hepatic resections (beyond segments IV B and V) should be performed only when necessary to obtain negative margins (R0 resection) in well-selected clinical situations as discussed above.<sup>533,535-537</sup> Bile duct excision should only be performed in the presence of adherent nodal disease and/or locally invasive disease or to obtain a negative cystic duct margin if necessary.<sup>539</sup>

Among patients with an incidental finding of gallbladder cancer, there is some evidence that a delayed resection due to referral to a tertiary cancer center or a radical resection following an initial noncurative procedure is not associated with a survival deficit compared with immediate resection.<sup>542,543</sup> However, these comparisons are difficult to interpret due to selection bias. Nevertheless, in all patients with a convincing clinical evidence of gallbladder cancer, the guidelines recommend that surgery should be performed by an experienced surgeon who is prepared to do a definitive resection of the tumor. If expertise is unavailable, patients should be referred to a center with available expertise. The panel is also of the opinion that surgery should not be performed in situations where the extent and resectability of the disease has not been established with good quality imaging. Consultation with a pathologist with expertise in the



hepatobiliary region should be considered, and careful review of the pathology report for T stage, cystic duct margin status, and other margins following surgery is crucial. If an imaging study shows a suspicious gallbladder mass, then the patient should be referred to an experienced center where they may be considered for upfront definitive resection.

### **Management of Resectable Disease**

All patients should undergo cross-sectional imaging (CT and/or MRI) of the chest, abdomen, and pelvis prior to surgery to evaluate local extent of disease and the presence of distant metastases. Staging laparoscopy has been shown to identify radiographically occult disseminated disease in patients with primary gallbladder cancer.<sup>544</sup> In a prospective study that evaluated the role of staging laparoscopy in 409 patients diagnosed with primary gallbladder cancer, Agarwal et al reported a significantly higher yield in locally advanced tumors compared with early-stage tumors (25.2% vs. 10.7%;  $P = .02$ ); the accuracy for detecting unresectable disease and a detectable lesion in locally advanced tumors (56.0% and 94.1%, respectively) was similar to that in early-stage tumors (54.6% and 100%, respectively).<sup>544</sup> In this study, the use of staging laparoscopy obviated the need for laparotomy in 55.9% of patients with unresectable disease. Staging laparoscopy, however, is of relatively low yield in patients with incidental finding of gallbladder cancer, since disseminated disease is relatively uncommon, and the patients have already had an assessment of their peritoneal cavity at the time of cholecystectomy.<sup>545</sup> Higher yields may be obtained in patients who are at higher risk for disseminated metastases (those with poorly differentiated, T3 or higher tumors or margin-positive tumors at cholecystectomy).<sup>545</sup>

In patients with a suspicious gallbladder mass, a definitive resection with cholecystectomy and en bloc hepatic resection and lymphadenectomy is recommended. In cases where there is a gallbladder mass but the diagnosis is unclear, intraoperative staging and consideration of

intraoperative photography prior to definitive resection should be considered. In selected cases, a frozen section biopsy of the gallbladder can be considered. In any case of gallbladder cancer, frozen section of suspicious distant lymph node (ie, celiac, retropancreatic, aortocaval) should also be obtained. Contraindications for resection include tumors with distant lymph node metastases beyond the porta hepatis (most commonly the celiac axis or aortocaval groove [retropancreatic]) or distant metastatic disease (ie, most commonly liver and peritoneal cavity). Additionally, some tumors are unresectable based on local invasion of the porta hepatis and its vascular and biliary structures.

Among patients with an incidental finding of gallbladder cancer on pathologic review, those with T1a lesions may be observed if the tumor margins are negative since these tumors have not penetrated the muscle layer and long-term survival approaches 100% with simple cholecystectomy.<sup>531</sup> In a sample of 122 patients with gallbladder cancer diagnosed incidentally, identified in a prospectively maintained database, liver involvement at re-resection (after cholecystectomy) was associated with decreased RFS and disease-specific survival for patients with T2 tumors (median RFS was 12 months vs. not reached for patients without liver involvement,  $P = .004$ ; median was 25 months vs. not reached for patients without liver involvement,  $P = .003$ ) but not in patients with T1b tumors.<sup>520</sup>

As mentioned above, hepatic resection and lymphadenectomy with or without bile duct excision is recommended for patients with T1b or greater lesions.<sup>533,535,536</sup> Re-resection to achieve negative margins is recommended for these patients with incidental gallbladder cancer since a significant percentage of these patients have been found to harbor residual disease within the liver and common bile duct.<sup>519,541</sup> Furthermore, although randomized trials are lacking, re-resection is generally associated with improved OS compared to cholecystectomy alone. Port





site disease is associated with disseminated peritoneal metastases, and prophylactic port site resection is not associated with improved survival or disease recurrence in patients with incidental findings of gallbladder cancer and, thus, should not be considered during definitive resection.<sup>546,547</sup>

For patients with a suspicious mass detected on imaging, the guidelines recommend cholecystectomy plus en bloc hepatic resection, and lymphadenectomy, with or without bile duct excision. A biopsy is not necessary in most cases and a diagnostic laparoscopy is recommended prior to definitive resection.<sup>544</sup> In selected patients where the diagnosis is not clear it may be reasonable to perform a cholecystectomy (including intraoperative frozen section) followed by the definitive resection during the same setting if pathology confirms cancer. Jaundice in patients with gallbladder cancer is considered a relative contraindication to surgery, and outcomes are generally poor in these patients; only a rare group of patients with localized node-negative disease potentially benefit from complete resection.<sup>521,548-550</sup> In patients with jaundice, if gallbladder cancer is suspected, surgery should only be performed if a complete resection is feasible. These patients should be carefully evaluated prior to surgery and referral to an experienced center should be considered. The guidelines recommend consideration of preoperative biliary drainage for patients with jaundice. However, caution should be exercised in patients with biliary obstruction as drainage is not always feasible and can be dangerous. Decisions regarding biliary drainage should be made by a multidisciplinary team.

Although there are no definitive data, the panel recommends consideration of a course of neoadjuvant chemotherapy for patients with jaundice. Gallbladder cancer that is locally advanced or has lymph node involvement is associated with a poor prognosis, but neoadjuvant chemotherapy may allow the oncologist to evaluate the biology of the

tumor and identify patients who are most likely to benefit from surgical intervention. A systematic review of eight studies found that only a third of the 474 patients achieved a R0 resection with the use of neoadjuvant chemotherapy or chemoradiotherapy.<sup>551</sup> In a retrospective analysis of 74 patients with locally advanced or lymph node-positive disease who received systemic therapy, 30% of patients underwent resection.<sup>552</sup> Out of the 22 patients who underwent resection, 45% underwent definitive resection, with OS being significantly greater for patients who underwent definitive resection compared to those who did not (51 months vs. 11 months, respectively;  $P = .003$ ).

In patients for whom there is evidence of locoregionally advanced disease (ie, nodal disease or evidence of other high-risk disease), neoadjuvant chemotherapy should be considered. Though clinical trials are needed to assess the efficacy of specific regimens and this concept, the following regimens may be used for gallbladder cancer in the neoadjuvant setting: gemcitabine/cisplatin, gemcitabine/oxaliplatin, gemcitabine/capecitabine, capecitabine/oxaliplatin, 5-fluorouracil (5-FU)/oxaliplatin, gemcitabine, capecitabine, and 5-FU. The panel currently does not recommend neoadjuvant chemoradiation for these patients, though a prospective study including 28 patients with locally advanced gallbladder cancer showed that an R0 resection was achieved in 14 patients, with good local control (93%) and 5-year survival (47%), following treatment with gemcitabine with concurrent RT.<sup>553</sup>

Fluoropyrimidine chemoradiation and fluoropyrimidine or gemcitabine chemotherapy are options for adjuvant treatment. See the section on *Adjuvant Chemotherapy and Chemoradiation for Biliary Tract Cancers*.

### **Management of Unresectable or Metastatic Disease**

Preoperative evaluation and a biopsy to confirm the diagnosis is recommended for patients with unresectable (includes tumors with distant lymph node metastases in the celiac axis or aortocaval groove) or





metastatic disease (includes distant metastases, nodal metastases beyond the porta hepatis, and extensive involvement of the porta hepatis causing jaundice or vascular encasement). MSI, mismatch repair (MMR), and tumor mutational burden (TMB) (defined as  $\geq 10$  mutations/megabase),<sup>554</sup> testing should be performed on biopsied tumor tissue, as cancers with MSI-H, dMMR, and TMB-high (TMB-H) may benefit from programmed death receptor-1 (PD-1) blockade such as pembrolizumab.<sup>494,555,556</sup> Primary options for these patients include: 1) clinical trial; 2) systemic therapy; 3) best supportive care. In addition, palliative RT is included as an option for patients with unresectable disease. See sections on *Chemotherapy* and *Chemoradiation and Radiation Therapy for Treatment for Advanced Biliary Tract Cancers*.

In patients with unresectable or metastatic gallbladder cancer and jaundice, biliary drainage is an appropriate palliative procedure and should be done before instituting chemotherapy if technically feasible.<sup>548</sup> However, caution should be exercised in patients with biliary obstruction as drainage is not always feasible and can be dangerous. Decisions regarding biliary drainage should be made by a multidisciplinary team. Biliary drainage followed by chemotherapy can result in improved quality of life. CA 19-9 testing can be considered after biliary decompression.

### Surveillance

There are no data to support a specific surveillance schedule or tests following resection of gallbladder cancer; determination of appropriate follow-up schedule/imaging should include a careful patient/physician discussion. It is recommended that follow-up of patients undergoing an extended cholecystectomy for gallbladder cancer should include consideration of imaging studies every 6 months for 2 years, then annually up to 5 years or as clinically indicated. Assessment of CEA and CA 19-9 may also be considered as clinically indicated. Re-evaluation according to

the initial workup should be considered in the event of disease relapse or progression.

### Cholangiocarcinomas

Cholangiocarcinomas encompass all tumors originating in the epithelium of the bile duct. More than 90% of cholangiocarcinomas are adenocarcinomas and are broadly divided into three histologic types based on their growth patterns: mass-forming, periductal-infiltrating, and intraductal-growing.<sup>557</sup> Cholangiocarcinomas are diagnosed throughout the biliary tree and are typically classified as either intrahepatic or extrahepatic cholangiocarcinoma. Extrahepatic cholangiocarcinomas are more common than intrahepatic cholangiocarcinomas. Analyses of SEER data from 1973 to 2012 showed that incidence of intrahepatic cholangiocarcinoma increased dramatically, while incidence of extrahepatic cholangiocarcinoma increased at a slower rate.<sup>558,559</sup> The increase in incidence of intrahepatic cholangiocarcinoma may have been due to an improvement in the ability to accurately diagnose intrahepatic cholangiocarcinoma, such as with imaging, molecular diagnostics, and pathology.<sup>558</sup> These cancers might have previously been diagnosed as cancers of unknown primary, in which incidence decreased from 1973 to 2012 [annual percentage change (APC), -1.87%].<sup>558</sup> Five-year OS rates for cholangiocarcinoma improved from 1973 to 2008, likely due to improvements in treatment for this disease.<sup>559</sup>

Intrahepatic cholangiocarcinomas are located within the hepatic parenchyma and have also been called “peripheral cholangiocarcinomas” (Figure 1). Extrahepatic cholangiocarcinomas occur anywhere within the extrahepatic bile duct—from the junction of the right and left hepatic ducts to the common bile duct, including the intrapancreatic portion (Figure 1)—and are further classified into hilar or distal tumors. Hilar cholangiocarcinomas (also called Klatskin tumors) occur at or near the junction of the right and left hepatic ducts; distal cholangiocarcinomas are



extrahepatic lesions arising in the extrahepatic bile ducts above the ampulla of Vater and below the confluence of the left and right bile ducts.<sup>560</sup> Hilar cholangiocarcinomas are the most common type of extrahepatic cholangiocarcinomas.

The NCCN Guidelines discuss the clinical management of patients with intra- and extrahepatic cholangiocarcinomas including hilar cholangiocarcinoma and the distal bile duct tumors. Tumors of the ampulla of Vater are not included in the NCCN Guidelines for Hepatobiliary Cancers.

### **Risk Factors**

No predisposing factors are identified in most patients diagnosed with cholangiocarcinoma,<sup>561</sup> although there is evidence that particular risk factors may be associated with the disease in some patients. These risk factors, like those for gallbladder cancer, are associated with the presence of chronic inflammation. Primary sclerosing cholangitis, chronic calculi of the bile duct (hepatolithiasis), choledochal cysts, and liver fluke infections are well-established risk factors for cholangiocarcinoma. Unlike gallbladder cancer, however, cholelithiasis is not thought to be linked with cholangiocarcinoma.<sup>562</sup> Inflammatory bowel disease may also be a risk factor for cholangiocarcinoma, though this association may be confounded by primary sclerosing cholangitis.<sup>563</sup> Other risk factors for intrahepatic cholangiocarcinoma have been found to include HBV infection, cirrhosis, diabetes, obesity, alcohol, and tobacco.<sup>564</sup> A systematic review and meta-analysis reported that the strongest risk factors for both intrahepatic and extrahepatic cholangiocarcinoma included biliary cysts and stones, cirrhosis, HBV, and HCV.<sup>565</sup> This may be responsible for the increased incidence of intrahepatic cholangiocarcinoma observed at some centers, although future studies are needed to further explore this putative association.<sup>566</sup> A recent systematic review including seven case-control studies (9102 patients and 129,111 controls) showed that NAFLD is

associated with increased incidence of both intrahepatic (pooled adjusted OR, 2.09; 95% CI, 1.49–2.91) and extrahepatic cholangiocarcinoma (pooled adjusted OR, 2.05; 95% CI, 1.59–2.64).<sup>567</sup>

### **Staging and Prognosis**

#### *Intrahepatic Cholangiocarcinoma*

In the 6<sup>th</sup> edition of the AJCC staging system, intrahepatic cholangiocarcinoma was staged identically to HCC. However, this staging system did not include predictive clinicopathologic features (multiple hepatic tumors, regional nodal involvement, and large tumor size) that are specific to intrahepatic cholangiocarcinoma.<sup>568</sup> In some reports, tumor size had no effect on survival in patients undergoing complete resection.<sup>569,570</sup> In a SEER database analysis of 598 patients with intrahepatic cholangiocarcinoma who had undergone surgery, Nathan et al reported that multiple lesions and vascular invasion predicted adverse prognosis following resection; lymph node status was of prognostic significance among patients without distant metastases.<sup>569</sup> In this study, tumor size had no independent effect on survival. These findings were confirmed in a subsequent multi-institutional international study of 449 patients undergoing surgery for intrahepatic cholangiocarcinoma.<sup>570</sup> The 5-year survival rate was higher for patients who lacked all three risk factors (multiple tumors, vascular invasion, and N1 disease) than for those with one or more risk factors (38.3%, 27.3%, and 18.1%, respectively) and, more importantly, tumor number and vascular invasion were of prognostic significance only in patients with N0 disease. Although tumor size was associated with survival in the univariate analysis, it was not of prognostic significance in a multivariate analysis.

In the revised 7<sup>th</sup> edition of the AJCC staging system, intrahepatic cholangiocarcinoma had a new staging classification that was independent of the staging classification used for HCC.<sup>571</sup> This classification focused on



multiple tumors, vascular invasion, and lymph node metastasis. Farges et al from the AFC-IHCC study group validated this staging classification in 163 patients with resectable intrahepatic cholangiocarcinoma.<sup>572</sup> The revised classification was useful in predicting survival according to the TNM staging. With a median follow-up of 34 months, the median survival was not reached for patients with stage I disease, was 53 months for those with stage II disease ( $P = .01$ ), and was 16 months for those with stage III disease ( $P < .0001$ ).

In the revised 8<sup>th</sup> edition of the AJCC staging system, T1 disease (ie, solitary tumor without vascular invasion) should now be staged according to tumor size (ie, T1a refers to a tumor that is  $\leq 5$  cm, while T1b refers to a tumor that is  $> 5$  cm).<sup>165</sup> T2 disease, on the other hand, is no longer divided into T2a (solitary tumor with vascular invasion) and T2b (multiple tumors with or without vascular invasion) disease.

### *Extrahepatic Cholangiocarcinoma*

The 7<sup>th</sup> edition of AJCC staging system included a separate TNM classification for hilar and distal extrahepatic cholangiocarcinoma, based on the extent of liver involvement and distant metastatic disease.<sup>571</sup> In the revised 8<sup>th</sup> edition of the AJCC staging system, regional lymph node involvement is now staged according to number of positive nodes.<sup>165</sup> Depth of tumor invasion is as an independent predictor of outcome in patients with distal as well as hilar cholangiocarcinomas.<sup>573,574</sup> In the revised 8<sup>th</sup> edition of the AJCC staging system for cancer of the distal bile duct, depth of tumor invasion has been added to the categorization of T1, T2, and T3 tumors.<sup>165</sup>

The modified Bismuth-Corlette staging system<sup>575</sup> and the Blumgart staging system<sup>576</sup> are used for the classification of hilar cholangiocarcinomas. The modified Bismuth-Corlette staging system classifies hilar cholangiocarcinomas into four types based on the extent of biliary involvement. However, this does not include other clinicopathologic

features such as vascular encasement, lymph node involvement, distant metastases, and liver atrophy. In addition, both the AJCC and the Bismuth-Corlette staging systems are not useful for predicting resectability or survival. The Blumgart staging system is a useful preoperative staging system that predicts resectability, likelihood of metastatic disease, and survival.<sup>576,577</sup> In this staging system, hilar cholangiocarcinomas are classified into three stages (T1–T3) based on the location and extent of bile duct involvement, the presence or absence of portal venous invasion, and hepatic lobar atrophy.<sup>576</sup> Negative histologic margins, concomitant partial hepatectomy, and well-differentiated tumor histology were associated with improved outcome after resection; increasing T-stage significantly correlated with reduced R0 resection rate, distant metastatic disease, and lower median survival.<sup>577</sup>

### **Diagnosis**

Early-stage cholangiocarcinoma may only manifest as mild changes in serum liver function tests. Patients with intrahepatic cholangiocarcinoma, due to their often late presentation, are more likely to present with nonspecific symptoms such as fever, weight loss, and/or abdominal pain; symptoms of biliary obstruction are uncommon because these tumors do not necessarily involve the common hepatic/bile duct. Intrahepatic cholangiocarcinoma may be detected incidentally as an isolated intrahepatic mass on imaging.<sup>98</sup> In contrast, patients with extrahepatic cholangiocarcinoma are likely to present with jaundice followed by evidence of a biliary obstruction or abnormality on subsequent imaging.

### **Workup**

The initial workup should include liver function tests. CEA and CA 19-9 testing can be considered for baseline assessment, although these markers are not specific for cholangiocarcinoma; they are also associated with other malignancies and benign conditions.<sup>578</sup> CA 19-9 may be falsely elevated due to jaundice.<sup>579</sup> Viral hepatitis serologies should be



considered for intrahepatic cholangiocarcinoma. If hepatitis is diagnosed, it needs to be monitored and managed following ASCO's guidelines.<sup>580</sup>

Since the diagnosis of HCC versus intrahepatic cholangiocarcinoma can be difficult, AFP testing may also be considered, especially in patients with chronic liver disease. Further, there are a number of mixed HCC/intrahepatic cholangiocarcinoma cases in which AFP may be elevated. LI-RADS provides some guidance in distinguishing between HCC and intrahepatic cholangiocarcinoma lesions.<sup>581</sup>

Early surgical consultation (prior to drainage in jaundiced patients) with a multidisciplinary team is recommended as part of the initial workup for assessment of resectability in intrahepatic and extrahepatic cholangiocarcinomas. The panel emphasizes that a multidisciplinary review of imaging studies involving experienced radiologists and surgeons is necessary to stage the disease and determine potential treatment options (ie, resection or other approach). Providers should only proceed with biopsy once transplant or resectability status has been determined. For patients with hilar cholangiocarcinoma who may be transplant candidates, transperitoneal biopsy is contraindicated and will likely preclude transplantation based on current protocols.<sup>582</sup> For patients undergoing resection, biopsy is usually not necessary. When necessary, intraluminal biopsy is the preferred biopsy approach for potential transplant patients.

In patients who are not resectable, direct visualization of the bile duct with directed biopsies is the ideal technique for the workup of cholangiocarcinoma. Multiphasic CT/MRI with IV contrast of the abdomen and pelvis to assess the involvement of the liver, major vessels, nearby lymph nodes, and distant sites is also recommended when extrahepatic cholangiocarcinoma is suspected.<sup>583,584</sup> There are no pathognomonic CT/MRI features associated with intrahepatic cholangiocarcinoma, but CT/MRI can indicate the involvement of major vessels and the presence of

vascular anomalies and satellite lesions.<sup>583</sup> Therefore, multiphasic CT/MRI with IV contrast is used to help determine tumor resectability by characterizing the primary tumor, its relationship to nearby major vessels and the biliary tree, the presence of satellite lesions and distant metastases in the liver, and lymph node involvement.<sup>98,583</sup> In addition, chest CT (with or without contrast) should be performed, and staging laparoscopy may be considered in conjunction with surgery if no distant metastasis is found. Endoscopic US may be useful for distal common bile duct cancers for defining a mass or abnormal thickening, which can direct biopsies. For hilar cholangiocarcinoma, endoscopic US should only be done after surgical consultation to prevent jeopardizing a patient's candidacy for transplantation. EGD and colonoscopy are recommended as part of initial workup for patients with intrahepatic cholangiocarcinoma since a mass diagnosed as adenocarcinoma can be metastatic disease. Pathologic workup can be suggestive of cholangiocarcinoma but is not definitive. IgG4-associated cholangitis, which presents with biliary strictures and obstructive jaundice, may mimic extrahepatic cholangiocarcinoma.<sup>585,586</sup> Therefore, serum IgG4 should be considered in patients for whom a diagnosis of extrahepatic cholangiocarcinoma is not clear, in order to avoid an unnecessary surgical resection.<sup>587,588</sup> Patients with IgG4-related cholangiopathy should be referred to an expert center.

Contrast-enhanced MRCP and/or CT as a diagnostic modality is recommended over direct cholangiography for the diagnosis of bile duct cancers.<sup>589,590</sup> MRCP has been shown to have a higher sensitivity, specificity, and diagnostic accuracy compared to ERCP in the diagnosis and pre-treatment staging of hilar cholangiocarcinomas.<sup>591</sup> Data also support the use of MRCP and CT as the preferred method of cholangiography for the assessment of bile duct tumors.<sup>592</sup> Direct cholangiography should only be performed when necessary as a diagnostic procedure in patients who are not resectable or in patients in whom a therapeutic intervention is necessary. ERCP/PTC is not





recommended for the diagnosis of extrahepatic cholangiocarcinoma, since this is associated with complications and contamination of the biliary tree. For distal bile duct tumors in which a diagnosis is needed or where palliation is indicated, an ERCP allows for complete imaging of the bile duct and stenting of the obstruction. In addition, brush cytology of the bile duct can be obtained for pathologic evaluation. Since many of the patients with extrahepatic cholangiocarcinoma present with jaundice, workup should include noninvasive cholangiography with cross-sectional imaging to evaluate local tumor extent.<sup>583</sup> Although the role of PET imaging has not been established in the evaluation of patients with cholangiocarcinoma, emerging evidence indicates that it may be useful for the detection of regional lymph node metastases and distant metastatic disease in patients with otherwise potentially resectable disease.<sup>524-526,593,594</sup>

### **Management of Intrahepatic Cholangiocarcinoma**

Complete resection is the only potentially curative treatment for patients with resectable disease, although most patients are not candidates for surgery due to the presence of advanced disease at diagnosis. The optimal surgical margin associated with improved survival and reduced risk of recurrence in patients undergoing surgery remains uncertain, with some reports documenting R0 resection as a significant predictor of survival and recurrence,<sup>595-600</sup> while others suggest that margin status is not a significant predictor of outcome.<sup>601,602</sup> Ribero et al from the Italian Intrahepatic Cholangiocarcinoma Study Group reported that margin-negative resection was associated with significantly higher survival rates (the estimated 5-year survival rates were 39.8% vs. 4.7% for patients with a positive margin) and significantly lower recurrence rates (53.9% vs. 73.6% for those with a positive margin); however, in patients resected with negative margins, the margin width had no long-term impact on survival ( $P = .61$ ) or recurrence ( $P > .05$ ) following resection.<sup>600</sup> Farges et al from the AFC-IHCC-2009 study group reported that although R1 resection was the strongest independent predictor of poor outcome in pN0 patients

undergoing surgery, its prognostic impact on survival was very low in pN+ patients (median survival was 18 months and 13 months, respectively, after R0 and R1 resections;  $P = .10$ ).<sup>602</sup> In this study, a margin width greater than 5 mm was an independent predictor of survival among pN0 patients with R0 resections, which is in contrast to the findings reported by Ribero et al.<sup>600</sup> A retrospective analysis of 535 patients with intrahepatic cholangiocarcinoma who underwent resection showed that other factors associated with worse survival post-resection include multifocal disease (HR, 1.49; 95% CI, 1.19–1.86;  $P = .01$ ), lymph node metastasis (HR, 2.21; 95% CI, 1.67–2.93;  $P < .01$ ), and vascular invasion (HR, 1.39; 95% CI, 1.10–1.75;  $P = .006$ ).<sup>603</sup>

Available evidence (although not conclusive) supports the recommendation that hepatic resection with negative margins should be the goal of surgical therapy for patients with potentially resectable disease.<sup>604</sup> Extensive hepatic resections are often necessary to achieve clear margins since the majority of tumors present as large masses.<sup>600</sup>

Initial surgical exploration should include assessment of multifocal liver disease, lymph node metastases, and distant metastases. Multifocal liver disease, distant (beyond the porta hepatis) nodal metastases, and distant metastases contraindicate surgery as these generally indicate advanced incurable disease. In highly selected situations, resection can be considered. A preoperative biopsy is not always necessary prior to definitive and potentially curative resection. Although limited multifocal liver tumors (including satellite lesions) and gross lymph node metastases to the porta hepatis are considered relative contraindications to surgery, surgical approaches can be considered in selected patients. Patient selection for surgery is facilitated by careful preoperative staging, which may include laparoscopy to identify patients with unresectable or disseminated metastatic disease.<sup>605,606</sup> Staging laparoscopy has been shown to identify peritoneal metastases and liver metastases with a





respective yield of 36% and 67% accuracy in patients with potentially resectable intrahepatic cholangiocarcinoma.<sup>605</sup> A portal lymphadenectomy helps provide accurate staging information.<sup>607</sup> Lymph node metastasis is an important prognostic indicator of survival.<sup>570,600</sup> Therefore, regional lymphadenectomy of the porta hepatis is recommended. It is important to note, however, that there are no data to support a therapeutic benefit of routine lymph node dissection in patients undergoing surgery.<sup>608-611</sup>

The optimal adjuvant treatment strategy for patients with resected intrahepatic cholangiocarcinoma has not been determined and there are limited clinical trial data to support a standard regimen for adjuvant treatment. Lymphovascular and perineural invasion, lymph node metastasis, and tumor size greater than or equal to 5 cm have been reported as independent predictors of recurrence and reduced OS following resection.<sup>612-614</sup> Since recurrence following resection is common, these tumor-specific risk factors could be considered as criteria for selection of patients for adjuvant treatment in clinical trials. See *Adjuvant Chemotherapy and Chemoradiation for Biliary Tract Cancers* in this discussion.

Primary treatment options for patients with unresectable or metastatic disease include: 1) clinical trial; 2) systemic therapy; or 3) best supportive care. In addition, fluoropyrimidine chemoradiation is included as an option for patients with unresectable disease. See sections on *Chemotherapy* and *Chemoradiation and Radiation Therapy for Treatment for Advanced Biliary Tract Cancers* in this discussion.

### Locoregional Therapy

Locoregional therapies such as RFA,<sup>615,616</sup> TACE,<sup>617-619</sup> DEB-TACE, or TACE drug-eluting microspheres,<sup>618,620,621</sup> and TARE with Y-90 microspheres<sup>619,622-627</sup> have been shown to be safe and effective in a small retrospective series of patients with unresectable intrahepatic cholangiocarcinomas. The results of two independent prospective studies

showed that the efficacy of TACE with irinotecan DEB was similar to that of gemcitabine and oxaliplatin (GEMOX), but was superior to that of TACE with mitomycin in terms of PFS and OS for patients with unresectable intrahepatic cholangiocarcinoma.<sup>618</sup> In a systematic review of 12 studies with 298 patients, the effects of radioembolization with Y-90 microspheres in unresectable intrahepatic cholangiocarcinoma were assessed.<sup>628</sup> The overall weighted median survival for this treatment was 15.5 months, partial tumor response was seen for 28% of patients, and SD was seen for 54% of patients. Other smaller series have also reported favorable response rates and survival benefit for patients with unresectable intrahepatic cholangiocarcinoma treated with TARE with Y-90 microspheres.<sup>622,625,627</sup> Due to the rarity of this disease, none of these locoregional approaches has been evaluated in RCTs. In the phase II MISPHEC trial, investigators determined that the combination of radioembolization with Y-90 microspheres with chemotherapy (cisplatin and gemcitabine) as a first-line treatment option in 41 patients with unresectable intrahepatic cholangiocarcinoma resulted in a 39% response rate, by RECIST criteria.<sup>629</sup> The median PFS and OS were 14 months and 22 months, respectively. Additionally, 22% of patients were downstaged to surgery.

Radiation therapy is a locoregional treatment option for unresectable intrahepatic cholangiocarcinoma.<sup>630</sup> A single-institution study including 79 patients with unresectable intrahepatic cholangiocarcinoma showed that higher doses of RT (3D-CRT with photons or protons) were associated with better 3-year OS (73% vs. 38%, respectively;  $P = .017$ ) and 3-year local control (78% vs. 45%, respectively;  $P = .04$ ), compared with lower doses of RT.<sup>631</sup> SBRT may also be used for patients with unresectable intrahepatic cholangiocarcinoma.<sup>405</sup> A non-randomized multi-institutional trial including 39 patients with unresectable intrahepatic cholangiocarcinoma showed that hypofractionated proton therapy resulted in a 2-year OS rate of 46.5% (median OS was 22.5 months) and a 2-year



PFS rate of 25.7%.<sup>408</sup> Therefore, hypofractionated proton therapy may also be considered for patients with unresectable intrahepatic cholangiocarcinoma, but this treatment should only be administered at experienced centers.

Data from prospective studies support the use of hepatic arterial infusion (HAI) chemotherapy in patients with advanced, liver confined, and unresectable intrahepatic cholangiocarcinoma.<sup>632-636</sup> In a meta-analysis including 20 studies ( $N = 657$ ), HAI was compared to TACE, DEB-TACE, and TARE with Y-90 microspheres.<sup>637</sup> OS and tumor response were greatest for HAI, with a median tumor response rate of 57%, though grade III/IV toxicity was also highest, relative to the other arterially directed therapies. A retrospective analysis of 525 patients with intrahepatic cholangiocarcinoma showed that patients who received a combined regimen of HAI and another chemotherapy agent (gemcitabine, irinotecan, or 5-FU) had greater OS, relative to patients receiving chemotherapy without HAI (30.8 vs. 18.4 months,  $P < .001$ ).<sup>638</sup>

Based on the available evidence as discussed above, the panel has included locoregional therapy as a treatment option that may be considered for patients with unresectable disease or metastatic cancer without extrahepatic disease. Intra-arterial chemotherapy is recommended only in the context of a clinical trial or at experienced centers for patients with advanced disease confined to the liver.

### **Management of Extrahepatic Cholangiocarcinoma**

Complete resection with negative margins is the only potentially curative treatment for patients with resectable disease. The reported 5-year survival rates following complete resection are in the range of 20% to 42% and 16% to 52%, respectively, for patients with hilar and distal cholangiocarcinomas.<sup>639,640</sup>

Surgical margin status and lymph node metastases are independent predictors of survival following resection.<sup>599,641,642</sup> Regional lymphadenectomy of the porta hepatis (hilar cholangiocarcinoma) or in the area of the head of the pancreas (distal cholangiocarcinoma) are considered standard parts of curative resections.<sup>643,644</sup> Since these surgical procedures are associated with postoperative morbidity, they should be carried out in patients who are medically fit for a major operation. Surgery is contraindicated in patients with distant metastatic disease to the liver, peritoneum, or distant lymph nodes beyond the porta hepatis (or head of the pancreas for distal tumors).

The type of surgical procedure for a resectable tumor is based on its anatomic location in the biliary tract. Resection of the involved biliary tract and en bloc liver resection (typically a major hepatectomy involving the right or left liver with the caudate lobe) is recommended for hilar tumors. Bile duct excision with frozen section assessment of proximal and distal bile duct margins and pancreaticoduodenectomy can be attempted for mid bile duct tumors not involving the liver or pancreas. However, mid bile duct tumors that can be completely resected with an isolated bile duct resection are uncommon. A combined pancreaticoduodenectomy and hepatic resection is required, in rare instances, for a bile duct tumor with extensive biliary tract involvement. This operation, however, is associated with high morbidity and should only be considered in well-selected cases.<sup>645,646</sup> Combined hepatic and pancreatic resections to clear distant nodal disease (as opposed to biliary extent) are not recommended, as these are highly morbid procedures with no obvious associated survival advantage. The guidelines recommend consideration of biliary drainage prior to definitive resection for patients with jaundice. However, caution should be exercised in patients with hilar biliary obstruction as drainage is not always simple and can be associated with significant morbidity.<sup>647</sup> Decisions about whether preoperative biliary drainage is appropriate (and the type of



drainage) should be made by a multidisciplinary team at a high-volume center.

In patients with hilar cholangiocarcinoma, extended hepatic resection (to encompass the biliary confluence) with caudate lobectomy is recommended, since hilar tumors, by definition, abut or invade the central portion of the liver. The recommendation for extended liver resection is supported by retrospective analyses showing a higher rate of R0 resection, prolonged survival, and decreased hepatic recurrence associated with extended hepatic resections as compared to bile duct resections.<sup>648-652</sup> Resection and reconstruction of the portal vein and/or hepatic artery may be necessary for complete resection, especially in patients with more advanced disease. This approach requires substantial experience and appropriate surgical support for such technical operations.<sup>653,654</sup> For adjuvant treatment of resected hilar cholangiocarcinoma, see the section on *Adjuvant Chemotherapy and Chemoradiation for Biliary Tract Cancers*.

Patient selection for surgery is facilitated by careful preoperative staging, surgical exploration, biopsy, and consideration of diagnostic laparoscopy to identify patients with unresectable or distant metastatic disease. A preoperative biopsy is not necessary if the index of suspicion is high. Laparoscopy can identify the majority of patients with occult metastatic hilar cholangiocarcinoma, albeit with a lower yield. A review including six studies of staging laparoscopy in patients with hilar cholangiocarcinoma showed a yield of 14% to 45% and an accuracy of 32% to 71%.<sup>655</sup> The decreasing yield of staging laparoscopy over time may be due to improvements in imaging techniques.<sup>656</sup>

While not routinely used in all patients undergoing resection, the consensus of the panel is that in patients with hilar cholangiocarcinoma, preoperative treatments including biliary drainage targeted to the FLR (using ERCP or PTC)<sup>657-660</sup> and contralateral PVE<sup>661,662</sup> should be

considered for patients with low FLR volumes. Patients with unresectable or metastatic disease should be considered for biliary drainage using either surgical bypass (although rarely used) or ERCP or PTC, most often involving biliary stent placement.<sup>663-666</sup>

In patients with unresectable or metastatic disease, biopsy is recommended to confirm the diagnosis prior to the initiation of further treatment. For patients with unresectable disease, biopsy is recommended only after determining transplant status. Molecular testing is recommended to potentially guide targeted treatment. Primary treatment options for these patients include: 1) clinical trial; 2) systemic therapy; or 3) best supportive care. In addition, RT or fluoropyrimidine chemoradiation are also included as options for patients with unresectable disease. Data to support particular chemoradiation and chemotherapy regimens are limited. See sections on *Chemotherapy* and *Chemoradiation and Radiation Therapy for Treatment of Advanced Biliary Tract Cancers*.

Liver transplantation is a potentially curative option for selected patients with lymph node-negative, non-disseminated, locally advanced hilar cholangiocarcinomas.<sup>667-670</sup> There is retrospective evidence suggesting that neoadjuvant chemoradiation followed by liver transplantation is effective for selected patients with hilar cholangiocarcinoma.<sup>671-673</sup> Results from two studies suggest that the combination of liver transplantation and neoadjuvant and/or adjuvant chemoradiation is associated with higher RFS than a potentially curative resection.<sup>674,675</sup> However, in one of these studies, there were substantial differences in the characteristics of patients in the two treatment groups.<sup>674</sup> It is important to note that many of these reports include patients with primary sclerosing cholangitis, and some have not had a definitive histologic cancer diagnosis. Liver transplantation should be considered only for highly selected patients (ie, tumor  $\leq 3$  cm in radial diameter, no intrahepatic or extrahepatic metastases, no nodal disease) with either unresectable disease with otherwise normal biliary



and hepatic function or underlying chronic liver disease precluding surgery. The panel encourages continuation of clinical research in this area, and referral of patients with unresectable disease to a transplant center with an UNOS-approved protocol for transplant of cholangiocarcinoma should be considered.

Photodynamic therapy (PDT) is an ablative therapy that involves intravenous injection of a photosensitizing drug followed by selective irradiation with light of a specific wavelength to initiate localized drug activation, and has been used for palliation in patients with extrahepatic cholangiocarcinoma. The combination of PDT with biliary stenting was reported to be associated with prolonged OS in patients with unresectable cholangiocarcinoma in two small RCTs.<sup>676,677</sup>

### Surveillance

There are no data to support a specific surveillance schedule or tests in patients undergoing resection of cholangiocarcinoma; determination of appropriate follow-up schedule/imaging should include a careful patient/physician discussion. It is recommended that follow-up of patients undergoing resection of cholangiocarcinoma should include consideration of imaging studies every 6 months for 2 years, then annually up to 5 years. Re-evaluation according to the initial workup should be considered in the event of disease progression.

### Adjuvant Chemotherapy and Chemoradiation for Biliary Tract Cancers

Recurrence following surgery is a primary limitation for cure in patients with biliary tract cancers, which provides an important justification for the use of adjuvant therapy. In a sample of 80 patients with extrahepatic cholangiocarcinoma who underwent resection, 48.8% died of disease by 28 months, while 11.3% died of other causes.<sup>576</sup> The role of adjuvant chemotherapy or chemoradiation therapy in patients with resected biliary tract cancers is poorly defined, with a lack of data from phase III

RCTs.<sup>678,679</sup> Due to the low incidence of biliary tract cancers, the efficacy and safety of adjuvant chemotherapy or chemoradiation therapy in these patients have been evaluated mostly in retrospective studies that have included only a small number of patients. Further, these studies often combined patients with gallbladder and bile duct cancers (with a few exceptions), which is problematic since the biology of these tumors is completely different. Despite the challenges associated with the accrual of large numbers of patients with biliary tract cancer for randomized phase III trials, it is widely recognized that efforts should be made to conduct such studies in which the individual disease entities are evaluated separately.

Data supporting adjuvant chemotherapy in patients with resected biliary tract cancer have come from two randomized phase III trials. In the phase III BILCAP study, 447 patients with completely resected cholangiocarcinoma or gallbladder cancer were randomized to receive either adjuvant capecitabine or observation.<sup>680</sup> RFS was significantly greater for patients in the capecitabine arm in both the intent-to-treat analysis (24.4 months vs. 17.5 months; HR, 0.75; 95% CI, 0.58–0.98;  $P = .033$ ) and in the per-protocol analysis ( $n = 430$ ; HR, 0.70; 95% CI, 0.54–0.92;  $P = .009$ ). Median OS was 51.1 months for the capecitabine arm and 36.4 months for the observation arm. This difference was statistically significant in the per-protocol analysis (HR, 0.75; 95% CI, 0.58–0.97;  $P = .028$ ) but not in the intent-to-treat analysis.

In the second phase III randomized trial, 508 patients with resected pancreaticobiliary cancer (139 patients had cholangiocarcinoma and 140 patients had gallbladder cancer) were randomly assigned to adjuvant chemotherapy with fluorouracil and mitomycin C or to a control arm.<sup>681</sup> Results from unplanned subgroup analyses showed a significantly better 5-year DFS for patients with gallbladder cancer treated with chemotherapy (20.3% compared to 11.6% in the control group;  $P = .021$ ), although no significant differences between the two treatment arms were observed for





all patients with biliary duct cancers. Results from this trial support the suggestion that patients with gallbladder cancer undergoing resection may derive survival benefit with adjuvant chemotherapy.

Negative results have been found for two gemcitabine-based regimens in two randomized phase III trials. In the phase III PRODIGE 12-ACCORD 18 trial, 196 patients with R0 or R1 resected biliary tract cancer were randomized to receive gemcitabine/oxaliplatin or surveillance alone.<sup>682</sup> No statistically significant differences were found between the study arms for RFS and OS. Negative results for survival outcomes were also found in a phase III trial from Japan evaluating the efficacy of gemcitabine monotherapy (compared to observation) in 226 patients with resected extrahepatic cholangiocarcinoma.<sup>683</sup>

Retrospective studies that have combined patients with gallbladder cancer and cholangiocarcinomas provide conflicting evidence regarding the role of adjuvant therapy.<sup>505,684,685</sup> It should be noted that the majority of recurrences after resection of gallbladder cancer involve distant sites, supporting the idea of developing effective adjuvant systemic therapies.<sup>505</sup>

In a systematic review and meta-analysis of 6712 patients with biliary tract cancers, Horgan et al reported an associated improvement in OS (although nonsignificant) with adjuvant therapy compared with surgery alone, with no difference between patients with gallbladder cancer and bile duct cancers.<sup>686</sup> Chemotherapy or chemoradiation therapy was associated with statistically greater benefit than RT alone, with the greatest benefit observed in patients with lymph node-positive disease and macroscopic residual disease (R1 resection). Another systematic review and meta-analysis of 42,917 patients found a significantly higher OS with adjuvant therapy after surgery compared with surgery alone.<sup>687</sup> Ren et al reported a higher 5-year OS with adjuvant radiotherapy post surgery in patients with gallbladder cancer or extrahepatic cholangiocarcinoma in a meta-analysis of 21 clinical trials.

In studies that included only patients with gallbladder cancer, a meta-analysis including 10 retrospective studies with 3191 patients showed that adjuvant chemotherapy was associated with improved OS, compared to resection alone (HR, 0.42; 95% CI, 0.22–0.80).<sup>688</sup> Subgroup analyses showed that the patients who are most likely to benefit from adjuvant therapy include those with a positive margin, those with nodal disease, and those with at least stage II disease. Retrospective studies have concluded that adjuvant chemotherapy or chemoradiation following R0 resection might improve OS in selected patients with T2 or T3 tumors and lymph node-positive gallbladder cancer.<sup>689-692</sup>

Retrospective studies that included only patients with resected extrahepatic cholangiocarcinoma suggest that adjuvant chemoradiation may improve local control and survival, although distant metastases was the most common pattern of failure.<sup>693-696</sup> Other studies have suggested that adjuvant chemoradiation may have a significant survival benefit only in a subgroup of patients with T3 or T4 tumors or those with a high risk of locoregional recurrence (R1 resection or positive lymph nodes).<sup>695,697,698</sup>

Most of the collective experience of chemoradiation in biliary tract cancers involves concurrent chemoradiation and fluorouracil. The phase II SWOG S0809 trial, which enrolled patients with extrahepatic cholangiocarcinoma or gallbladder cancer ( $N = 79$ ), provided prospective data on adjuvant chemotherapy/chemoradiation (ie, capecitabine/gemcitabine followed by concurrent capecitabine and RT). Two-year OS was 65%, and median survival was 35 months. A majority of patients enrolled in the trial (86%) completed therapy, and the regimen was generally tolerable. Confirmatory phase III trial data are needed. Concurrent chemoradiation with capecitabine has been used in other studies.<sup>695,699</sup> Concurrent chemoradiation with gemcitabine is not recommended due to the limited experience and toxicity associated with this treatment.<sup>700</sup>





# NCCN Guidelines Version 5.2021

## Hepatobiliary Cancers

Among patients with cancer of the gallbladder or extrahepatic bile duct, those who have undergone an R0 resection and who have negative regional nodes or those with carcinoma in situ at margin may be followed with observation alone, receive fluoropyrimidine chemoradiation, or receive fluoropyrimidine or gemcitabine chemotherapy. Patients with intrahepatic cholangiocarcinoma who have undergone an R0 resection may be observed or treated with fluoropyrimidine or gemcitabine chemotherapy. Chemoradiation is not a recommended treatment option for these patients.

Recommended chemotherapy regimens for these patients include gemcitabine monotherapy or combined with cisplatin or capecitabine, capecitabine monotherapy or combined with cisplatin or oxaliplatin, and 5-fluorouracil monotherapy or combined with oxaliplatin. Besides capecitabine monotherapy, whose use in this setting is supported by the phase III BILCAP study,<sup>680</sup> data to support particular chemotherapy regimens for adjuvant treatment of resected biliary tract cancer are limited due to lack of clinical trial data and are based on the extrapolation of data from studies of patients with advanced disease. Additionally, some of the recommendations are based on practice patterns at NCCN Member Institutions and retrospective studies from single-center experiences. Besides gemcitabine monotherapy not being recommended for patients with resected extrahepatic cholangiocarcinoma (based on the negative results of a phase III Japanese trial<sup>683</sup>), the recommendations in the NCCN Guidelines on the use of adjuvant chemotherapy are not specific to the particular type of biliary tract cancer, due to the limited data and the heterogeneity of patient populations included in many of the published studies. Based on the negative results of the randomized phase III PRODIGE 12-ACCORD 18 trial,<sup>682</sup> gemcitabine/oxaliplatin was removed as a recommended regimen for resected biliary tract cancer in 2019.

Patients with microscopic positive tumor margins (R1), gross residual local disease (R2), or positive regional lymph nodes after resection should be evaluated by a multidisciplinary team to review the available treatment options on a case-by-case basis. Treatment of patients with gross residual disease (R2) should be consistent with treatment for unresectable disease. For patients with R1 margins or positive regional nodes, the optimal treatment strategy has not been established but may include fluoropyrimidine-based or gemcitabine-based chemotherapy or fluoropyrimidine chemoradiation. Fluoropyrimidine or gemcitabine-based chemotherapy may be followed by fluoropyrimidine-based chemoradiation, and vice versa. There are limited data to support a specific chemoradiation regimen. If radiotherapy is used, then EBRT using 3D-CRT and IMRT are options.<sup>701,702</sup> Dosing schedules may depend on margin positivity and may include 45 Gy at 1.8 Gy/fraction or 50 to 60 Gy at 1.8 to 2.0 Gy/fraction (to allow for an integrated boost) to the tumor bed.<sup>679,703</sup>

### Treatment for Advanced Biliary Tract Cancers

The prognosis of patients with advanced biliary tract cancers is poor and the median survival for those undergoing supportive care alone is short.<sup>704</sup> Treatment options for advanced biliary tract cancers include enrollment in a clinical trial, systemic therapy (gemcitabine- or fluoropyrimidine-based chemotherapy, or pembrolizumab for patients with MSI-H/dMMR tumors), fluoropyrimidine-based chemoradiation, and radiotherapy without additional chemotherapy.

### Chemotherapy

The survival benefit of chemotherapy (fluorouracil, leucovorin, and etoposide) over best supportive care for patients with advanced biliary tract cancers was initially suggested in a phase III trial of 90 patients with advanced pancreatic and biliary tract cancers, 37 of whom had advanced biliary tract cancers.<sup>705</sup> In a single-center randomized study of 81 patients with unresectable gallbladder cancer, Sharma et al reported that modified



GEMOX improved PFS and OS compared to best supportive care or fluorouracil.<sup>706</sup> Median OS was 4.5, 4.6, and 9.5 months, respectively, for the best supportive care, fluorouracil, and modified GEMOX arms ( $P = .039$ ). The corresponding PFS was 2.8, 3.5, and 8.5 months ( $P < .001$ ).

Several phase II studies have also demonstrated the efficacy of chemotherapy for the treatment of patients with advanced biliary tract cancers.<sup>707,708</sup> The results of a pooled analysis of 104 trials that have included 2810 patients with advanced biliary tract cancers showed that response rates and tumor control were higher for the subgroup of patients receiving a combination of gemcitabine and platinum-based agents.<sup>709</sup> In a retrospective study of 304 patients with unresectable biliary tract cancers who were treated with gemcitabine alone, a cisplatin-based regimen, or a fluoropyrimidine-based regimen, patients receiving gemcitabine were shown to have a lower risk of death.<sup>710</sup> Most importantly, the support for the use of gemcitabine-based or fluoropyrimidine-based chemotherapy for patients with advanced biliary tract cancers comes from four randomized studies.<sup>711-714</sup>

The randomized, controlled, phase III ABC-02 study, which enrolled 410 patients with locally advanced or metastatic cholangiocarcinoma, gallbladder cancer, or ampullary cancer, demonstrated that the combination of gemcitabine and cisplatin improved OS and PFS by 30% over gemcitabine alone.<sup>713</sup> Median OS was 11.7 months and 8.1 months (HR, 0.64; 95% CI, 0.52–0.80;  $P < .001$ ), and median PFS was 8.0 months vs. 5.0 months (HR, 0.63; 95% CI, 0.51–0.77;  $P < .001$ ), both in favor of the combination arm. Although the rate of neutropenia was higher in the group receiving gemcitabine and cisplatin, there was no significant difference in the rate of neutropenia-associated infections between the two arms. Okusaka et al also reported similar findings in a phase II randomized study of 84 patients with advanced biliary tract cancers.<sup>714</sup> Combined analyses from both of these trials ( $n = 227$ ) showed that

derived neutrophil-to-lymphocyte ratio assessed at baseline was associated with greater long-term survival in those randomized to receive gemcitabine/cisplatin ( $P < .01$ ).<sup>715</sup> Based on these results, the combination of gemcitabine and cisplatin is considered to be the standard of care for first-line chemotherapy for patients with advanced or metastatic biliary tract cancers. Results from the randomized phase III ABC-06 study showed that compared to active symptom control alone, active symptom control combined with FOLFOX in patients previously treated with combined cisplatin and gemcitabine improved median OS (6.2 months vs. 5.3 months; adjusted HR, 0.69;  $P = .031$ ).<sup>716</sup> Second-line treatment with fluorouracil and irinotecan (FOLFIRI) also provided some benefits to patients.<sup>717</sup>

Examples of other gemcitabine-based or fluoropyrimidine (fluorouracil or capecitabine)-based regimens with demonstrated activity in phase II trials include: gemcitabine and cisplatin or oxaliplatin<sup>718-726</sup>; gemcitabine and fluoropyrimidine<sup>727-731</sup>; gemcitabine and albumin-bound paclitaxel (for cholangiocarcinoma)<sup>732</sup>; gemcitabine, cisplatin, and albumin-bound paclitaxel<sup>733</sup>; gemcitabine and cetuximab<sup>734</sup>; and fluoropyrimidine and oxaliplatin or cisplatin.<sup>735-738</sup> In the phase II trial examining the combination of gemcitabine-cisplatin with albumin-bound paclitaxel, the disease status of 20% of patients went from unresectable to resectable.<sup>733</sup> A phase III study showed that the combination of capecitabine and oxaliplatin was non-inferior to the gemcitabine and oxaliplatin combination in terms of the 6-month PFS.<sup>739</sup> Triple-drug chemotherapy regimens have also been shown to be effective in patients with advanced biliary tract cancers, albeit in a very small number of patients.<sup>740-742</sup> The phase III trial that evaluated fluorouracil, leucovorin, and etoposide versus fluorouracil, cisplatin, and epirubicin did not show one regimen to be significantly superior with respect to OS (12 months vs. 9 months, respectively) in patients with advanced biliary tract cancers, although the trial was underpowered to detect such a difference.<sup>740</sup> In a phase II trial, the combination of



panitumumab, a monoclonal anti-EGFR antibody, with gemcitabine and irinotecan showed encouraging efficacy with good tolerability in patients with advanced cholangiocarcinoma, with a 5-month PFS rate of 69%.<sup>743</sup> The median PFS and OS were 9.7 months and 12.9 months, respectively.

The effects of other gemcitabine combination therapies have been examined in phase II trials. In a randomized phase II study of 51 patients, Kornek et al established the efficacy and tolerance of mitomycin in combination with gemcitabine or capecitabine in previously untreated patients with advanced biliary tract cancers.<sup>711</sup> Mitomycin and capecitabine were associated with superior CR rate (31% vs. 20%), median PFS (5.3 months vs. 4.2 months), and OS (9.25 months vs. 6.7 months). The results of the 40955 EORTC trial showed that cisplatin and fluorouracil was more active than high-dose fluorouracil in terms of overall response rates (19% and 7.1%, respectively) and OS (8 months and 5 months, respectively), but the PFS was similar in both treatment arms (3.3 months).<sup>712</sup> In a randomized phase II trial, the combination of gemcitabine and sorafenib was compared to gemcitabine with a placebo in 102 patients with unresectable or metastatic biliary tract cancer.<sup>744</sup> There were no significant between-group differences for OS and PFS rates, but patients who developed liver metastases following resection survived longer if they received sorafenib, relative to patients who received the placebo ( $P = .019$ ). The gemcitabine/sorafenib combination was well-tolerated. Data from phase III trials are needed.

The panel has included combination therapy with gemcitabine and cisplatin with a category 1 recommendation for patients with unresectable or metastatic biliary tract cancers. Based on the experiences from phase II studies, the following gemcitabine-based and fluoropyrimidine-based combination chemotherapy regimens are included with a category 2A recommendation for the treatment of patients with advanced biliary tract cancer: gemcitabine with oxaliplatin or capecitabine; capecitabine with

oxaliplatin; fluorouracil with oxaliplatin; and single-agent fluorouracil, capecitabine, and gemcitabine. Gemcitabine combined with albumin-bound paclitaxel is an option for patients with unresectable or metastatic biliary tract cancer. Capecitabine or fluorouracil, with cisplatin, are included as a category 2B recommendation. The combination of gemcitabine and fluorouracil is not included due to the increased toxicity and decreased efficacy observed with this regimen<sup>727</sup> when compared with results of studies of the gemcitabine and capecitabine regimen in the setting of advanced biliary tract cancer.

In a systematic review including 23 studies (14 phase II clinical trials and 9 retrospective studies) with 761 patients with advanced biliary tract cancer, the efficacy of second-line chemotherapy was examined.<sup>745</sup> There is insufficient evidence to recommend specific regimens for second-line therapy in this group of patients, and prospective randomized trials are needed.

### ***Chemoradiation and Radiation Therapy***

Chemoradiation in the setting of advanced biliary tract cancers can provide control of symptoms due to local tumor effects and may prolong OS. However, there are limited clinical trial data to define a standard regimen or definitive benefit. In a retrospective analysis of 37 patients treated with chemoradiation for unresectable extrahepatic cholangiocarcinoma, the actuarial OS rates at 1 and 2 years were 59% and 22%, respectively, although effective local control was observed in the majority of patients during this time period (actuarial local control rates of 90% and 71% at 1 and 2 years, respectively).<sup>746</sup> The most extensively investigated chemotherapeutic agent for use in concurrent chemoradiation in the treatment of biliary tract cancers has been fluorouracil,<sup>747,748</sup> although capecitabine has been substituted for fluorouracil in some studies.<sup>699</sup> The panel recommends that concurrent chemoradiation (EBRT guided by imaging) should be limited to either fluorouracil or capecitabine,



and that such treatment should be restricted to patients without evidence of metastatic disease. Concurrent chemoradiation with gemcitabine is not recommended due to the limited experience and toxicity associated with this treatment.

RT with EBRT and SBRT may be used for patients with unresectable biliary tract cancers. Evidence supports the consideration of RT for treatment of unresectable and metastatic intrahepatic cholangiocarcinoma,<sup>405,408,631,749</sup> but there is little evidence to support this treatment option for gallbladder cancer and extrahepatic cholangiocarcinoma without concurrent chemotherapy and in patients with unresected disease.<sup>750,751</sup>

### Targeted Therapy

There is an increasing role for molecular profiling of cholangiocarcinomas. *IDH1/2* mutations are found in 10% to 23% of intrahepatic cholangiocarcinomas.<sup>752-758</sup> The prognostic effect of this mutation in intrahepatic cholangiocarcinoma is uncertain,<sup>759</sup> but the *IDH1* mutation, which accounts for 0.8% (95% CI, 0.4%–1.5%) of patients with extrahepatic cholangiocarcinoma,<sup>760</sup> is associated with poor prognosis in these patients.<sup>758</sup> A phase III study with 185 patients with advanced *IDH1*-mutant cholangiocarcinoma resulted in significant improvement in PFS (median 2.7 months vs. 1.4 months; HR, 0.37;  $P < .0001$ ) when treated with ivosidenib, an *IDH1* inhibitor, compared to placebo.<sup>761</sup> The panel voted to include ivosidenib as a subsequent-line treatment option “useful in certain circumstances” for unresectable or metastatic cholangiocarcinoma with *IDH1* mutations following disease progression. Mutations in *FGFR2* fusions have been found in 13% to 14% of intrahepatic cholangiocarcinomas.<sup>762-764</sup> *FGFR* mutations may be associated with a favorable prognosis.<sup>757,763</sup> In the phase II FIGHT-202 clinical trial, pemigatinib, an *FGFR* inhibitor, demonstrated promising therapeutic potential, with 35.5% of patients with cholangiocarcinoma and

*FGFR2* fusions or rearrangements achieving an objective response.<sup>765</sup> In another phase II study, published in an abstract, treatment with infigratinib, an *FGFR1-3* inhibitor, led to an ORR of 23.1% (95% CI, 15.6 %–32.2%) in patients with previously treated advanced/metastatic cholangiocarcinoma with *FGFR2* fusions or rearrangements.<sup>766</sup> The median duration of response was 5.0 months and the median PFS was 7.3 months (95% CI, 5.6 months–7.6 months). The panel voted to include pemigatinib and infigratinib as subsequent-line treatment options “useful in certain circumstances” for unresectable or metastatic cholangiocarcinoma with *FGFR2* fusions or rearrangements following disease progression.

*NTRK* fusion genes were identified in 0.75% of patients with biliary tract tumors.<sup>767</sup> A few *NTRK* inhibitors such as entrectinib and larotrectinib have shown efficacy against *NTRK* fusion-positive solid tumors.<sup>768-770</sup> The panel voted to include entrectinib and larotrectinib as first-line or subsequent-line (following disease progression) treatment options “useful in certain circumstances” for unresectable or metastatic disease with *NTRK* gene fusions. A study including 35 patients with resected intrahepatic cholangiocarcinoma showed that 17% of these tumors had an *NRAS* mutation, and 14% had a *BAP1* mutation.<sup>758</sup> The same study also analyzed the tumors of 38 patients with extrahepatic cholangiocarcinoma and showed that 47% had a *KRAS* mutation, 24% had a *TP53* mutation, and 16% had an *ARID1A* mutation. *BRAF* V600E mutation was a rare occurrence and was restricted to intrahepatic cholangiocarcinoma.<sup>771,772</sup> In the phase II ROAR trial with 43 patients with *BRAF* V600E-mutated biliary tract cancer, treatment with the oral combination of dabrafenib and trametinib led to an ORR of 51% (95% CI, 36%–67%).<sup>773</sup> Results from the Subprotocol H trial revealed an ORR of 38% (90% CI, 22.9%–54.9%,  $P < .0001$ ) and a PFS of 11.4 months (90% CI, 8.4 months–16.3 months) in 29 patients.<sup>774</sup> In the 2021 update, the panel voted to include the oral combination of dabrafenib and trametinib as a subsequent-line treatment





# NCCN Guidelines Version 5.2021

## Hepatobiliary Cancers

option “useful in certain circumstances” for unresectable or metastatic progressive disease with *BRAF*-V600E mutations.

*HER2* gene amplification has been found in up to 18% of extrahepatic cholangiocarcinomas.<sup>775</sup> In patients with lymph node metastases, *HER2* gene amplification may be associated with poor prognosis.<sup>775</sup> Other gene mutations that may be associated with a poor prognosis are: *ALK* for extrahepatic cholangiocarcinoma; *ARID1A*, *PIK3C2G*, *STK11*, and *TGFR2* for intrahepatic cholangiocarcinoma; and *TP53* for intrahepatic and extrahepatic cholangiocarcinoma.<sup>758</sup> Given emerging evidence regarding actionable targets for treating cholangiocarcinoma, molecular testing of unresectable and metastatic tumors is recommended.

Studies have indicated that MSI-H, dMMR, and TMB-H tumors are sensitive to PD-1 blockade.<sup>494,555,556,776</sup> The phase II KEYNOTE-158 study investigated the use of pembrolizumab in patients with advanced noncolorectal MSI-H/dMMR tumors.<sup>494</sup> Analyses of a cholangiocarcinoma subgroup revealed an ORR of 40.9% (95% CI, 20.7%–63.6%). The median PFS and OS were 4.2 months and 24.3 months, respectively. Data from the study also revealed that patients with a TMB-H status could have a robust response to pembrolizumab.<sup>776</sup> Twenty-nine percent of patients in the TMB-H arm achieved an objective response compared to 6% in the non TMB-H arm. Results were published from a study of patients with dMMR tumors of various disease sites.<sup>555</sup> Among four patients with dMMR cholangiocarcinoma who received pembrolizumab, one patient had a CR, and the remaining patients had SD. Based on these studies, the FDA expanded pembrolizumab approval in 2017 and 2020 to include treatment of unresectable or metastatic, MSI-H, dMMR, or TMB-H solid tumors that have progressed following prior treatment and that have no satisfactory alternative treatment options. The panel voted to include pembrolizumab as a first-line or subsequent-line (following disease progression and with no prior treatment with a checkpoint inhibitor) treatment option “useful in

certain circumstances” for patients with unresectable or metastatic MSI-H, dMMR, and TMB-H (for subsequent-line therapy) biliary tract tumors, though cautions that data to support this recommendation are limited, particularly in the first-line setting.<sup>777</sup>

Dostarlimab-gxly, another anti-PD-1 antibody, was assessed in an open-label phase I study with 2 cohorts.<sup>472</sup> One cohort had 103 patients with advanced or recurrent MSI-H/dMMR endometrial cancer and another had 106 patients with advanced or recurrent MSI-H/dMMR or POLE-hypermuted non-endometrial solid tumors (comprising mostly gastrointestinal tumors [93.4%] with 65.1% colorectal tumors). An interim analysis, published in an abstract, revealed an ORR of 41.6% (95% CI, 34.9%–48.6%), per RECIST v1.1. The ORR for the cohort with non-endometrial cancer was 38.7% (95% CI, 29.4%–48.6%). The median duration of response was not reached (median follow-up of 16.3 months for the cohort with endometrial cancer and 12.4 months for the cohort with non-endometrial cancer). The most frequent grade 3 or higher treatment-related adverse events were anemia (2.2%), elevated lipase (1.9%), elevated alanine aminotransferase (1.1%), and diarrhea (1.1%). Another published abstract demonstrated that among the cohort with non-endometrial cancer, patients with colorectal cancer had an ORR of 36.2% (95% CI, 25.0%–48.7%).<sup>473</sup> The cohort also included one patient with gallbladder cancer and 1 with biliary neoplasm. Both patients had a complete response. The panel voted to include dostarlimab-gxly as a category 2B subsequent-line treatment option “useful in certain circumstances” for patients with MSI-H/dMMR recurrent or advanced tumors that have progressed on or following prior treatment, who have no satisfactory alternative treatment options, and who have not been previously treated with a checkpoint inhibitor.

In a phase II trial with 46 evaluable patients with advanced biliary tract cancers, an ORR of 22% and a disease control rate of 59% were





obtained, upon investigator assessment, with the use of nivolumab, another anti-PD1 drug.<sup>778</sup> With blinded independent central review, the ORR was 11% and the disease control rate was 50%. In the intention-to-treat cohort, the median PFS and median OS were 3.7 months (95% CI, 2.3–5.7 months) and 14.2 months (95% CI, 6.0 months–not reached), respectively. The panel voted to include nivolumab as a category 2B subsequent-line treatment option “useful in certain circumstances” for patients with unresectable or metastatic progressive disease who have not been previously treated with a checkpoint inhibitor.

Initial results from the phase II LEAP-005 trial, published in an abstract that examined the combination of lenvatinib with pembrolizumab as a subsequent therapy for patients with advanced biliary tract disease, demonstrated an ORR of 9.7% (95% CI, 2.0–25.8%), with a median PFS of 6.1 months.<sup>779</sup> The panel voted to include the combination of lenvatinib and pembrolizumab as a category 2B subsequent-line treatment option “useful in certain circumstances” for patients with unresectable or metastatic progressive disease who have not been previously treated with a checkpoint inhibitor.

In a retrospective review of eight patients with advanced gallbladder cancer and *HER2/neu* gene amplification or overexpression, five of the eight patients who received *HER2/neu*-directed therapy (trastuzumab) experienced a PR or CR. No response was seen in five patients with cholangiocarcinoma who also received *HER2/neu*-directed therapy.<sup>780</sup> Phase II studies are currently ongoing to investigate *HER2*-directed treatment options for solid tumors (eg, NCT02465060, NCT02693535). In a published abstract, pralsetinib, a selective RET inhibitor, demonstrated an ORR of 50% (95% CI, 21%–79%) in patients with *RET* fusion-positive tumors other than non-small cell lung cancer and thyroid.<sup>781</sup> A response was observed in the two patients who had cholangiocarcinoma. However, *RET* mutations in cholangiocarcinoma are rare.<sup>782</sup>

In a phase II trial, regorafenib was found to have a disease control rate of 56% and could thus be useful in patients with disease refractory to chemotherapy.<sup>783</sup> Another phase II trial reported an ORR of 9.1% and a disease control rate of 64%.<sup>784</sup> In the phase II REACHIN trial, patients with biliary tract cancers were randomized to receive best supportive care along with either regorafenib or placebo.<sup>785</sup> The median PFS for patients in the regorafenib arm was 3.0 months compared to 1.5 months for those in the placebo arm. The median OS was 5.3 months for the regorafenib group compared to 5.1 months for the placebo group. The panel voted to include regorafenib as a category 2B subsequent-line treatment option (“other recommended regimen”) for unresectable or metastatic progressive disease.

## Summary

Hepatobiliary cancers are associated with a poor prognosis. Many patients with HCC are diagnosed at an advanced stage, and patients with biliary tract cancers commonly present with advanced disease. In the past few years, several advances have been made in the therapeutic approaches for patients with hepatobiliary cancers.

Complete resection of the tumor in well-selected patients is currently the best available potentially curative treatment. Liver transplantation is a curative option for select resectable patients. Bridge therapy can be considered for patients with HCC to decrease tumor progression and the dropout rate from the liver transplantation waiting list.

Locoregional therapies (ablation, arterially directed therapies, and RT) are often the initial approach for patients with HCC who are not candidates for surgery or liver transplantation. Ablation should be considered as definitive treatment in the context of a multidisciplinary review in well-selected patients with small properly located tumors. Arterially directed therapies (TACE, DEB-TACE, or TARE with Y-90 microspheres) are appropriate for



patients with unresectable or inoperable tumors that are not amenable to ablation therapy. SBRT can be considered as an alternative to ablation and/or embolization techniques (especially for patients with 1–3 tumors and minimal or no extrahepatic disease) or when these therapies have failed or are contraindicated. Though it is currently rarely used, there are emerging data supporting its usefulness. PBT may also be used in select settings. Locoregional therapy is also included as an option for patients with unresectable or metastatic intrahepatic cholangiocarcinoma. RT with EBRT and SBRT may be used in patients with unresectable gallbladder cancer or extrahepatic cholangiocarcinoma, though there is little evidence to support this treatment option without concurrent chemotherapy and in patients with unresected disease.

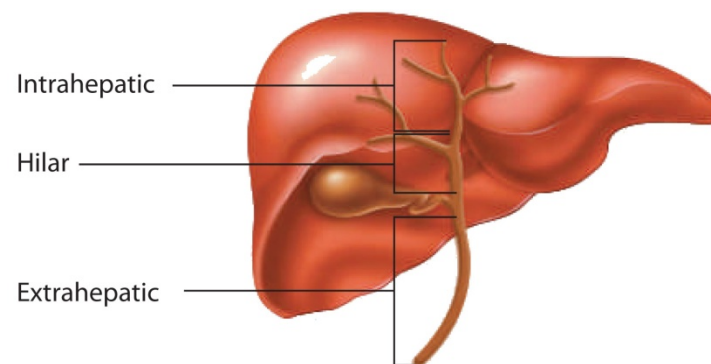
The combination of atezolizumab and bevacizumab is now the preferred first-line option for patients with HCC. Lenvatinib and sorafenib are listed as other recommended first-line options. A number of agents have recently been added to the NCCN Guidelines for subsequent-line therapy for patients with disease progression. These options include regorafenib, cabozantinib, ramucirumab, nivolumab, combined nivolumab and ipilimumab, pembrolizumab, and dostarlimab-gxly. The results of the randomized phase III ABC-02 study demonstrated a survival advantage for the combination of gemcitabine and cisplatin over gemcitabine alone in patients with advanced or metastatic biliary tract cancers. The combination of gemcitabine and cisplatin is included as a category 1 recommendation for this group of patients. Drugs such as entrectinib, larotrectinib, pembrolizumab, dostarlimab-gxly pemigatinib, infigratinib, ivosidenib, and combined dabrafenib and trametinib may benefit certain patients with specific genomic mutations.

It is essential that all patients be evaluated by a multidisciplinary team prior to initiation of treatment. Careful patient selection for treatment and patient engagement are essential. There are relatively few high-quality

RCTs of patients with hepatobiliary cancers, and patient participation in prospective clinical trials is the preferred option for the treatment of patients with all stages of disease.



**Figure 1: Classification of Cholangiocarcinoma**



Reproduced with permission from Patel T. Cholangiocarcinoma. Nat Clin Pract Gastroenterol Hepatol 2006;3:33-42.



## References

1. Siegel RL, Miller KD, Jemal A. Cancer statistics, 2020. *CA Cancer J Clin* 2020;70:7-30. Available at: <https://www.ncbi.nlm.nih.gov/pubmed/31912902>.
2. Fong ZV, Tanabe KK. The clinical management of hepatocellular carcinoma in the United States, Europe, and Asia: a comprehensive and evidence-based comparison and review. *Cancer* 2014;120:2824-2838. Available at: <http://www.ncbi.nlm.nih.gov/pubmed/24897995>.
3. U.S. National Library of Medicine-Key MEDLINE® Indicators. Available at: [http://www.nlm.nih.gov/bsd/bsd\\_key.html](http://www.nlm.nih.gov/bsd/bsd_key.html). Accessed July 24, 2014.
4. Ryerson AB, Ehemann CR, Altekruse SF, et al. Annual Report to the Nation on the Status of Cancer, 1975-2012, featuring the increasing incidence of liver cancer. *Cancer* 2016;122:1312-1337. Available at: <https://www.ncbi.nlm.nih.gov/pubmed/26959385>.
5. The burden of primary liver cancer and underlying etiologies from 1990 to 2015 at the global, regional, and national level: results from the Global Burden of Disease Study 2015. *JAMA Oncol* 2017;3:1683-1691. Available at: <https://www.ncbi.nlm.nih.gov/pubmed/28983565>.
6. Marrero JA, Kulik LM, Sirlin CB, et al. Diagnosis, staging, and management of hepatocellular carcinoma: 2018 Practice Guidance by the American Association for the Study of Liver Diseases. *Hepatology* 2018;68:723-750. Available at: <https://www.ncbi.nlm.nih.gov/pubmed/29624699>.
7. Islami F, Miller KD, Siegel RL, et al. Disparities in liver cancer occurrence in the United States by race/ethnicity and state. *CA Cancer J Clin* 2017;67:273-289. Available at: <https://www.ncbi.nlm.nih.gov/pubmed/28586094>.
8. Melkonian SC, Jim MA, Reilley B, et al. Incidence of primary liver cancer in American Indians and Alaska Natives, US, 1999-2009. *Cancer Causes Control* 2018;29:833-844. Available at: <https://www.ncbi.nlm.nih.gov/pubmed/30030669>.
9. Petrick JL, Kelly SP, Altekruse SF, et al. Future of hepatocellular carcinoma incidence in the United States forecast through 2030. *J Clin Oncol* 2016;34:1787-1794. Available at: <https://www.ncbi.nlm.nih.gov/pubmed/27044939>.
10. Herbst DA, Reddy KR. Risk factors for hepatocellular carcinoma. *Clin Liver Dis (Hoboken)* 2012;1:180-182. Available at: <https://www.ncbi.nlm.nih.gov/pubmed/31186882>.
11. Janevska D, Chaloska-Ivanova V, Janevski V. Hepatocellular carcinoma: Risk factors, diagnosis and treatment. *Open Access Maced J Med Sci* 2015;3:732-736. Available at: <https://www.ncbi.nlm.nih.gov/pubmed/27275318>.
12. Fattovich G, Stroffolini T, Zagni I, Donato F. Hepatocellular carcinoma in cirrhosis: incidence and risk factors. *Gastroenterology* 2004;127:S35-50. Available at: <http://www.ncbi.nlm.nih.gov/pubmed/15508101>.
13. de Martel C, Maucourt-Boulch D, Plummer M, Franceschi S. World-wide relative contribution of hepatitis B and C viruses in hepatocellular carcinoma. *Hepatology* 2015;62:1190-1200. Available at: <https://www.ncbi.nlm.nih.gov/pubmed/26146815>.
14. Sun J, Althoff KN, Jing Y, et al. Trends in hepatocellular carcinoma incidence and risk among persons with HIV in the US and Canada, 1996-2015. *JAMA Netw Open* 2021;4:e2037512. Available at: <https://www.ncbi.nlm.nih.gov/pubmed/33595662>.
15. Ganne-Carrie N, Nahon P. Hepatocellular carcinoma in the setting of alcohol-related liver disease. *J Hepatol* 2019;70:284-293. Available at: <https://www.ncbi.nlm.nih.gov/pubmed/30658729>.
16. Kanwal F, Kramer JR, Mapakshi S, et al. Risk of hepatocellular cancer in patients with non-alcoholic fatty liver disease. *Gastroenterology* 2018;155:1828-1837 e1822. Available at: <https://www.ncbi.nlm.nih.gov/pubmed/30144434>.
17. Ascha MS, Hanounieh IA, Lopez R, et al. The incidence and risk factors of hepatocellular carcinoma in patients with nonalcoholic



steatohepatitis. *Hepatology* 2010;51:1972-1978. Available at: <http://www.ncbi.nlm.nih.gov/pubmed/20209604>.

18. ElMBERG M, Hultcrantz R, EkBOM A, et al. Cancer risk in patients with hereditary hemochromatosis and in their first-degree relatives. *Gastroenterology* 2003;125:1733-1741. Available at: <https://www.ncbi.nlm.nih.gov/pubmed/14724826>.

19. Di Bisceglie AM, Lyra AC, Schwartz M, et al. Hepatitis C-related hepatocellular carcinoma in the United States: influence of ethnic status. *Am J Gastroenterol* 2003;98:2060-2063. Available at: <http://www.ncbi.nlm.nih.gov/pubmed/14499788>.

20. Chen CJ, Yu MW, Liaw YF. Epidemiological characteristics and risk factors of hepatocellular carcinoma. *J Gastroenterol Hepatol* 1997;12:S294-308. Available at: <http://www.ncbi.nlm.nih.gov/pubmed/9407350>.

21. Yang HI, Lu SN, Liaw YF, et al. Hepatitis B e antigen and the risk of hepatocellular carcinoma. *N Engl J Med* 2002;347:168-174. Available at: <http://www.ncbi.nlm.nih.gov/pubmed/12124405>.

22. Chen G, Lin W, Shen F, et al. Past HBV viral load as predictor of mortality and morbidity from HCC and chronic liver disease in a prospective study. *Am J Gastroenterol* 2006;101:1797-1803. Available at: <http://www.ncbi.nlm.nih.gov/pubmed/16817842>.

23. Chen CJ, Yang HI, Su J, et al. Risk of hepatocellular carcinoma across a biological gradient of serum hepatitis B virus DNA level. *JAMA* 2006;295:65-73. Available at: <http://www.ncbi.nlm.nih.gov/pubmed/16391218>.

24. Lee MH, Yang HI, Lu SN, et al. Hepatitis C virus seromarkers and subsequent risk of hepatocellular carcinoma: long-term predictors from a community-based cohort study. *J Clin Oncol* 2010;28:4587-4593. Available at: <http://www.ncbi.nlm.nih.gov/pubmed/20855826>.

25. Ishiguro S, Inoue M, Tanaka Y, et al. Impact of viral load of hepatitis C on the incidence of hepatocellular carcinoma: A population-based cohort

study (JPHC Study). *Cancer Lett* 2011;300:173-179. Available at: <http://www.ncbi.nlm.nih.gov/pubmed/21035947>.

26. Alter MJ. The epidemiology of acute and chronic hepatitis C. *Clin Liver Dis* 1997;1:559-568. Available at: <http://www.ncbi.nlm.nih.gov/pubmed/15560058>.

27. Ryder SD, Irving WL, Jones DA, et al. Progression of hepatic fibrosis in patients with hepatitis C: a prospective repeat liver biopsy study. *Gut* 2004;53:451-455. Available at: <http://www.ncbi.nlm.nih.gov/pubmed/14960533>.

28. Falade-Nwulia O, Suarez-Cuervo C, Nelson DR, et al. Oral direct-acting agent therapy for hepatitis C virus infection: a systematic review. *Ann Intern Med* 2017;166:637-648. Available at: <https://www.ncbi.nlm.nih.gov/pubmed/28319996>.

29. Suwanthawornkul T, Anothaisintawee T, Sobhonslidsuk A, et al. Efficacy of second generation direct-acting antiviral agents for treatment naive hepatitis C genotype 1: a systematic review and network meta-analysis. *PLoS One* 2015;10:e0145953. Available at: <https://www.ncbi.nlm.nih.gov/pubmed/26720298>.

30. Ogata F, Kobayashi M, Akuta N, et al. Outcome of all-oral direct-acting antiviral regimens on the rate of development of hepatocellular carcinoma in patients with hepatitis C virus genotype 1-related chronic liver disease. *Oncology* 2017. Available at: <https://www.ncbi.nlm.nih.gov/pubmed/28448999>.

31. Carrat F, Fontaine H, Dorival C, et al. Clinical outcomes in patients with chronic hepatitis C after direct-acting antiviral treatment: a prospective cohort study. *Lancet* 2019;393:1453-1464. Available at: <https://www.ncbi.nlm.nih.gov/pubmed/30765123>.

32. Lavanchy D. Worldwide epidemiology of HBV infection, disease burden, and vaccine prevention. *J Clin Virol* 2005;34 Suppl 1:1-3. Available at: <http://www.ncbi.nlm.nih.gov/pubmed/16461208>.





33. Goldstein ST, Zhou F, Hadler SC, et al. A mathematical model to estimate global hepatitis B disease burden and vaccination impact. *Int J Epidemiol* 2005;34:1329-1339. Available at: <http://www.ncbi.nlm.nih.gov/pubmed/16249217>.

34. Beasley RP, Hwang LY, Lin CC, Chien CS. Hepatocellular carcinoma and hepatitis B virus. A prospective study of 22 707 men in Taiwan. *Lancet* 1981;2:1129-1133. Available at: <http://www.ncbi.nlm.nih.gov/pubmed/6118576>.

35. Bruix J, Sherman M. Management of hepatocellular carcinoma: An update. *AASLD Practice Guidelines*; 2010. Available at: <http://www.aasld.org/practiceguidelines/Documents/HCCUpdate2010.pdf>.

36. Thiele M, Gluud LL, Fialla AD, et al. Large variations in risk of hepatocellular carcinoma and mortality in treatment naive hepatitis B patients: systematic review with meta-analyses. *PLoS One* 2014;9:e107177. Available at: <http://www.ncbi.nlm.nih.gov/pubmed/25225801>.

37. Kim WR, Loomba R, Berg T, et al. Impact of long-term tenofovir disoproxil fumarate on incidence of hepatocellular carcinoma in patients with chronic hepatitis B. *Cancer* 2015;121:3631-3638. Available at: <https://www.ncbi.nlm.nih.gov/pubmed/26177866>.

38. Chang MH, You SL, Chen CJ, et al. Decreased incidence of hepatocellular carcinoma in hepatitis B vaccinees: a 20-year follow-up study. *J Natl Cancer Inst* 2009;101:1348-1355. Available at: <https://www.ncbi.nlm.nih.gov/pubmed/19759364>.

39. Chang MH, You SL, Chen CJ, et al. Long-term effects of hepatitis B immunization of infants in preventing liver cancer. *Gastroenterology* 2016;151:472-480.e471. Available at: <https://www.ncbi.nlm.nih.gov/pubmed/27269245>.

40. McMahon BJ, Bulkow LR, Singleton RJ, et al. Elimination of hepatocellular carcinoma and acute hepatitis B in children 25 years after a hepatitis B newborn and catch-up immunization program. *Hepatology*

2011;54:801-807. Available at: <https://www.ncbi.nlm.nih.gov/pubmed/21618565>.

41. Blonski W, Kotlyar DS, Forde KA. Non-viral causes of hepatocellular carcinoma. *World J Gastroenterol* 2010;16:3603-3615. Available at: <http://www.ncbi.nlm.nih.gov/pubmed/20677332>.

42. Asare GA, Bronz M, Naidoo V, Kew MC. Synergistic interaction between excess hepatic iron and alcohol ingestion in hepatic mutagenesis. *Toxicology* 2008;254:11-18. Available at: <http://www.ncbi.nlm.nih.gov/pubmed/18852013>.

43. Singal AK, Anand BS. Mechanisms of synergy between alcohol and hepatitis C virus. *J Clin Gastroenterol* 2007;41:761-772. Available at: <http://www.ncbi.nlm.nih.gov/pubmed/17700425>.

44. Volk ML, Marrero JA. Early detection of liver cancer: diagnosis and management. *Curr Gastroenterol Rep* 2008;10:60-66. Available at: <http://www.ncbi.nlm.nih.gov/pubmed/18417044>.

45. Lok AS, McMahon BJ. Chronic hepatitis B: update 2009. *AASLD Practice Guidelines* (ed 2009/08/29); 2009. Available at: <http://www.aasld.org/practiceguidelines/Pages/SortablePracticeGuidelinesAlpha.aspx>.

46. Terrault NA, Bzowej NH, Chang KM, et al. AASLD guidelines for treatment of chronic hepatitis B. *Hepatology* 2016;63:261-283. Available at: <http://www.ncbi.nlm.nih.gov/pubmed/26566064>.

47. Beaton MD, Adams PC. Prognostic factors and survival in patients with hereditary hemochromatosis and cirrhosis. *Can J Gastroenterol* 2006;20:257-260. Available at: <http://www.ncbi.nlm.nih.gov/pubmed/16609753>.

48. Yeoman AD, Al-Chalabi T, Karani JB, et al. Evaluation of risk factors in the development of hepatocellular carcinoma in autoimmune hepatitis: Implications for follow-up and screening. *Hepatology* 2008;48:863-870. Available at: <http://www.ncbi.nlm.nih.gov/pubmed/18752332>.



49. Tansel A, Katz LH, El-Serag HB, et al. Incidence and determinants of hepatocellular carcinoma in autoimmune hepatitis: a systematic review and meta-analysis. *Clin Gastroenterol Hepatol* 2017;15:1207-1217 e1204. Available at: <https://www.ncbi.nlm.nih.gov/pubmed/28215616>.

50. Gomaa AI, Khan SA, Toledano MB, et al. Hepatocellular carcinoma: epidemiology, risk factors and pathogenesis. *World J Gastroenterol* 2008;14:4300-4308. Available at: <https://www.ncbi.nlm.nih.gov/pubmed/18666317>.

51. Arnaoutakis DJ, Mavros MN, Shen F, et al. Recurrence patterns and prognostic factors in patients with hepatocellular carcinoma in noncirrhotic liver: a multi-institutional analysis. *Ann Surg Oncol* 2014;21:147-154. Available at: <https://www.ncbi.nlm.nih.gov/pubmed/23959056>.

52. Makarova-Rusher OV, Altekruse SF, McNeel TS, et al. Population attributable fractions of risk factors for hepatocellular carcinoma in the United States. *Cancer* 2016;122:1757-1765. Available at: <https://www.ncbi.nlm.nih.gov/pubmed/26998818>.

53. Pearson-Stuttard J, Zhou B, Kontis V, et al. Worldwide burden of cancer attributable to diabetes and high body-mass index: a comparative risk assessment. *Lancet Diabetes Endocrinol* 2018;6:95-104. Available at: <https://www.ncbi.nlm.nih.gov/pubmed/29195904>.

54. Alexander M, Loomis AK, van der Lei J, et al. Risks and clinical predictors of cirrhosis and hepatocellular carcinoma diagnoses in adults with diagnosed NAFLD: real-world study of 18 million patients in four European cohorts. *BMC Med* 2019;17:95. Available at: <https://www.ncbi.nlm.nih.gov/pubmed/31104631>.

55. Marchesini G, Bugianesi E, Forlani G, et al. Nonalcoholic fatty liver, steatohepatitis, and the metabolic syndrome. *Hepatology* 2003;37:917-923. Available at: <http://www.ncbi.nlm.nih.gov/pubmed/12668987>.

56. Takamatsu S, Noguchi N, Kudoh A, et al. Influence of risk factors for metabolic syndrome and non-alcoholic fatty liver disease on the progression and prognosis of hepatocellular carcinoma.

*Hepatology* 2008;55:609-614. Available at: <http://www.ncbi.nlm.nih.gov/pubmed/18613418>.

57. Kim NG, Nguyen PP, Dang H, et al. Temporal trends in disease presentation and survival of patients with hepatocellular carcinoma: A real-world experience from 1998 to 2015. *Cancer* 2018;124:2588-2598. Available at: <https://www.ncbi.nlm.nih.gov/pubmed/29624631>.

58. Younossi ZM. Review article: current management of non-alcoholic fatty liver disease and non-alcoholic steatohepatitis. *Aliment Pharmacol Ther* 2008;28:2-12. Available at: <http://www.ncbi.nlm.nih.gov/pubmed/18410557>.

59. White DL, Kanwal F, El-Serag HB. Association between nonalcoholic fatty liver disease and risk for hepatocellular cancer, based on systematic review. *Clin Gastroenterol Hepatol* 2012;10:1342-1359 e1342. Available at: <http://www.ncbi.nlm.nih.gov/pubmed/23041539>.

60. Sanyal AJ, Banas C, Sargeant C, et al. Similarities and differences in outcomes of cirrhosis due to nonalcoholic steatohepatitis and hepatitis C. *Hepatology* 2006;43:682-689. Available at: <http://www.ncbi.nlm.nih.gov/pubmed/16502396>.

61. Yatsuji S, Hashimoto E, Tobari M, et al. Clinical features and outcomes of cirrhosis due to non-alcoholic steatohepatitis compared with cirrhosis caused by chronic hepatitis C. *J Gastroenterol Hepatol* 2009;24:248-254. Available at: <http://www.ncbi.nlm.nih.gov/pubmed/19032450>.

62. Loomba R, Lim JK, Patton H, El-Serag HB. AGA clinical practice update on screening and surveillance for hepatocellular carcinoma in patients with nonalcoholic fatty liver disease: Expert review. *Gastroenterology* 2020;158:1822-1830. Available at: <https://www.ncbi.nlm.nih.gov/pubmed/32006545>.

63. El-Serag HB, Davila JA. Is fibrolamellar carcinoma different from hepatocellular carcinoma? A US population-based study. *Hepatology* 2004;39:798-803. Available at: <https://www.ncbi.nlm.nih.gov/pubmed/14999699>.



64. Stipa F, Yoon SS, Liao KH, et al. Outcome of patients with fibrolamellar hepatocellular carcinoma. *Cancer* 2006;106:1331-1338. Available at: <https://www.ncbi.nlm.nih.gov/pubmed/16475212>.

65. Mayo SC, Mavros MN, Nathan H, et al. Treatment and prognosis of patients with fibrolamellar hepatocellular carcinoma: a national perspective. *J Am Coll Surg* 2014;218:196-205. Available at: <https://www.ncbi.nlm.nih.gov/pubmed/24315886>.

66. Groeschl RT, Miura JT, Wong RK, et al. Multi-institutional analysis of recurrence and survival after hepatectomy for fibrolamellar carcinoma. *J Surg Oncol* 2014;110:412-415. Available at: <https://www.ncbi.nlm.nih.gov/pubmed/24844420>.

67. Lafaro KJ, Pawlik TM. Fibrolamellar hepatocellular carcinoma: current clinical perspectives. *J Hepatocell Carcinoma* 2015;2:151-157. Available at: <https://www.ncbi.nlm.nih.gov/pubmed/27508204>.

68. Honeyman JN, Simon EP, Robine N, et al. Detection of a recurrent DNAJB1-PRKACA chimeric transcript in fibrolamellar hepatocellular carcinoma. *Science* 2014;343:1010-1014. Available at: <https://www.ncbi.nlm.nih.gov/pubmed/24578576>.

69. Cornella H, Alsinet C, Sayols S, et al. Unique genomic profile of fibrolamellar hepatocellular carcinoma. *Gastroenterology* 2015;148:806-818.e810. Available at: <https://www.ncbi.nlm.nih.gov/pubmed/25557953>.

70. Darcy DG, Chiaroni-Clarke R, Murphy JM, et al. The genomic landscape of fibrolamellar hepatocellular carcinoma: whole genome sequencing of ten patients. *Oncotarget* 2015;6:755-770. Available at: <https://www.ncbi.nlm.nih.gov/pubmed/25605237>.

71. Graham RP, Jin L, Knutson DL, et al. DNAJB1-PRKACA is specific for fibrolamellar carcinoma. *Mod Pathol* 2015;28:822-829. Available at: <https://www.ncbi.nlm.nih.gov/pubmed/25698061>.

72. Abou-Alfa GK, Mayer RJ, Cosgrove D, et al. Randomized phase II study of everolimus (E), leuprolide + letrozole (LL), and E + LL (ELL) in patients (pts) with unresectable fibrolamellar carcinoma (FLC). *J Clin*

*Oncol* 2015;33:e15149. Available at: [https://ascopubs.org/doi/abs/10.1200/jco.2015.33.15\\_suppl.e15149](https://ascopubs.org/doi/abs/10.1200/jco.2015.33.15_suppl.e15149).

73. Heimbach JK, Kulik LM, Finn RS, et al. AASLD guidelines for the treatment of hepatocellular carcinoma. *Hepatology* 2018;67:358-380. Available at: <https://www.ncbi.nlm.nih.gov/pubmed/28130846>.

74. EASL-EORTC clinical practice guidelines: management of hepatocellular carcinoma. *J Hepatol* 2012;56:908-943. Available at: <https://www.ncbi.nlm.nih.gov/pubmed/22424438>.

75. Zhang B-H, Yang B-H, Tang Z-Y. Randomized controlled trial of screening for hepatocellular carcinoma. *J Cancer Res Clin Oncol* 2004;130:417-422. Available at: <http://www.ncbi.nlm.nih.gov/pubmed/15042359>.

76. Chang P-E, Ong W-C, Lui H-F, Tan C-K. Is the prognosis of young patients with hepatocellular carcinoma poorer than the prognosis of older patients? A comparative analysis of clinical characteristics, prognostic features, and survival outcome. *J Gastroenterol* 2008;43:881-888. Available at: <http://www.ncbi.nlm.nih.gov/pubmed/19012042>.

77. El-Serag HB, Marrero JA, Rudolph L, Reddy KR. Diagnosis and treatment of hepatocellular carcinoma. *Gastroenterology* 2008;134:1752-1763. Available at: <http://www.ncbi.nlm.nih.gov/pubmed/18471552>.

78. Waidely E, Al-Yuobi AR, Bashammakh AS, et al. Serum protein biomarkers relevant to hepatocellular carcinoma and their detection. *Analyst* 2016;141:36-44. Available at: <https://www.ncbi.nlm.nih.gov/pubmed/26606739>.

79. Zhang B, Yang B. Combined alpha fetoprotein testing and ultrasonography as a screening test for primary liver cancer. *J Med Screen* 1999;6:108-110. Available at: <http://www.ncbi.nlm.nih.gov/pubmed/10444731>.

80. Tong MJ, Rosinski AA, Huynh CT, et al. Long-term survival after surveillance and treatment in patients with chronic viral hepatitis and



# NCCN Guidelines Version 5.2021

## Hepatobiliary Cancers

hepatocellular carcinoma. *Hepatol Commun* 2017;1:595-608. Available at: <https://www.ncbi.nlm.nih.gov/pubmed/29404481>.

81. Pathologic diagnosis of early hepatocellular carcinoma: a report of the international consensus group for hepatocellular neoplasia. *Hepatology* 2009;49:658-664. Available at: <http://www.ncbi.nlm.nih.gov/pubmed/19177576>.

82. Lok AS, Sterling RK, Everhart JE, et al. Des-gamma-carboxy prothrombin and alpha-fetoprotein as biomarkers for the early detection of hepatocellular carcinoma. *Gastroenterology* 2010;138:493-502. Available at: <http://www.ncbi.nlm.nih.gov/pubmed/19852963>.

83. Tangkijvanich P, Anukulkarnkusol N, Suwangool P, et al. Clinical characteristics and prognosis of hepatocellular carcinoma: analysis based on serum alpha-fetoprotein levels. *J Clin Gastroenterol* 2000;31:302-308. Available at: <http://www.ncbi.nlm.nih.gov/pubmed/11129271>.

84. Tzartzeva K, Obi J, Rich NE, et al. Surveillance imaging and alpha fetoprotein for early detection of hepatocellular carcinoma in patients with cirrhosis: a meta-analysis. *Gastroenterology* 2018;154:1706-1718. Available at: <https://www.ncbi.nlm.nih.gov/pubmed/29425931>.

85. Arrieta O, Cacho B, Morales-Espinosa D, et al. The progressive elevation of alpha fetoprotein for the diagnosis of hepatocellular carcinoma in patients with liver cirrhosis. *BMC Cancer* 2007;7:28. Available at: <https://www.ncbi.nlm.nih.gov/pubmed/17288606>.

86. Schiff ER, Sorrell MF, Maddrey WC. *Schiff's Diseases of the Liver*. Philadelphia: Lippincott Williams & Wilkins (LWW); 2007.

87. Liver imaging reporting and data system version 2017. 2018. Available at: <http://www.acr.org/quality-safety/resources/LIRADS>. Accessed April 2, 2019.

88. Luo JC, Hwang SJ, Wu JC, et al. Clinical characteristics and prognosis of hepatocellular carcinoma patients with paraneoplastic syndromes. *Hepatogastroenterology* 2002;49:1315-1319. Available at: <http://www.ncbi.nlm.nih.gov/pubmed/12239934>.

89. Gera S, Ettel M, Acosta-Gonzalez G, Xu R. Clinical features, histology, and histogenesis of combined hepatocellular-cholangiocarcinoma. *World J Hepatol* 2017;9:300-309. Available at: <https://www.ncbi.nlm.nih.gov/pubmed/28293379>.

90. O'Connor K, Walsh JC, Schaeffer DF. Combined hepatocellular-cholangiocarcinoma (cHCC-CC): a distinct entity. *Ann Hepatol* 2014;13:317-322. Available at: <https://www.ncbi.nlm.nih.gov/pubmed/24756005>.

91. Li DB, Si XY, Wang SJ, Zhou YM. Long-term outcomes of combined hepatocellular-cholangiocarcinoma after hepatectomy or liver transplantation: A systematic review and meta-analysis. *Hepatobiliary Pancreat Dis Int* 2019;18:12-18. Available at: <https://www.ncbi.nlm.nih.gov/pubmed/30442549>.

92. Li R, Yang D, Tang CL, et al. Combined hepatocellular carcinoma and cholangiocarcinoma (biphenotypic) tumors: clinical characteristics, imaging features of contrast-enhanced ultrasound and computed tomography. *BMC Cancer* 2016;16:158. Available at: <https://www.ncbi.nlm.nih.gov/pubmed/26917546>.

93. Kassahun WT, Hauss J. Management of combined hepatocellular and cholangiocarcinoma. *Int J Clin Pract* 2008;62:1271-1278. Available at: <https://www.ncbi.nlm.nih.gov/pubmed/18284443>.

94. Yano Y, Yamamoto J, Kosuge T, et al. Combined hepatocellular and cholangiocarcinoma: a clinicopathologic study of 26 resected cases. *Jpn J Clin Oncol* 2003;33:283-287. Available at: <https://www.ncbi.nlm.nih.gov/pubmed/12913082>.

95. Yin X, Zhang BH, Qiu SJ, et al. Combined hepatocellular carcinoma and cholangiocarcinoma: clinical features, treatment modalities, and prognosis. *Ann Surg Oncol* 2012;19:2869-2876. Available at: <https://www.ncbi.nlm.nih.gov/pubmed/22451237>.

96. Breedis C, Young G. The blood supply of neoplasms in the liver. *Am J Pathol* 1954;30:969-977. Available at: <http://www.ncbi.nlm.nih.gov/pubmed/13197542>.





97. Marrero JA, Hussain HK, Nghiem HV, et al. Improving the prediction of hepatocellular carcinoma in cirrhotic patients with an arterially-enhancing liver mass. *Liver Transpl* 2005;11:281-289. Available at: <http://www.ncbi.nlm.nih.gov/pubmed/15719410>.
98. Miller G, Schwartz LH, D'Angelica M. The use of imaging in the diagnosis and staging of hepatobiliary malignancies. *Surg Oncol Clin N Am* 2007;16:343-368. Available at: <http://www.ncbi.nlm.nih.gov/pubmed/17560517>.
99. Forner A, Vilana R, Ayuso C, et al. Diagnosis of hepatic nodules 20 mm or smaller in cirrhosis: Prospective validation of the noninvasive diagnostic criteria for hepatocellular carcinoma. *Hepatology* 2008;47:97-9104. Available at: <http://www.ncbi.nlm.nih.gov/pubmed/18069697>.
100. Choi JY, Lee JM, Sirlin CB. CT and MR imaging diagnosis and staging of hepatocellular carcinoma: part II. Extracellular agents, hepatobiliary agents, and ancillary imaging features. *Radiology* 2014;273:30-50. Available at: <https://www.ncbi.nlm.nih.gov/pubmed/25247563>.
101. Tang A, Bashir MR, Corwin MT, et al. Evidence supporting LI-RADS major features for CT- and MR imaging-based diagnosis of hepatocellular carcinoma: a systematic review. *Radiology* 2018;286:29-48. Available at: <https://www.ncbi.nlm.nih.gov/pubmed/29166245>.
102. Claudon M, Dietrich CF, Choi BI, et al. Guidelines and good clinical practice recommendations for contrast enhanced ultrasound (CEUS) in the liver - update 2012: A WFUMB-EFSUMB initiative in cooperation with representatives of AFSUMB, AIUM, ASUM, FLAUS and ICUS. *Ultrasound Med Biol* 2013;39:187-210. Available at: <https://www.ncbi.nlm.nih.gov/pubmed/23137926>.
103. Chou R, Cuevas C, Fu R, et al. Imaging techniques for the diagnosis of hepatocellular carcinoma: a systematic review and meta-analysis. *Ann Intern Med* 2015;162:697-711. Available at: <https://www.ncbi.nlm.nih.gov/pubmed/25984845>.
104. Colli A, Fraquelli M, Casazza G, et al. Accuracy of ultrasonography, spiral CT, magnetic resonance, and alpha-fetoprotein in diagnosing hepatocellular carcinoma: a systematic review. *Am J Gastroenterol* 2006;101:513-523. Available at: <https://www.ncbi.nlm.nih.gov/pubmed/16542288>.
105. Sun DW, An L, Wei F, et al. Prognostic significance of parameters from pretreatment (18)F-FDG PET in hepatocellular carcinoma: a meta-analysis. *Abdom Radiol (NY)* 2016;41:33-41. Available at: <https://www.ncbi.nlm.nih.gov/pubmed/26830609>.
106. Lin CY, Chen JH, Liang JA, et al. 18F-FDG PET or PET/CT for detecting extrahepatic metastases or recurrent hepatocellular carcinoma: a systematic review and meta-analysis. *Eur J Radiol* 2012;81:2417-2422. Available at: <https://www.ncbi.nlm.nih.gov/pubmed/21899970>.
107. Park JW, Kim JH, Kim SK, et al. A prospective evaluation of 18F-FDG and 11C-acetate PET/CT for detection of primary and metastatic hepatocellular carcinoma. *J Nucl Med* 2008;49:1912-1921. Available at: <https://www.ncbi.nlm.nih.gov/pubmed/18997056>.
108. Lee YJ, Lee JM, Lee JS, et al. Hepatocellular carcinoma: diagnostic performance of multidetector CT and MR imaging-a systematic review and meta-analysis. *Radiology* 2015;275:97-109. Available at: <http://www.ncbi.nlm.nih.gov/pubmed/25559230>.
109. Roberts LR, Sirlin CB, Zaiem F, et al. Imaging for the diagnosis of hepatocellular carcinoma: A systematic review and meta-analysis. *Hepatology* 2018;67:401-421. Available at: <https://www.ncbi.nlm.nih.gov/pubmed/28859233>.
110. Kierans AS, Kang SK, Rosenkrantz AB. The diagnostic performance of dynamic contrast-enhanced MR imaging for detection of small hepatocellular carcinoma measuring up to 2 cm: a meta-analysis. *Radiology* 2016;278:82-94. Available at: <https://www.ncbi.nlm.nih.gov/pubmed/26098460>.
111. Sangiovanni A, Manini MA, Iavarone M, et al. The diagnostic and economic impact of contrast imaging techniques in the diagnosis of small





hepatocellular carcinoma in cirrhosis. Gut 2010;59:638-644. Available at: <http://www.ncbi.nlm.nih.gov/pubmed/19951909>.

112. Schellhaas B, Wildner D, Pfeifer L, et al. LI-RADS-CEUS - proposal for a contrast-enhanced ultrasound algorithm for the diagnosis of hepatocellular carcinoma in high-risk populations. Ultraschall Med 2016;37:627-634. Available at: <https://www.ncbi.nlm.nih.gov/pubmed/27486793>.

113. Chang TT, Sawhney R, Monto A, et al. Implementation of a multidisciplinary treatment team for hepatocellular cancer at a Veterans Affairs Medical Center improves survival. HPB (Oxford) 2008;10:405-411. Available at: <https://www.ncbi.nlm.nih.gov/pubmed/19088925>.

114. Yopp AC, Mansour JC, Beg MS, et al. Establishment of a multidisciplinary hepatocellular carcinoma clinic is associated with improved clinical outcome. Ann Surg Oncol 2014;21:1287-1295. Available at: <https://www.ncbi.nlm.nih.gov/pubmed/24318095>.

115. Agarwal PD, Phillips P, Hillman L, et al. Multidisciplinary management of hepatocellular carcinoma improves access to therapy and patient survival. J Clin Gastroenterol 2017;51:845-849. Available at: <https://www.ncbi.nlm.nih.gov/pubmed/28877082>.

116. Serper M, Taddei TH, Mehta R, et al. Association of provider specialty and multidisciplinary care with hepatocellular carcinoma treatment and mortality. Gastroenterology 2017;152:1954-1964. Available at: <https://www.ncbi.nlm.nih.gov/pubmed/28283421>.

117. Farinati F, Marino D, De Giorgio M, et al. Diagnostic and prognostic role of alpha-fetoprotein in hepatocellular carcinoma: both or neither? Am J Gastroenterol 2006;101:524-532. Available at: <http://www.ncbi.nlm.nih.gov/pubmed/16542289>.

118. Trevisani F, D'Intino PE, Morselli-Labate AM, et al. Serum alpha-fetoprotein for diagnosis of hepatocellular carcinoma in patients with chronic liver disease: influence of HBsAg and anti-HCV status. J Hepatol 2001;34:570-575. Available at: <http://www.ncbi.nlm.nih.gov/pubmed/11394657>.

119. Gregory JJ, Jr., Finlay JL. Alpha-fetoprotein and beta-human chorionic gonadotropin: their clinical significance as tumour markers. Drugs 1999;57:463-467. Available at: <http://www.ncbi.nlm.nih.gov/pubmed/10235686>.

120. Torzilli G, Minagawa M, Takayama T, et al. Accurate preoperative evaluation of liver mass lesions without fine-needle biopsy. Hepatology 1999;30:889-893. Available at: <http://www.ncbi.nlm.nih.gov/pubmed/10498639>.

121. Levy I, Greig PD, Gallinger S, et al. Resection of hepatocellular carcinoma without preoperative tumor biopsy. Ann Surg 2001;234:206-209. Available at: <http://www.ncbi.nlm.nih.gov/pubmed/11505066>.

122. Lok AS, Lai CL. alpha-Fetoprotein monitoring in Chinese patients with chronic hepatitis B virus infection: role in the early detection of hepatocellular carcinoma. Hepatology 1989;9:110-115. Available at: <http://www.ncbi.nlm.nih.gov/pubmed/2461890>.

123. Bialecki ES, Di Bisceglie AM. Diagnosis of hepatocellular carcinoma. HPB (Oxford) 2005;7:26-34. Available at: <https://www.ncbi.nlm.nih.gov/pubmed/18333158>.

124. Debruyne EN, Delanghe JR. Diagnosing and monitoring hepatocellular carcinoma with alpha-fetoprotein: new aspects and applications. Clin Chim Acta 2008;395:19-26. Available at: <http://www.ncbi.nlm.nih.gov/pubmed/18538135>.

125. Durazo FA, Blatt LM, Corey WG, et al. Des-gamma-carboxyprothrombin, alpha-fetoprotein and AFP-L3 in patients with chronic hepatitis, cirrhosis and hepatocellular carcinoma. J Gastroenterol Hepatol 2008;23:1541-1548. Available at: <http://www.ncbi.nlm.nih.gov/pubmed/18422961>.

126. Marrero JA, Feng Z, Wang Y, et al. Alpha-fetoprotein, des-gamma-carboxyprothrombin, and lectin-bound alpha-fetoprotein in early hepatocellular carcinoma. Gastroenterology 2009;137:110-118. Available at: <http://www.ncbi.nlm.nih.gov/pubmed/19362088>.



# NCCN Guidelines Version 5.2021

## Hepatobiliary Cancers

127. Johnson PJ, Pirrie SJ, Cox TF, et al. The detection of hepatocellular carcinoma using a prospectively developed and validated model based on serological biomarkers. *Cancer Epidemiol Biomarkers Prev* 2014;23:144-153. Available at: <https://www.ncbi.nlm.nih.gov/pubmed/24220911>.

128. Berhane S, Toyoda H, Tada T, et al. Role of the GALAD and BALAD-2 serologic models in diagnosis of hepatocellular carcinoma and prediction of survival in patients. *Clin Gastroenterol Hepatol* 2016;14:875-886 e876. Available at: <https://www.ncbi.nlm.nih.gov/pubmed/26775025>.

129. Yang JD, Addissie BD, Mara KC, et al. GALAD score for hepatocellular carcinoma detection in comparison with liver ultrasound and proposal of GALADUS score. *Cancer Epidemiol Biomarkers Prev* 2019;28:531-538. Available at: <https://www.ncbi.nlm.nih.gov/pubmed/30464023>.

130. Best J, Bechmann LP, Sowa JP, et al. GALAD score detects early hepatocellular carcinoma in an international cohort of patients with nonalcoholic steatohepatitis. *Clin Gastroenterol Hepatol* 2020;18:728-735 e724. Available at: <https://www.ncbi.nlm.nih.gov/pubmed/31712073>.

131. Pomfret EA, Washburn K, Wald C, et al. Report of a national conference on liver allocation in patients with hepatocellular carcinoma in the United States. *Liver Transpl* 2010;16:262-278. Available at: <https://www.ncbi.nlm.nih.gov/pubmed/20209641>.

132. DeLeve LD, Valla DC, Garcia-Tsao G. Vascular disorders of the liver. *Hepatology* 2009;49:1729-1764. Available at: <https://www.ncbi.nlm.nih.gov/pubmed/19399912>.

133. Malaguarnera G, Paladina I, Giordano M, et al. Serum markers of intrahepatic cholangiocarcinoma. *Dis Markers* 2013;34:219-228. Available at: <https://www.ncbi.nlm.nih.gov/pubmed/23396291>.

134. Khan SA, Thomas HC, Davidson BR, Taylor-Robinson SD. Cholangiocarcinoma. *Lancet* 2005;366:1303-1314. Available at: <https://www.ncbi.nlm.nih.gov/pubmed/16214602>.

135. Stewart CJR, Coldewey J, Stewart IS. Comparison of fine needle aspiration cytology and needle core biopsy in the diagnosis of radiologically detected abdominal lesions. *J Clin Pathol* 2002;55:93-97. Available at: <http://www.ncbi.nlm.nih.gov/pubmed/11865001>.

136. Pupulim LF, Felce-Dachez M, Paradis V, et al. Algorithm for immediate cytologic diagnosis of hepatic tumors. *AJR Am J Roentgenol* 2008;190:208-212. Available at: <http://www.ncbi.nlm.nih.gov/pubmed/18287414>.

137. Asmis T, Balaa F, Scully L, et al. Diagnosis and management of hepatocellular carcinoma: results of a consensus meeting of The Ottawa Hospital Cancer Centre. *Curr Oncol* 2010;17:6-12. Available at: <http://www.ncbi.nlm.nih.gov/pubmed/20404972>.

138. Renshaw AA, Haja J, Wilbur DC, Miller TR. Fine-needle aspirates of adenocarcinoma/metastatic carcinoma that resemble hepatocellular carcinoma: correlating cytologic features and performance in the College of American Pathologists Nongynecologic Cytology Program. *Arch Pathol Lab Med* 2005;129:1217-1221. Available at: <http://www.ncbi.nlm.nih.gov/pubmed/16196506>.

139. Pawlik TM, Gleisner AL, Anders RA, et al. Preoperative assessment of hepatocellular carcinoma tumor grade using needle biopsy: implications for transplant eligibility. *Ann Surg* 2007;245:435-442. Available at: <http://www.ncbi.nlm.nih.gov/pubmed/17435551>.

140. Ghany MG, Strader DB, Thomas DL, Seeff LB. Diagnosis, management, and treatment of hepatitis C: an update. *Hepatology* 2009;49:1335-1374. Available at: <http://www.ncbi.nlm.nih.gov/pubmed/19330875>.

141. Katyal S, Oliver JH, Peterson MS, et al. Extrahepatic metastases of hepatocellular carcinoma. *Radiology* 2000;216:698-703. Available at: <http://www.ncbi.nlm.nih.gov/pubmed/10966697>.

142. Natsuizaka M, Omura T, Akaike T, et al. Clinical features of hepatocellular carcinoma with extrahepatic metastases. *J Gastroenterol*



Hepatol 2005;20:1781-1787. Available at:  
<http://www.ncbi.nlm.nih.gov/pubmed/16246200>.

143. Harding JJ, Abu-Zeinah G, Chou JF, et al. Frequency, morbidity, and mortality of bone metastases in advanced hepatocellular carcinoma. J Natl Compr Canc Netw 2018;16:50-58. Available at:  
<https://www.ncbi.nlm.nih.gov/pubmed/29295881>.

144. Dodd GD, 3rd, Baron RL, Oliver JH, 3rd, et al. Enlarged abdominal lymph nodes in end-stage cirrhosis: CT-histopathologic correlation in 507 patients. Radiology 1997;203:127-130. Available at:  
<http://www.ncbi.nlm.nih.gov/pubmed/9122379>.

145. Cooper GS, Bellamy P, Dawson NV, et al. A prognostic model for patients with end-stage liver disease. Gastroenterology 1997;113:1278-1288. Available at: <http://www.ncbi.nlm.nih.gov/pubmed/9322523>.

146. Bruix J, Castells A, Bosch J, et al. Surgical resection of hepatocellular carcinoma in cirrhotic patients: prognostic value of preoperative portal pressure. Gastroenterology 1996;111:1018-1022. Available at:  
<http://www.ncbi.nlm.nih.gov/pubmed/8831597>.

147. Groszmann RJ, Wongcharatrawee S. The hepatic venous pressure gradient: anything worth doing should be done right. Hepatology 2004;39:280-282. Available at:  
<http://www.ncbi.nlm.nih.gov/pubmed/14767976>.

148. Boyer TD. Changing clinical practice with measurements of portal pressure. Hepatology 2004;39:283-285. Available at:  
<http://www.ncbi.nlm.nih.gov/pubmed/14767977>.

149. Thalheimer U, Mela M, Patch D, Burroughs AK. Targeting portal pressure measurements: a critical reappraisal. Hepatology 2004;39:286-290. Available at: <http://www.ncbi.nlm.nih.gov/pubmed/14767978>.

150. Kamath PS, Wiesner RH, Malinchoc M, et al. A model to predict survival in patients with end-stage liver disease. Hepatology 2001;33:464-470. Available at: <http://www.ncbi.nlm.nih.gov/pubmed/11172350>.

151. Malinchoc M, Kamath PS, Gordon FD, et al. A model to predict poor survival in patients undergoing transjugular intrahepatic portosystemic shunts. Hepatology 2000;31:864-871. Available at:  
<http://www.ncbi.nlm.nih.gov/pubmed/10733541>.

152. Martin AP, Bartels M, Hauss J, Fangmann J. Overview of the MELD score and the UNOS adult liver allocation system. Transplant Proc 2007;39:3169-3174. Available at:  
<http://www.ncbi.nlm.nih.gov/pubmed/18089345>.

153. Cholongitas E, Papatheodoridis GV, Vangeli M, et al. Systematic review: The model for end-stage liver disease--should it replace Child-Pugh's classification for assessing prognosis in cirrhosis? Aliment Pharmacol Ther 2005;22:1079-1089. Available at:  
<http://www.ncbi.nlm.nih.gov/pubmed/16305721>.

154. Saxena V, Lai JC. Kidney failure and liver allocation: Current practices and potential improvements. Adv Chronic Kidney Dis 2015;22:391-398. Available at:  
<https://www.ncbi.nlm.nih.gov/pubmed/26311601>.

155. Johnson PJ, Berhane S, Kagebayashi C, et al. Assessment of liver function in patients with hepatocellular carcinoma: a new evidence-based approach-the ALBI grade. J Clin Oncol 2015;33:550-558. Available at:  
<https://www.ncbi.nlm.nih.gov/pubmed/25512453>.

156. Oikonomou T, Goulis L, Doumtsios P, et al. ALBI and PALBI grades are associated with the outcome of patients with stable decompensated cirrhosis. Ann Hepatol 2019;18:126-136. Available at:  
<https://www.ncbi.nlm.nih.gov/pubmed/31113581>.

157. Wan SZ, Nie Y, Zhang Y, et al. Assessing the prognostic performance of the Child-Pugh, Model for End-Stage Liver Disease, and Albumin-Bilirubin scores in patients with decompensated cirrhosis: A large Asian cohort from gastroenterology department. Dis Markers 2020;2020:5193028. Available at:  
<https://www.ncbi.nlm.nih.gov/pubmed/32148566>.



158. Fan ST. Liver functional reserve estimation: state of the art and relevance for local treatments: the Eastern perspective. *J Hepatobiliary Pancreat Sci* 2010;17:380-384. Available at: <http://www.ncbi.nlm.nih.gov/pubmed/19865790>.

159. Fan ST, Lai EC, Lo CM, et al. Hospital mortality of major hepatectomy for hepatocellular carcinoma associated with cirrhosis. *Arch Surg* 1995;130:198-203. Available at: <http://www.ncbi.nlm.nih.gov/pubmed/7848092>.

160. Kudo M, Izumi N, Kokudo N, et al. Management of hepatocellular carcinoma in Japan: Consensus-Based Clinical Practice Guidelines proposed by the Japan Society of Hepatology (JSH) 2010 updated version. *Dig Dis* 2011;29:339-364. Available at: <http://www.ncbi.nlm.nih.gov/pubmed/21829027>.

161. Bruix J, Sherman M, Llovet JM, et al. Clinical management of hepatocellular carcinoma. Conclusions of the Barcelona-2000 EASL conference. European Association for the Study of the Liver. *J Hepatol* 2001;35:421-430. Available at: <http://www.ncbi.nlm.nih.gov/pubmed/11592607>.

162. Dohmen K. Many staging systems for hepatocellular carcinoma: evolution from Child-Pugh, Okuda to SLiDe. *J Gastroenterol Hepatol* 2004;19:1227-1232. Available at: <http://www.ncbi.nlm.nih.gov/pubmed/15482527>.

163. Marrero JA, Fontana RJ, Barrat A, et al. Prognosis of hepatocellular carcinoma: comparison of 7 staging systems in an American cohort. *Hepatology* 2005;41:707-716. Available at: <http://www.ncbi.nlm.nih.gov/pubmed/15795889>.

164. Pugh RN, Murray-Lyon IM, Dawson JL, et al. Transection of the oesophagus for bleeding oesophageal varices. *Br J Surg* 1973;60:646-649. Available at: <http://www.ncbi.nlm.nih.gov/pubmed/4541913>.

165. Amin MB, ed AJCC Cancer Staging Manual. In: Cancer AJCo, ed (ed 8th). Chicago, IL: Springer; 2017.

166. Okuda K, Ohtsuki T, Obata H, et al. Natural history of hepatocellular carcinoma and prognosis in relation to treatment. Study of 850 patients. *Cancer* 1985;56:918-928. Available at: <http://www.ncbi.nlm.nih.gov/pubmed/2990661>.

167. Chevret S, Trinchet JC, Mathieu D, et al. A new prognostic classification for predicting survival in patients with hepatocellular carcinoma. Groupe d'Etude et de Traitement du Carcinome Hepatocellulaire. *J Hepatol* 1999;31:133-141. Available at: <http://www.ncbi.nlm.nih.gov/pubmed/10424293>.

168. Leung TWT, Tang AMY, Zee B, et al. Construction of the Chinese University Prognostic Index for hepatocellular carcinoma and comparison with the TNM staging system, the Okuda staging system, and the Cancer of the Liver Italian Program staging system: a study based on 926 patients. *Cancer* 2002;94:1760-1769. Available at: <http://www.ncbi.nlm.nih.gov/pubmed/11920539>.

169. Kudo M, Chung H, Osaki Y. Prognostic staging system for hepatocellular carcinoma (CLIP score): its value and limitations, and a proposal for a new staging system, the Japan Integrated Staging Score (JIS score). *J Gastroenterol* 2003;38:207-215. Available at: <http://www.ncbi.nlm.nih.gov/pubmed/12673442>.

170. A new prognostic system for hepatocellular carcinoma: a retrospective study of 435 patients: the Cancer of the Liver Italian Program (CLIP) investigators. *Hepatology* 1998;28:751-755. Available at: <http://www.ncbi.nlm.nih.gov/pubmed/9731568>.

171. Llovet JM, Bru C, Bruix J. Prognosis of hepatocellular carcinoma: the BCLC staging classification. *Semin Liver Dis* 1999;19:329-338. Available at: <http://www.ncbi.nlm.nih.gov/pubmed/10518312>.

172. Omagari K, Honda S, Kadokawa Y, et al. Preliminary analysis of a newly proposed prognostic scoring system (SLiDe score) for hepatocellular carcinoma. *J Gastroenterol Hepatol* 2004;19:805-811. Available at: <http://www.ncbi.nlm.nih.gov/pubmed/15209629>.





173. Huo T-I, Lin H-C, Huang Y-H, et al. The model for end-stage liver disease-based Japan Integrated Scoring system may have a better predictive ability for patients with hepatocellular carcinoma undergoing locoregional therapy. *Cancer* 2006;107:141-148. Available at: <http://www.ncbi.nlm.nih.gov/pubmed/16708358>.

174. Limquiac JL, Wong GLH, Wong VWS, et al. Evaluation of model for end stage liver disease (MELD)-based systems as prognostic index for hepatocellular carcinoma. *J Gastroenterol Hepatol* 2009;24:63-69. Available at: <http://www.ncbi.nlm.nih.gov/pubmed/19054256>.

175. Nanashima A, Sumida Y, Abo T, et al. Modified Japan Integrated Staging is currently the best available staging system for hepatocellular carcinoma patients who have undergone hepatectomy. *J Gastroenterol* 2006;41:250-256. Available at: <http://www.ncbi.nlm.nih.gov/pubmed/16699859>.

176. Bruix J, Sherman M. Management of hepatocellular carcinoma. *Hepatology* 2005;42:1208-1236. Available at: <http://www.ncbi.nlm.nih.gov/pubmed/16250051>.

177. Wang J-H, Changchien C-S, Hu T-H, et al. The efficacy of treatment schedules according to Barcelona Clinic Liver Cancer staging for hepatocellular carcinoma - Survival analysis of 3892 patients. *Eur J Cancer* 2008;44:1000-1006. Available at: <http://www.ncbi.nlm.nih.gov/pubmed/18337087>.

178. Kamarajah SK, Frankel TL, Sonnenday C, et al. Critical evaluation of the American Joint Commission on Cancer (AJCC) 8th edition staging system for patients with hepatocellular carcinoma (HCC): A Surveillance, Epidemiology, End Results (SEER) analysis. *J Surg Oncol* 2018;117:644-650. Available at: <https://www.ncbi.nlm.nih.gov/pubmed/29127719>.

179. Vauthey J-N, Ribero D, Abdalla EK, et al. Outcomes of liver transplantation in 490 patients with hepatocellular carcinoma: validation of a uniform staging after surgical treatment. *J Am Coll Surg* 2007;204:1016-1027. Available at: <http://www.ncbi.nlm.nih.gov/pubmed/17481532>.

180. Huitzil-Melendez FD, Capanu M, O'Reilly EM, et al. Advanced hepatocellular carcinoma: which staging systems best predict prognosis? *J Clin Oncol* 2010;28:2889-2895. Available at: <http://www.ncbi.nlm.nih.gov/pubmed/20458042>.

181. Cho YK, Chung JW, Kim JK, et al. Comparison of 7 staging systems for patients with hepatocellular carcinoma undergoing transarterial chemoembolization. *Cancer* 2008;112:352-361. Available at: <http://www.ncbi.nlm.nih.gov/pubmed/18008352>.

182. Collette S, Bonnetain F, Paoletti X, et al. Prognosis of advanced hepatocellular carcinoma: comparison of three staging systems in two French clinical trials. *Ann Oncol* 2008;19:1117-1126. Available at: <http://www.ncbi.nlm.nih.gov/pubmed/18303031>.

183. Cabibbo G, Enea M, Attanasio M, et al. A meta-analysis of survival rates of untreated patients in randomized clinical trials of hepatocellular carcinoma. *Hepatology* 2010;51:1274-1283. Available at: <http://www.ncbi.nlm.nih.gov/pubmed/20112254>.

184. Guglielmi A, Ruzzenente A, Pachera S, et al. Comparison of seven staging systems in cirrhotic patients with hepatocellular carcinoma in a cohort of patients who underwent radiofrequency ablation with complete response. *Am J Gastroenterol* 2008;103:597-604. Available at: <http://www.ncbi.nlm.nih.gov/pubmed/17970836>.

185. Vitale A, Morales RR, Zanusi G, et al. Barcelona Clinic Liver Cancer staging and transplant survival benefit for patients with hepatocellular carcinoma: a multicentre, cohort study. *The Lancet Oncology* 2011;12:654-662. Available at: <http://www.ncbi.nlm.nih.gov/pubmed/21684210>.

186. Cho CS, Gonen M, Shia J, et al. A novel prognostic nomogram is more accurate than conventional staging systems for predicting survival after resection of hepatocellular carcinoma. *J Am Coll Surg* 2008;206:281-291. Available at: <http://www.ncbi.nlm.nih.gov/pubmed/18222381>.





# NCCN Guidelines Version 5.2021

## Hepatobiliary Cancers

187. Nathan H, Schulick RD, Choti MA, Pawlik TM. Predictors of survival after resection of early hepatocellular carcinoma. *Ann Surg* 2009;249:799-805. Available at: <http://www.ncbi.nlm.nih.gov/pubmed/19387322>.

188. Nathan H, Mentha G, Marques HP, et al. Comparative performances of staging systems for early hepatocellular carcinoma. *HPB (Oxford)* 2009;11:382-390. Available at: <http://www.ncbi.nlm.nih.gov/pubmed/19768142>.

189. Truty MJ, Vauthey J-N. Surgical resection of high-risk hepatocellular carcinoma: patient selection, preoperative considerations, and operative technique. *Ann Surg Oncol* 2010;17:1219-1225. Available at: <http://www.ncbi.nlm.nih.gov/pubmed/20405326>.

190. Pawlik TM, Poon RT, Abdalla EK, et al. Critical appraisal of the clinical and pathologic predictors of survival after resection of large hepatocellular carcinoma. *Arch Surg* 2005;140:450-457. Available at: <http://www.ncbi.nlm.nih.gov/pubmed/15897440>.

191. Chok KS, Ng KK, Poon RT, et al. Impact of postoperative complications on long-term outcome of curative resection for hepatocellular carcinoma. *Br J Surg* 2009;96:81-87. Available at: <http://www.ncbi.nlm.nih.gov/pubmed/19065644>.

192. Kianmanesh R, Regimbeau JM, Belghiti J. Selective approach to major hepatic resection for hepatocellular carcinoma in chronic liver disease. *Surg Oncol Clin N Am* 2003;12:51-63. Available at: <http://www.ncbi.nlm.nih.gov/pubmed/12735129>.

193. Llovet JM, Fuster J, Bruix J. Intention-to-treat analysis of surgical treatment for early hepatocellular carcinoma: resection versus transplantation. *Hepatology* 1999;30:1434-1440. Available at: <http://www.ncbi.nlm.nih.gov/pubmed/10573522>.

194. Poon RT-P, Fan ST, Lo CM, et al. Long-term survival and pattern of recurrence after resection of small hepatocellular carcinoma in patients with preserved liver function: implications for a strategy of salvage transplantation. *Ann Surg* 2002;235:373-382. Available at: <http://www.ncbi.nlm.nih.gov/pubmed/11882759>.

195. Seo DD, Lee HC, Jang MK, et al. Preoperative portal vein embolization and surgical resection in patients with hepatocellular carcinoma and small future liver remnant volume: comparison with transarterial chemoembolization. *Ann Surg Oncol* 2007;14:3501-3509. Available at: <http://www.ncbi.nlm.nih.gov/pubmed/17899289>.

196. Wei AC, Tung-Ping Poon R, Fan ST, Wong J. Risk factors for perioperative morbidity and mortality after extended hepatectomy for hepatocellular carcinoma. *Br J Surg* 2003;90:33-41. Available at: <http://www.ncbi.nlm.nih.gov/pubmed/12520572>.

197. Faber W, Stockmann M, Schirmer C, et al. Significant impact of patient age on outcome after liver resection for HCC in cirrhosis. *Eur J Surg Oncol* 2014;40:208-213. Available at: <https://www.ncbi.nlm.nih.gov/pubmed/24275202>.

198. Ribero D, Curley SA, Imamura H, et al. Selection for resection of hepatocellular carcinoma and surgical strategy: indications for resection, evaluation of liver function, portal vein embolization, and resection. *Ann Surg Oncol* 2008;15:986-992. Available at: <http://www.ncbi.nlm.nih.gov/pubmed/18236112>.

199. Berzigotti A, Reig M, Abraldes JG, et al. Portal hypertension and the outcome of surgery for hepatocellular carcinoma in compensated cirrhosis: a systematic review and meta-analysis. *Hepatology* 2015;61:526-536. Available at: <https://www.ncbi.nlm.nih.gov/pubmed/25212123>.

200. Santambrogio R, Kluger MD, Costa M, et al. Hepatic resection for hepatocellular carcinoma in patients with Child-Pugh's A cirrhosis: is clinical evidence of portal hypertension a contraindication? *HPB (Oxford)* 2013;15:78-84. Available at: <https://www.ncbi.nlm.nih.gov/pubmed/23216782>.

201. Tsai TJ, Chau GY, Lui WY, et al. Clinical significance of microscopic tumor venous invasion in patients with resectable hepatocellular carcinoma. *Surgery* 2000;127:603-608. Available at: <http://www.ncbi.nlm.nih.gov/pubmed/10840353>.



202. Abdalla EK, Denys A, Hasegawa K, et al. Treatment of large and advanced hepatocellular carcinoma. *Ann Surg Oncol* 2008;15:979-985. Available at: <http://www.ncbi.nlm.nih.gov/pubmed/18236115>.

203. Jonas S, Bechstein WO, Steinmuller T, et al. Vascular invasion and histopathologic grading determine outcome after liver transplantation for hepatocellular carcinoma in cirrhosis. *Hepatology* 2001;33:1080-1086. Available at: <http://www.ncbi.nlm.nih.gov/pubmed/11343235>.

204. Vauthey J-N, Lauwers GY, Esnaola NF, et al. Simplified staging for hepatocellular carcinoma. *J Clin Oncol* 2002;20:1527-1536. Available at: <http://www.ncbi.nlm.nih.gov/pubmed/11896101>.

205. Glantzounis GK, Paliouras A, Stylianidi MC, et al. The role of liver resection in the management of intermediate and advanced stage hepatocellular carcinoma. A systematic review. *Eur J Surg Oncol* 2018;44:195-208. Available at: <https://www.ncbi.nlm.nih.gov/pubmed/29258719>.

206. Yamakado K, Nakatsuka A, Takaki H, et al. Early-stage hepatocellular carcinoma: radiofrequency ablation combined with chemoembolization versus hepatectomy. *Radiology* 2008;247:260-266. Available at: <http://www.ncbi.nlm.nih.gov/pubmed/18305190>.

207. Kubota K, Makuuchi M, Kusaka K, et al. Measurement of liver volume and hepatic functional reserve as a guide to decision-making in resectional surgery for hepatic tumors. *Hepatology* 1997;26:1176-1181. Available at: <http://www.ncbi.nlm.nih.gov/pubmed/9362359>.

208. Kishi Y, Abdalla EK, Chun YS, et al. Three hundred and one consecutive extended right hepatectomies: evaluation of outcome based on systematic liver volumetry. *Ann Surg* 2009;250:540-548. Available at: <https://www.ncbi.nlm.nih.gov/pubmed/19730239>.

209. Zorzi D, Laurent A, Pawlik TM, et al. Chemotherapy-associated hepatotoxicity and surgery for colorectal liver metastases. *Br J Surg* 2007;94:274-286. Available at: <https://www.ncbi.nlm.nih.gov/pubmed/17315288>.

210. Glantzounis GK, Tokidis E, Basourakos SP, et al. The role of portal vein embolization in the surgical management of primary hepatobiliary cancers. A systematic review. *Eur J Surg Oncol* 2017;43:32-41. Available at: <https://www.ncbi.nlm.nih.gov/pubmed/27283892>.

211. Brouquet A, Andreou A, Shindoh J, Vauthey J-N. Methods to improve resectability of hepatocellular carcinoma. In: Schlag PM, Senn H-J, eds. *Recent Results in Cancer Research*. Vol. 190: Springer; 2013:57-67.

212. Chapelle T, Op de Beeck B, Roeyen G, et al. Measuring future liver remnant function prior to hepatectomy may guide the indication for portal vein occlusion and avoid posthepatectomy liver failure: a prospective interventional study. *HPB (Oxford)* 2017;19:108-117. Available at: <https://www.ncbi.nlm.nih.gov/pubmed/27956027>.

213. Martel G, Cieslak KP, Huang R, et al. Comparison of techniques for volumetric analysis of the future liver remnant: implications for major hepatic resections. *HPB (Oxford)* 2015;17:1051-1057. Available at: <https://www.ncbi.nlm.nih.gov/pubmed/26373675>.

214. Roayaie S, Jibara G, Tabrizian P, et al. The role of hepatic resection in the treatment of hepatocellular cancer. *Hepatology* 2015;62:440-451. Available at: <https://www.ncbi.nlm.nih.gov/pubmed/25678263>.

215. Bruix J, Takayama T, Mazzaferro V, et al. Adjuvant sorafenib for hepatocellular carcinoma after resection or ablation (STORM): a phase 3, randomised, double-blind, placebo-controlled trial. *Lancet Oncol* 2015;16:1344-1354. Available at: <https://www.ncbi.nlm.nih.gov/pubmed/26361969>.

216. Qi YP, Zhong JH, Liang ZY, et al. Adjuvant transarterial chemoembolization for patients with hepatocellular carcinoma involving microvascular invasion. *Am J Surg* 2019;217:739-744. Available at: <https://www.ncbi.nlm.nih.gov/pubmed/30103903>.

217. Chen ZH, Zhang XP, Zhou TF, et al. Adjuvant transarterial chemoembolization improves survival outcomes in hepatocellular carcinoma with microvascular invasion: A systematic review and meta-



analysis. Eur J Surg Oncol 2019;45:2188-2196. Available at: <https://www.ncbi.nlm.nih.gov/pubmed/31256949>.

218. Yin J, Li N, Han Y, et al. Effect of antiviral treatment with nucleotide/nucleoside analogs on postoperative prognosis of hepatitis B virus-related hepatocellular carcinoma: a two-stage longitudinal clinical study. J Clin Oncol 2013;31:3647-3655. Available at: <http://www.ncbi.nlm.nih.gov/pubmed/24002499>.

219. Huang G, Lau WY, Wang ZG, et al. Antiviral therapy improves postoperative survival in patients with hepatocellular carcinoma: a randomized controlled trial. Ann Surg 2015;261:56-66. Available at: <https://www.ncbi.nlm.nih.gov/pubmed/25072444>.

220. Xu J, Li J, Chen J, Liu ZJ. Effect of adjuvant interferon therapy on hepatitis b/c virus-related hepatocellular carcinoma after curative therapy - meta-analysis. Adv Clin Exp Med 2015;24:331-340. Available at: <http://www.ncbi.nlm.nih.gov/pubmed/25931368>.

221. Xia BW, Zhang YC, Wang J, et al. Efficacy of antiviral therapy with nucleotide/nucleoside analogs after curative treatment for patients with hepatitis B virus-related hepatocellular carcinoma: A systematic review and meta-analysis. Clin Res Hepatol Gastroenterol 2015;39:458-468. Available at: <https://www.ncbi.nlm.nih.gov/pubmed/25650304>.

222. Manthravadi S, Paleti S, Pandya P. Impact of sustained viral response postcurative therapy of hepatitis C-related hepatocellular carcinoma: a systematic review and meta-analysis. Int J Cancer 2017;140:1042-1049. Available at: <https://www.ncbi.nlm.nih.gov/pubmed/27861842>.

223. Reig M, Boix L, Bruix J. The impact of direct antiviral agents on the development and recurrence of hepatocellular carcinoma. Liver Int 2017;37 Suppl 1:136-139. Available at: <https://www.ncbi.nlm.nih.gov/pubmed/28052619>.

224. Torres HA, Shigle TL, Hammoudi N, et al. The oncologic burden of hepatitis C virus infection: A clinical perspective. CA Cancer J Clin 2017. Available at: <https://www.ncbi.nlm.nih.gov/pubmed/28683174>.

225. Conti F, Buonfiglioli F, Scuteri A, et al. Early occurrence and recurrence of hepatocellular carcinoma in HCV-related cirrhosis treated with direct-acting antivirals. J Hepatol 2016;65:727-733. Available at: <https://www.ncbi.nlm.nih.gov/pubmed/27349488>.

226. Furtado R, Crawford M, Sandroussi C. Systematic review and meta-analysis of adjuvant i(131) lipiodol after excision of hepatocellular carcinoma. Ann Surg Oncol 2014;21:2700-2707. Available at: <https://www.ncbi.nlm.nih.gov/pubmed/24743904>.

227. Zhu GQ, Shi KQ, Yu HJ, et al. Optimal adjuvant therapy for resected hepatocellular carcinoma: a systematic review with network meta-analysis. Oncotarget 2015;6:18151-18161. Available at: <https://www.ncbi.nlm.nih.gov/pubmed/26061709>.

228. Lee JH, Lee JH, Lim YS, et al. Adjuvant immunotherapy with autologous cytokine-induced killer cells for hepatocellular carcinoma. Gastroenterology 2015;148:1383-1391.e1386. Available at: <https://www.ncbi.nlm.nih.gov/pubmed/25747273>.

229. Watt KD, Pedersen RA, Kremers WK, et al. Evolution of causes and risk factors for mortality post-liver transplant: results of the NIDDK long-term follow-up study. Am J Transplant 2010;10:1420-1427. Available at: <https://www.ncbi.nlm.nih.gov/pubmed/20486907>.

230. Mazzaferro V, Regalia E, Doci R, et al. Liver transplantation for the treatment of small hepatocellular carcinomas in patients with cirrhosis. N Engl J Med 1996;334:693-699. Available at: <http://www.ncbi.nlm.nih.gov/pubmed/8594428>.

231. Mazzaferro V, Chun YS, Poon RTP, et al. Liver transplantation for hepatocellular carcinoma. Ann Surg Oncol 2008;15:1001-1007. Available at: <http://www.ncbi.nlm.nih.gov/pubmed/18236119>.

232. OPTN/UNOS policy notice modification to hepatocellular carcinoma (HCC) extension criteria. Available at: [https://optn.transplant.hrsa.gov/media/2411/modification-to-hcc-auto-approval-criteria\\_policy-notice.pdf](https://optn.transplant.hrsa.gov/media/2411/modification-to-hcc-auto-approval-criteria_policy-notice.pdf).



233. Cha CH, Ruo L, Fong Y, et al. Resection of hepatocellular carcinoma in patients otherwise eligible for transplantation. *Ann Surg* 2003;238:315-321; discussion 321-313. Available at: <http://www.ncbi.nlm.nih.gov/pubmed/14501497>.

234. Poon RT, Fan ST, Lo CM, et al. Difference in tumor invasiveness in cirrhotic patients with hepatocellular carcinoma fulfilling the Milan criteria treated by resection and transplantation: impact on long-term survival. *Ann Surg* 2007;245:51-58. Available at: <http://www.ncbi.nlm.nih.gov/pubmed/17197965>.

235. Shah SA, Cleary SP, Tan JC, et al. An analysis of resection vs transplantation for early hepatocellular carcinoma: defining the optimal therapy at a single institution. *Ann Surg Oncol* 2007;14:2608-2614. Available at: <http://www.ncbi.nlm.nih.gov/pubmed/17522942>.

236. Facciuto ME, Koneru B, Rocca JP, et al. Surgical treatment of hepatocellular carcinoma beyond Milan criteria. Results of liver resection, salvage transplantation, and primary liver transplantation. *Ann Surg Oncol* 2008;15:1383-1391. Available at: <http://www.ncbi.nlm.nih.gov/pubmed/18320284>.

237. OPTN Policies Effective as of June 8 2020 [Modify HOPE Act Variance Correction]. Available at: [https://optn.transplant.hrsa.gov/media/1200/optn\\_policies.pdf](https://optn.transplant.hrsa.gov/media/1200/optn_policies.pdf).

238. Ioannou GN, Perkins JD, Carithers RL. Liver transplantation for hepatocellular carcinoma: impact of the MELD allocation system and predictors of survival. *Gastroenterology* 2008;134:1342-1351. Available at: <http://www.ncbi.nlm.nih.gov/pubmed/18471511>.

239. Volk ML, Vijan S, Marrero JA. A novel model measuring the harm of transplanting hepatocellular carcinoma exceeding Milan criteria. *Am J Transplant* 2008;8:839-846. Available at: <http://www.ncbi.nlm.nih.gov/pubmed/18318783>.

240. Duffy JP, Vardanian A, Benjamin E, et al. Liver transplantation criteria for hepatocellular carcinoma should be expanded: a 22-year experience

with 467 patients at UCLA. *Ann Surg* 2007;246:502-509. Available at: <http://www.ncbi.nlm.nih.gov/pubmed/17717454>.

241. Yao FY, Ferrell L, Bass NM, et al. Liver transplantation for hepatocellular carcinoma: expansion of the tumor size limits does not adversely impact survival. *Hepatology* 2001;33:1394-1403. Available at: <http://www.ncbi.nlm.nih.gov/pubmed/11391528>.

242. Yao FY, Bass NM, Nikolai B, et al. Liver transplantation for hepatocellular carcinoma: analysis of survival according to the intention-to-treat principle and dropout from the waiting list. *Liver Transpl* 2002;8:873-883. Available at: <http://www.ncbi.nlm.nih.gov/pubmed/12360427>.

243. Volk M, Marrero JA. Liver transplantation for hepatocellular carcinoma: who benefits and who is harmed? *Gastroenterology* 2008;134:1612-1614. Available at: <http://www.ncbi.nlm.nih.gov/pubmed/18471530>.

244. Lee S-G, Hwang S, Moon D-B, et al. Expanded indication criteria of living donor liver transplantation for hepatocellular carcinoma at one large-volume center. *Liver Transpl* 2008;14:935-945. Available at: <http://www.ncbi.nlm.nih.gov/pubmed/18581465>.

245. Wan P, Xia Q, Zhang JJ, et al. Liver transplantation for hepatocellular carcinoma exceeding the Milan criteria: a single-center experience. *J Cancer Res Clin Oncol* 2014;140:341-348. Available at: <http://www.ncbi.nlm.nih.gov/pubmed/24374832>.

246. Duvoux C, Roudot-Thoraval F, Decaens T, et al. Liver transplantation for hepatocellular carcinoma: a model including alpha-fetoprotein improves the performance of Milan criteria. *Gastroenterology* 2012;143:986-994.e983; quiz e914-985. Available at: <https://www.ncbi.nlm.nih.gov/pubmed/22750200>.

247. Notarpaolo A, Layese R, Magistri P, et al. Validation of the AFP model as a predictor of HCC recurrence in patients with viral hepatitis-related cirrhosis who had received a liver transplant for HCC. *J Hepatol* 2017;66:552-559. Available at: <https://www.ncbi.nlm.nih.gov/pubmed/27899297>.





248. Mehta N, Heimbach J, Harnois DM, et al. Validation of a risk estimation of tumor recurrence after transplant (RETREAT) score for hepatocellular carcinoma recurrence after liver transplant. *JAMA Oncol* 2017;3:493-500. Available at: <https://www.ncbi.nlm.nih.gov/pubmed/27838698>.

249. Kim J, Ko ME, Nelson RA, et al. Increasing age and survival after orthotopic liver transplantation for patients with hepatocellular cancer. *J Am Coll Surg* 2014;218:431-438. Available at: <https://www.ncbi.nlm.nih.gov/pubmed/24559955>.

250. Kozyreva ON, Chi D, Clark JW, et al. A multicenter retrospective study on clinical characteristics, treatment patterns, and outcome in elderly patients with hepatocellular carcinoma. *Oncologist* 2011;16:310-318. Available at: <https://www.ncbi.nlm.nih.gov/pubmed/21349948>.

251. Zhao LY, Huo RR, Xiang X, et al. Hepatic resection for elderly patients with hepatocellular carcinoma: a systematic review of more than 17,000 patients. *Expert Rev Gastroenterol Hepatol* 2018;12:1059-1068. Available at: <https://www.ncbi.nlm.nih.gov/pubmed/30145919>.

252. Fujiki M, Aucejo F, Kim R. General overview of neo-adjuvant therapy for hepatocellular carcinoma before liver transplantation: necessity or option? *Liver Int* 2011;31:1081-1089. Available at: <http://www.ncbi.nlm.nih.gov/pubmed/22008644>.

253. Xing M, Sakaria S, Dhanasekaran R, et al. Bridging locoregional therapy prolongs survival in patients listed for liver transplant with hepatocellular carcinoma. *Cardiovasc Intervent Radiol* 2017;40:410-420. Available at: <https://www.ncbi.nlm.nih.gov/pubmed/27900445>.

254. Llovet JM, Di Bisceglie AM, Bruix J, et al. Design and endpoints of clinical trials in hepatocellular carcinoma. *J Natl Cancer Inst* 2008;100:698-711. Available at: <http://www.ncbi.nlm.nih.gov/pubmed/18477802>.

255. Majno P, Giostra E, Mentha G. Management of hepatocellular carcinoma on the waiting list before liver transplantation: time for

controlled trials? *Liver Transpl* 2007;13:S27-35. Available at: <http://www.ncbi.nlm.nih.gov/pubmed/17969086>.

256. Pompili M, Mirante VG, Rondinara G, et al. Percutaneous ablation procedures in cirrhotic patients with hepatocellular carcinoma submitted to liver transplantation: Assessment of efficacy at explant analysis and of safety for tumor recurrence. *Liver Transpl* 2005;11:1117-1126. Available at: <http://www.ncbi.nlm.nih.gov/pubmed/16123960>.

257. Mazzaferro V, Battiston C, Perrone S, et al. Radiofrequency ablation of small hepatocellular carcinoma in cirrhotic patients awaiting liver transplantation: a prospective study. *Ann Surg* 2004;240:900-909. Available at: <http://www.ncbi.nlm.nih.gov/pubmed/15492574>.

258. Yao FY, Bass NM, Nikolai B, et al. A follow-up analysis of the pattern and predictors of dropout from the waiting list for liver transplantation in patients with hepatocellular carcinoma: implications for the current organ allocation policy. *Liver Transpl* 2003;9:684-692. Available at: <http://www.ncbi.nlm.nih.gov/pubmed/12827553>.

259. DuBay DA, Sandroussi C, Kachura JR, et al. Radiofrequency ablation of hepatocellular carcinoma as a bridge to liver transplantation. *HPB (Oxford)* 2011;13:24-32. Available at: <http://www.ncbi.nlm.nih.gov/pubmed/21159100>.

260. Tsochatzis E, Garcovich M, Marelli L, et al. Transarterial embolization as neo-adjuvant therapy pretransplantation in patients with hepatocellular carcinoma. *Liver Int* 2013;33:944-949. Available at: <http://www.ncbi.nlm.nih.gov/pubmed/23530918>.

261. Llovet JM, Bruix J. Systematic review of randomized trials for unresectable hepatocellular carcinoma: Chemoembolization improves survival. *Hepatology* 2003;37:429-442. Available at: <https://www.ncbi.nlm.nih.gov/pubmed/12540794>.

262. Richard HM, Silberzweig JE, Mitty HA, et al. Hepatic arterial complications in liver transplant recipients treated with pretransplantation chemoembolization for hepatocellular carcinoma. *Radiology*





2000;214:775-779. Available at:  
<http://www.ncbi.nlm.nih.gov/pubmed/10715045>.

263. Graziadei IW, Sandmueller H, Waldenberger P, et al. Chemoembolization followed by liver transplantation for hepatocellular carcinoma impedes tumor progression while on the waiting list and leads to excellent outcome. *Liver Transpl* 2003;9:557-563. Available at:  
<http://www.ncbi.nlm.nih.gov/pubmed/12783395>.

264. Hayashi PH, Ludkowski M, Forman LM, et al. Hepatic artery chemoembolization for hepatocellular carcinoma in patients listed for liver transplantation. *Am J Transplant* 2004;4:782-787. Available at:  
<http://www.ncbi.nlm.nih.gov/pubmed/15084175>.

265. Nicolini D, Svegliati-Baroni G, Candelari R, et al. Doxorubicin-eluting bead vs conventional transcatheter arterial chemoembolization for hepatocellular carcinoma before liver transplantation. *World J Gastroenterol* 2013;19:5622-5632. Available at:  
<http://www.ncbi.nlm.nih.gov/pubmed/24039354>.

266. Kulik LM, Atassi B, van Holsbeeck L, et al. Yttrium-90 microspheres (TheraSphere) treatment of unresectable hepatocellular carcinoma: downstaging to resection, RFA and bridge to transplantation. *J Surg Oncol* 2006;94:572-586. Available at:  
<http://www.ncbi.nlm.nih.gov/pubmed/17048240>.

267. Sandroussi C, Dawson LA, Lee M, et al. Radiotherapy as a bridge to liver transplantation for hepatocellular carcinoma. *Transpl Int* 2010;23:299-306. Available at: <http://www.ncbi.nlm.nih.gov/pubmed/19843294>.

268. Lu L, Zeng J, Wen Z, et al. Transcatheter arterial chemoembolisation followed by three-dimensional conformal radiotherapy versus transcatheter arterial chemoembolisation alone for primary hepatocellular carcinoma in adults. *Cochrane Database Syst Rev* 2019;2:CD012244. Available at: <https://www.ncbi.nlm.nih.gov/pubmed/30776082>.

269. Kulik L, Heimbach JK, Zaiem F, et al. Therapies for patients with hepatocellular carcinoma awaiting liver transplantation: A systematic

review and meta-analysis. *Hepatology* 2018;67:381-400. Available at:  
<https://www.ncbi.nlm.nih.gov/pubmed/28859222>.

270. Freeman RB, Steffick DE, Guidinger MK, et al. Liver and intestine transplantation in the United States, 1997-2006. *Am J Transplant* 2008;8:958-976. Available at:  
<http://www.ncbi.nlm.nih.gov/pubmed/18336699>.

271. Campos BD, Botha JF. Transplantation for hepatocellular carcinoma and cholangiocarcinoma. *J Natl Compr Canc Netw* 2009;7:409-416. Available at: <http://www.ncbi.nlm.nih.gov/pubmed/19406041>.

272. Toso C, Mentha G, Kneteman NM, Majno P. The place of downstaging for hepatocellular carcinoma. *J Hepatol* 2010;52:930-936. Available at: <http://www.ncbi.nlm.nih.gov/pubmed/20385428>.

273. Yao FY, Fidelman N. Reassessing the boundaries of liver transplantation for hepatocellular carcinoma: Where do we stand with tumor down-staging? *Hepatology* 2016;63:1014-1025. Available at:  
<https://www.ncbi.nlm.nih.gov/pubmed/26560491>.

274. Parikh ND, Waljee AK, Singal AG. Downstaging hepatocellular carcinoma: A systematic review and pooled analysis. *Liver Transpl* 2015;21:1142-1152. Available at:  
<https://www.ncbi.nlm.nih.gov/pubmed/25981135>.

275. Ravaioli M, Grazi GL, Piscaglia F, et al. Liver transplantation for hepatocellular carcinoma: results of down-staging in patients initially outside the Milan selection criteria. *Am J Transplant* 2008;8:2547-2557. Available at: <http://www.ncbi.nlm.nih.gov/pubmed/19032223>.

276. Yao FY, Kerlan RK, Jr., Hirose R, et al. Excellent outcome following down-staging of hepatocellular carcinoma prior to liver transplantation: an intention-to-treat analysis. *Hepatology* 2008;48:819-827. Available at:  
<http://www.ncbi.nlm.nih.gov/pubmed/18688876>.

277. Chapman WC, Majella Doyle MB, Stuart JE, et al. Outcomes of neoadjuvant transarterial chemoembolization to downstage hepatocellular



carcinoma before liver transplantation. *Ann Surg* 2008;248:617-625. Available at: <http://www.ncbi.nlm.nih.gov/pubmed/18936575>.

278. Lewandowski RJ, Kulik LM, Riaz A, et al. A comparative analysis of transarterial downstaging for hepatocellular carcinoma: chemoembolization versus radioembolization. *Am J Transplant* 2009;9:1920-1928. Available at: <http://www.ncbi.nlm.nih.gov/pubmed/19552767>.

279. Yao FY, Mehta N, Flemming J, et al. Downstaging of hepatocellular cancer before liver transplant: long-term outcome compared to tumors within Milan criteria. *Hepatology* 2015;61:1968-1977. Available at: <https://www.ncbi.nlm.nih.gov/pubmed/25689978>.

280. De Luna W, Sze DY, Ahmed A, et al. Transarterial chemoinfusion for hepatocellular carcinoma as downstaging therapy and a bridge toward liver transplantation. *Am J Transplant* 2009;9:1158-1168. Available at: <https://www.ncbi.nlm.nih.gov/pubmed/19344435>.

281. Jang JW, You CR, Kim CW, et al. Benefit of downsizing hepatocellular carcinoma in a liver transplant population. *Aliment Pharmacol Ther* 2010;31:415-423. Available at: <http://www.ncbi.nlm.nih.gov/pubmed/19821808>.

282. Millonig G, Graziadei IW, Freund MC, et al. Response to preoperative chemoembolization correlates with outcome after liver transplantation in patients with hepatocellular carcinoma. *Liver Transpl* 2007;13:272-279. Available at: <http://www.ncbi.nlm.nih.gov/pubmed/17256758>.

283. Otto G, Herber S, Heise M, et al. Response to transarterial chemoembolization as a biological selection criterion for liver transplantation in hepatocellular carcinoma. *Liver Transpl* 2006;12:1260-1267. Available at: <http://www.ncbi.nlm.nih.gov/pubmed/16826556>.

284. Mazzaferro V, Citterio D, Bhoori S, et al. Liver transplantation in hepatocellular carcinoma after tumour downstaging (XXL): a randomised, controlled, phase 2b/3 trial. *Lancet Oncol* 2020;21:947-956. Available at: <https://www.ncbi.nlm.nih.gov/pubmed/32615109>.

285. Eisenhauer EA, Therasse P, Bogaerts J, et al. New response evaluation criteria in solid tumours: revised RECIST guideline (version 1.1). *Eur J Cancer* 2009;45:228-247. Available at: <http://www.ncbi.nlm.nih.gov/pubmed/19097774>.

286. Duke E, Deng J, Ibrahim SM, et al. Agreement between competing imaging measures of response of hepatocellular carcinoma to yttrium-90 radioembolization. *J Vasc Interv Radiol* 2010;21:515-521. Available at: <http://www.ncbi.nlm.nih.gov/pubmed/20172741>.

287. Lencioni R, Llovet JM. Modified RECIST (mRECIST) assessment for hepatocellular carcinoma. *Semin Liver Dis* 2010;30:52-60. Available at: <http://www.ncbi.nlm.nih.gov/pubmed/20175033>.

288. Riaz A, Miller FH, Kulik LM, et al. Imaging response in the primary index lesion and clinical outcomes following transarterial locoregional therapy for hepatocellular carcinoma. *JAMA* 2010;303:1062-1069. Available at: <http://www.ncbi.nlm.nih.gov/pubmed/20233824>.

289. Sato Y, Watanabe H, Sone M, et al. Tumor response evaluation criteria for HCC (hepatocellular carcinoma) treated using TACE (transcatheter arterial chemoembolization): RECIST (response evaluation criteria in solid tumors) version 1.1 and mRECIST (modified RECIST): JIVROSG-0602. *Ups J Med Sci* 2013;118:16-22. Available at: <https://www.ncbi.nlm.nih.gov/pubmed/23167460>.

290. Takada J, Hidaka H, Nakazawa T, et al. Modified response evaluation criteria in solid tumors is superior to response evaluation criteria in solid tumors for assessment of responses to sorafenib in patients with advanced hepatocellular carcinoma. *BMC Res Notes* 2015;8:609. Available at: <https://www.ncbi.nlm.nih.gov/pubmed/26502722>.

291. Riaz A, Ryu RK, Kulik LM, et al. Alpha-fetoprotein response after locoregional therapy for hepatocellular carcinoma: oncologic marker of radiologic response, progression, and survival. *J Clin Oncol* 2009;27:5734-5742. Available at: <http://www.ncbi.nlm.nih.gov/pubmed/19805671>.

292. Livraghi T, Goldberg SN, Lazzaroni S, et al. Small hepatocellular carcinoma: treatment with radio-frequency ablation versus ethanol



# NCCN Guidelines Version 5.2021

## Hepatobiliary Cancers

injection. Radiology 1999;210:655-661. Available at: <http://www.ncbi.nlm.nih.gov/pubmed/10207464>.

293. Lencioni RA, Allgaier HP, Cioni D, et al. Small hepatocellular carcinoma in cirrhosis: randomized comparison of radio-frequency thermal ablation versus percutaneous ethanol injection. Radiology 2003;228:235-240. Available at: <http://www.ncbi.nlm.nih.gov/pubmed/12759473>.

294. Lin S-M, Lin C-J, Lin C-C, et al. Radiofrequency ablation improves prognosis compared with ethanol injection for hepatocellular carcinoma < or =4 cm. Gastroenterology 2004;127:1714-1723. Available at: <http://www.ncbi.nlm.nih.gov/pubmed/15578509>.

295. Lin SM, Lin CJ, Lin CC, et al. Randomised controlled trial comparing percutaneous radiofrequency thermal ablation, percutaneous ethanol injection, and percutaneous acetic acid injection to treat hepatocellular carcinoma of 3 cm or less. Gut 2005;54:1151-1156. Available at: <http://www.ncbi.nlm.nih.gov/pubmed/16009687>.

296. Shiina S, Teratani T, Obi S, et al. A randomized controlled trial of radiofrequency ablation with ethanol injection for small hepatocellular carcinoma. Gastroenterology 2005;129:122-130. Available at: <http://www.ncbi.nlm.nih.gov/pubmed/16012942>.

297. Brunello F, Veltri A, Carucci P, et al. Radiofrequency ablation versus ethanol injection for early hepatocellular carcinoma: A randomized controlled trial. Scand J Gastroenterol 2008;43:727-735. Available at: <http://www.ncbi.nlm.nih.gov/pubmed/18569991>.

298. Giorgio A, Di Sarno A, De Stefano G, et al. Percutaneous radiofrequency ablation of hepatocellular carcinoma compared to percutaneous ethanol injection in treatment of cirrhotic patients: an Italian randomized controlled trial. Anticancer Res 2011;31:2291-2295. Available at: <http://www.ncbi.nlm.nih.gov/pubmed/21737654>.

299. Weis S, Franke A, Mossner J, et al. Radiofrequency (thermal) ablation versus no intervention or other interventions for hepatocellular carcinoma. Cochrane Database Syst Rev 2013;12:CD003046. Available at: <http://www.ncbi.nlm.nih.gov/pubmed/24357457>.

300. Cho YK, Kim JK, Kim MY, et al. Systematic review of randomized trials for hepatocellular carcinoma treated with percutaneous ablation therapies. Hepatology 2009;49:453-459. Available at: <http://www.ncbi.nlm.nih.gov/pubmed/19065676>.

301. Orlando A, Leandro G, Olivo M, et al. Radiofrequency thermal ablation vs. percutaneous ethanol injection for small hepatocellular carcinoma in cirrhosis: meta-analysis of randomized controlled trials. Am J Gastroenterol 2009;104:514-524. Available at: <http://www.ncbi.nlm.nih.gov/pubmed/19174803>.

302. Germani G, Pleguezuelo M, Gurusamy K, et al. Clinical outcomes of radiofrequency ablation, percutaneous alcohol and acetic acid injection for hepatocellular carcinoma: a meta-analysis. J Hepatol 2010;52:380-388. Available at: <http://www.ncbi.nlm.nih.gov/pubmed/20149473>.

303. Peng ZW, Zhang YJ, Chen MS, et al. Radiofrequency ablation as first-line treatment for small solitary hepatocellular carcinoma: long-term results. Eur J Surg Oncol 2010;36:1054-1060. Available at: <http://www.ncbi.nlm.nih.gov/pubmed/20846819>.

304. Shiina S, Tateishi R, Arano T, et al. Radiofrequency ablation for hepatocellular carcinoma: 10-year outcome and prognostic factors. Am J Gastroenterol 2012;107:569-577. Available at: <http://www.ncbi.nlm.nih.gov/pubmed/22158026>.

305. Brunello F, Cantamessa A, Gaia S, et al. Radiofrequency ablation: technical and clinical long-term outcomes for single hepatocellular carcinoma up to 30 mm. Eur J Gastroenterol Hepatol 2013;25:842-849. Available at: <http://www.ncbi.nlm.nih.gov/pubmed/23442417>.

306. Francica G, Saviano A, De Sio I, et al. Long-term effectiveness of radiofrequency ablation for solitary small hepatocellular carcinoma: a retrospective analysis of 363 patients. Dig Liver Dis 2013;45:336-341. Available at: <http://www.ncbi.nlm.nih.gov/pubmed/23245589>.

307. Huang G-T, Lee P-H, Tsang Y-M, et al. Percutaneous ethanol injection versus surgical resection for the treatment of small hepatocellular



carcinoma: a prospective study. *Ann Surg* 2005;242:36-42. Available at: <http://www.ncbi.nlm.nih.gov/pubmed/15973099>.

308. Chen M-S, Li J-Q, Zheng Y, et al. A prospective randomized trial comparing percutaneous local ablative therapy and partial hepatectomy for small hepatocellular carcinoma. *Ann Surg* 2006;243:321-328. Available at: <http://www.ncbi.nlm.nih.gov/pubmed/16495695>.

309. Huang J, Yan L, Cheng Z, et al. A randomized trial comparing radiofrequency ablation and surgical resection for HCC conforming to the Milan criteria. *Ann Surg* 2010;252:903-912. Available at: <http://www.ncbi.nlm.nih.gov/pubmed/21107100>.

310. Feng K, Yan J, Li X, et al. A randomized controlled trial of radiofrequency ablation and surgical resection in the treatment of small hepatocellular carcinoma. *J Hepatol* 2012;57:794-802. Available at: <http://www.ncbi.nlm.nih.gov/pubmed/22634125>.

311. Fang Y, Chen W, Liang X, et al. Comparison of long-term effectiveness and complications of radiofrequency ablation with hepatectomy for small hepatocellular carcinoma. *J Gastroenterol Hepatol* 2014;29:193-200. Available at: <https://www.ncbi.nlm.nih.gov/pubmed/24224779>.

312. Ng KKC, Chok KSH, Chan ACY, et al. Randomized clinical trial of hepatic resection versus radiofrequency ablation for early-stage hepatocellular carcinoma. *Br J Surg* 2017;104:1775-1784. Available at: <https://www.ncbi.nlm.nih.gov/pubmed/29091283>.

313. Feng Q, Chi Y, Liu Y, et al. Efficacy and safety of percutaneous radiofrequency ablation versus surgical resection for small hepatocellular carcinoma: a meta-analysis of 23 studies. *J Cancer Res Clin Oncol* 2015;141:1-9. Available at: <http://www.ncbi.nlm.nih.gov/pubmed/24889505>.

314. Jia JB, Zhang D, Ludwig JM, Kim HS. Radiofrequency ablation versus resection for hepatocellular carcinoma in patients with Child-Pugh A liver cirrhosis: a meta-analysis. *Clin Radiol* 2017;72:1066-1075. Available at: <https://www.ncbi.nlm.nih.gov/pubmed/28851491>.

315. Xu G, Qi F-Z, Zhang J-H, et al. Meta-analysis of surgical resection and radiofrequency ablation for early hepatocellular carcinoma. *World J Surg Oncol* 2012;10:163-163. Available at: <http://www.ncbi.nlm.nih.gov/pubmed/22897815>.

316. Cai H, Kong W, Zhou T, Qiu Y. Radiofrequency ablation versus reresection in treating recurrent hepatocellular carcinoma: a meta-analysis. *Medicine (Baltimore)* 2014;93:e122. Available at: <https://www.ncbi.nlm.nih.gov/pubmed/25396332>.

317. Livraghi T, Goldberg SN, Lazzaroni S, et al. Hepatocellular carcinoma: radio-frequency ablation of medium and large lesions. *Radiology* 2000;214:761-768. Available at: <http://www.ncbi.nlm.nih.gov/pubmed/10715043>.

318. Vivarelli M, Guglielmi A, Ruzzenente A, et al. Surgical resection versus percutaneous radiofrequency ablation in the treatment of hepatocellular carcinoma on cirrhotic liver. *Ann Surg* 2004;240:102-107. Available at: <http://www.ncbi.nlm.nih.gov/pubmed/15213625>.

319. Ruzzenente A, Guglielmi A, Sandri M, et al. Surgical resection versus local ablation for HCC on cirrhosis: results from a propensity case-matched study. *J Gastrointest Surg* 2012;16:301-311; discussion 311. Available at: <http://www.ncbi.nlm.nih.gov/pubmed/22095524>.

320. Livraghi T, Meloni F, Di Stasi M, et al. Sustained complete response and complications rates after radiofrequency ablation of very early hepatocellular carcinoma in cirrhosis: Is resection still the treatment of choice? *Hepatology* 2008;47:82-89. Available at: <http://www.ncbi.nlm.nih.gov/pubmed/18008357>.

321. Peng ZW, Lin XJ, Zhang YJ, et al. Radiofrequency ablation versus hepatic resection for the treatment of hepatocellular carcinomas 2 cm or smaller: a retrospective comparative study. *Radiology* 2012;262:1022-1033. Available at: <http://www.ncbi.nlm.nih.gov/pubmed/22357902>.

322. Shibata T, Imuro Y, Yamamoto Y, et al. Small hepatocellular carcinoma: comparison of radio-frequency ablation and percutaneous





microwave coagulation therapy. Radiology 2002;223:331-337. Available at: <http://www.ncbi.nlm.nih.gov/pubmed/11997534>.

323. Ding J, Jing X, Liu J, et al. Comparison of two different thermal techniques for the treatment of hepatocellular carcinoma. Eur J Radiol 2013;82:1379-1384. Available at: <http://www.ncbi.nlm.nih.gov/pubmed/23726122>.

324. Groeschl RT, Pilgrim CHC, Hanna EM, et al. Microwave ablation for hepatic malignancies: a multiinstitutional analysis. Ann Surg 2013. Available at: <http://www.ncbi.nlm.nih.gov/pubmed/24096760>.

325. Zhang L, Wang N, Shen Q, et al. Therapeutic efficacy of percutaneous radiofrequency ablation versus microwave ablation for hepatocellular carcinoma. PLoS One 2013;8. Available at: <http://www.ncbi.nlm.nih.gov/pubmed/24146824>.

326. Shi J, Sun Q, Wang Y, et al. Comparison of microwave ablation and surgical resection for treatment of hepatocellular carcinomas conforming to Milan Criteria. J Gastroenterol Hepatol 2014. Available at: <http://www.ncbi.nlm.nih.gov/pubmed/24628534>.

327. Hsiao CY, Huang KW. Irreversible electroporation: a novel ultrasound-guided modality for non-thermal tumor ablation. J Med Ultrasound 2017;25:195-200. Available at: <https://www.ncbi.nlm.nih.gov/pubmed/30065492>.

328. Narayanan G, Froud T, Suthar R, Barbary K. Irreversible electroporation of hepatic malignancy. Semin Intervent Radiol 2013;30:67-73. Available at: <https://www.ncbi.nlm.nih.gov/pubmed/24436519>.

329. Lencioni R, Crocetti L, Narayanan G. Irreversible electroporation in the treatment of hepatocellular carcinoma. Tech Vasc Interv Radiol 2015;18:135-139. Available at: <https://www.ncbi.nlm.nih.gov/pubmed/26365542>.

330. Scheffer HJ, Nielsen K, de Jong MC, et al. Irreversible electroporation for nonthermal tumor ablation in the clinical setting: a systematic review of safety and efficacy. J Vasc Interv Radiol

2014;25:997-1011; quiz 1011. Available at: <https://www.ncbi.nlm.nih.gov/pubmed/24656178>.

331. Cheung W, Kavnoudias H, Roberts S, et al. Irreversible electroporation for unresectable hepatocellular carcinoma: initial experience and review of safety and outcomes. Technol Cancer Res Treat 2013;12:233-241. Available at: <https://www.ncbi.nlm.nih.gov/pubmed/23369152>.

332. Cannon R, Ellis S, Hayes D, et al. Safety and early efficacy of irreversible electroporation for hepatic tumors in proximity to vital structures. J Surg Oncol 2013;107:544-549. Available at: <https://www.ncbi.nlm.nih.gov/pubmed/23090720>.

333. Fruhling P, Nilsson A, Duraj F, et al. Single-center nonrandomized clinical trial to assess the safety and efficacy of irreversible electroporation (IRE) ablation of liver tumors in humans: Short to mid-term results. Eur J Surg Oncol 2017;43:751-757. Available at: <https://www.ncbi.nlm.nih.gov/pubmed/28109674>.

334. Liapi E, Geschwind J-FH. Intra-arterial therapies for hepatocellular carcinoma: where do we stand? Ann Surg Oncol 2010;17:1234-1246. Available at: <http://www.ncbi.nlm.nih.gov/pubmed/20405328>.

335. Rand T, Loewe C, Schoder M, et al. Arterial embolization of unresectable hepatocellular carcinoma with use of microspheres, lipiodol, and cyanoacrylate. Cardiovasc Intervent Radiol 2005;28:313-318. Available at: <http://www.ncbi.nlm.nih.gov/pubmed/15886943>.

336. Huang YH, Chen CH, Chang TT, et al. The role of transcatheter arterial embolization for patients with unresectable hepatocellular carcinoma: a nationwide, multicentre study evaluated by cancer stage. Aliment Pharmacol Ther 2005;21:687-694. Available at: <http://www.ncbi.nlm.nih.gov/pubmed/15771754>.

337. Maluccio MA, Covey AM, Porat LB, et al. Transcatheter arterial embolization with only particles for the treatment of unresectable hepatocellular carcinoma. J Vasc Interv Radiol 2008;19:862-869. Available at: <http://www.ncbi.nlm.nih.gov/pubmed/18503900>.





338. Bonomo G, Pedicini V, Monfardini L, et al. Bland embolization in patients with unresectable hepatocellular carcinoma using precise, tightly size-calibrated, anti-inflammatory microparticles: first clinical experience and one-year follow-up. *Cardiovasc Intervent Radiol* 2010;33:552-559. Available at: <http://www.ncbi.nlm.nih.gov/pubmed/19957182>.

339. Ramsey DE, Kernagis LY, Soulen MC, Geschwind J-FH. Chemoembolization of hepatocellular carcinoma. *J Vasc Interv Radiol* 2002;13:211-221. Available at: <http://www.ncbi.nlm.nih.gov/pubmed/12354839>.

340. Lo C-M, Ngan H, Tso W-K, et al. Randomized controlled trial of transarterial lipiodol chemoembolization for unresectable hepatocellular carcinoma. *Hepatology* 2002;35:1164-1171. Available at: <http://www.ncbi.nlm.nih.gov/pubmed/11981766>.

341. Llovet JM, Real MI, Montana X, et al. Arterial embolisation or chemoembolisation versus symptomatic treatment in patients with unresectable hepatocellular carcinoma: a randomised controlled trial. *Lancet* 2002;359:1734-1739. Available at: <http://www.ncbi.nlm.nih.gov/pubmed/12049862>.

342. Kong JY, Li SM, Fan HY, et al. Transarterial chemoembolization extends long-term survival in patients with unresectable hepatocellular carcinoma. *Medicine (Baltimore)* 2018;97:e11872. Available at: <https://www.ncbi.nlm.nih.gov/pubmed/30113483>.

343. Brown KT, Do RK, Gonen M, et al. Randomized trial of hepatic artery embolization for hepatocellular carcinoma using doxorubicin-eluting microspheres compared with embolization with microspheres alone. *J Clin Oncol* 2016;34:2046-2053. Available at: <https://www.ncbi.nlm.nih.gov/pubmed/26834067>.

344. Morse MA, Hanks BA, Suhocki P, et al. Improved time to progression for transarterial chemoembolization compared with transarterial embolization for patients with unresectable hepatocellular carcinoma. *Clin Colorectal Cancer* 2012;11:185-190. Available at: <http://www.ncbi.nlm.nih.gov/pubmed/22280845>.

345. Molinari M, Kachura JR, Dixon E, et al. Transarterial chemoembolisation for advanced hepatocellular carcinoma: results from a North American cancer centre. *Clin Oncol (R Coll Radiol)* 2006;18:684-692. Available at: <http://www.ncbi.nlm.nih.gov/pubmed/17100154>.

346. Llado L, Virgili J, Figueras J, et al. A prognostic index of the survival of patients with unresectable hepatocellular carcinoma after transcatheter arterial chemoembolization. *Cancer* 2000;88:50-57. Available at: <http://www.ncbi.nlm.nih.gov/pubmed/10618605>.

347. Han K, Kim JH, Ko GY, et al. Treatment of hepatocellular carcinoma with portal venous tumor thrombosis: A comprehensive review. *World J Gastroenterol* 2016;22:407-416. Available at: <https://www.ncbi.nlm.nih.gov/pubmed/26755886>.

348. Leng JJ, Xu YZ, Dong JH. Efficacy of transarterial chemoembolization for hepatocellular carcinoma with portal vein thrombosis: a meta-analysis. *ANZ J Surg* 2016;86:816-820. Available at: <https://www.ncbi.nlm.nih.gov/pubmed/25088384>.

349. Kim W, Clark TW, Baum RA, Soulen MC. Risk factors for liver abscess formation after hepatic chemoembolization. *J Vasc Interv Radiol* 2001;12:965-968. Available at: <http://www.ncbi.nlm.nih.gov/pubmed/11487677>.

350. Mezhir JJ, Fong Y, Fleischer D, et al. Pyogenic abscess after hepatic artery embolization: a rare but potentially lethal complication. *J Vasc Interv Radiol* 2011;22:177-182. Available at: <http://www.ncbi.nlm.nih.gov/pubmed/21195630>.

351. Sergio A, Cristofori C, Cardin R, et al. Transcatheter arterial chemoembolization (TACE) in hepatocellular carcinoma (HCC): the role of angiogenesis and invasiveness. *Am J Gastroenterol* 2008;103:914-921. Available at: <http://www.ncbi.nlm.nih.gov/pubmed/18177453>.

352. Xiong ZP, Yang SR, Liang ZY, et al. Association between vascular endothelial growth factor and metastasis after transcatheter arterial chemoembolization in patients with hepatocellular carcinoma.



Hepatobiliary Pancreat Dis Int 2004;3:386-390. Available at: <http://www.ncbi.nlm.nih.gov/pubmed/15313674>.

353. Song BC, Chung YH, Kim JA, et al. Association between insulin-like growth factor-2 and metastases after transcatheter arterial chemoembolization in patients with hepatocellular carcinoma: a prospective study. Cancer 2001;91:2386-2393. Available at: <http://www.ncbi.nlm.nih.gov/pubmed/11413529>.

354. Kudo M, Imanaka K, Chida N, et al. Phase III study of sorafenib after transarterial chemoembolisation in Japanese and Korean patients with unresectable hepatocellular carcinoma. Eur J Cancer 2011;47:2117-2127. Available at: <http://www.ncbi.nlm.nih.gov/pubmed/21664811>.

355. Erhardt A, Kolligs F, Dollinger M, et al. TACE plus sorafenib for the treatment of hepatocellular carcinoma: results of the multicenter, phase II SOCRATES trial. Cancer Chemother Pharmacol 2014;74:947-954. Available at: <https://www.ncbi.nlm.nih.gov/pubmed/25173458>.

356. Pawlik TM, Reyes DK, Cosgrove D, et al. Phase II trial of sorafenib combined with concurrent transarterial chemoembolization with drug-eluting beads for hepatocellular carcinoma. J Clin Oncol 2011;29:3960-3967. Available at: <http://www.ncbi.nlm.nih.gov/pubmed/21911714>.

357. Park J-W, Koh YH, Kim HB, et al. Phase II study of concurrent transarterial chemoembolization and sorafenib in patients with unresectable hepatocellular carcinoma. J Hepatol 2012;56:1336-1342. Available at: <http://www.ncbi.nlm.nih.gov/pubmed/22314421>.

358. Chung Y-H, Han G, Yoon J-H, et al. Interim analysis of START: study in Asia of the combination of TACE (transcatheter arterial chemoembolization) with sorafenib in patients with hepatocellular carcinoma trial. Int J Cancer 2013;132:2448-2458. Available at: <http://www.ncbi.nlm.nih.gov/pubmed/23129123>.

359. Zhu K, Chen J, Lai L, et al. Hepatocellular carcinoma with portal vein tumor thrombus: treatment with transarterial chemoembolization combined with sorafenib—a retrospective controlled study. Radiology 2014;272:284-293. Available at: <http://www.ncbi.nlm.nih.gov/pubmed/24708192>.

360. Zhao Y, Wang WJ, Guan S, et al. Sorafenib combined with transarterial chemoembolization for the treatment of advanced hepatocellular carcinoma: a large-scale multicenter study of 222 patients. Ann Oncol 2013;24:1786-1792. Available at: <http://www.ncbi.nlm.nih.gov/pubmed/23508822>.

361. Lencioni R, Llovet JM, Han G, et al. Sorafenib or placebo plus TACE with doxorubicin-eluting beads for intermediate stage HCC: the SPACE trial. J Hepatol 2016;64:1090-1098. Available at: <https://www.ncbi.nlm.nih.gov/pubmed/26809111>.

362. Poon RT, Tso WK, Pang RW, et al. A phase I/II trial of chemoembolization for hepatocellular carcinoma using a novel intra-arterial drug-eluting bead. Clin Gastroenterol Hepatol 2007;5:1100-1108. Available at: <http://www.ncbi.nlm.nih.gov/pubmed/17627902>.

363. Reyes DK, Vossen JA, Kamel IR, et al. Single-center phase II trial of transarterial chemoembolization with drug-eluting beads for patients with unresectable hepatocellular carcinoma: initial experience in the United States. Cancer J 2009;15:526-532. Available at: <http://www.ncbi.nlm.nih.gov/pubmed/20010173>.

364. Lammer J, Malagari K, Vogl T, et al. Prospective randomized study of doxorubicin-eluting-bead embolization in the treatment of hepatocellular carcinoma: results of the PRECISION V study. Cardiovasc Intervent Radiol 2010;33:41-52. Available at: <http://www.ncbi.nlm.nih.gov/pubmed/19908093>.

365. Malagari K, Pomoni M, Kelekis A, et al. Prospective randomized comparison of chemoembolization with doxorubicin-eluting beads and bland embolization with BeadBlock for hepatocellular carcinoma. Cardiovasc Intervent Radiol 2010;33:541-551. Available at: <http://www.ncbi.nlm.nih.gov/pubmed/19937027>.

366. Dhanasekaran R, Kooby DA, Staley CA, et al. Comparison of conventional transarterial chemoembolization (TACE) and chemoembolization with doxorubicin drug eluting beads (DEB) for unresectable hepatocellular carcinoma (HCC). J Surg Oncol



2010;101:476-480. Available at:  
<http://www.ncbi.nlm.nih.gov/pubmed/20213741>.

367. Malagari K, Pomoni M, Moschouris H, et al. Chemoembolization with doxorubicin-eluting beads for unresectable hepatocellular carcinoma: five-year survival analysis. *Cardiovasc Intervent Radiol* 2012;35:1119-1128. Available at: <https://www.ncbi.nlm.nih.gov/pubmed/22614031>.

368. Song MJ, Chun HJ, Song do S, et al. Comparative study between doxorubicin-eluting beads and conventional transarterial chemoembolization for treatment of hepatocellular carcinoma. *J Hepatol* 2012;57:1244-1250. Available at: <http://www.ncbi.nlm.nih.gov/pubmed/22824821>.

369. Golfieri R, Giampalma E, Renzulli M, et al. Randomised controlled trial of doxorubicin-eluting beads vs conventional chemoembolisation for hepatocellular carcinoma. *Br J Cancer* 2014;111:255-264. Available at: <http://www.ncbi.nlm.nih.gov/pubmed/24937669>.

370. Yang B, Liang J, Qu Z, et al. Transarterial strategies for the treatment of unresectable hepatocellular carcinoma: A systematic review. *PLoS One* 2020;15:e0227475. Available at: <https://www.ncbi.nlm.nih.gov/pubmed/32074102>.

371. Chao Y, Chung YH, Han G, et al. The combination of transcatheter arterial chemoembolization and sorafenib is well tolerated and effective in Asian patients with hepatocellular carcinoma: final results of the START trial. *Int J Cancer* 2015;136:1458-1467. Available at: <https://www.ncbi.nlm.nih.gov/pubmed/25099027>.

372. Cai R, Song R, Pang P, et al. Transcatheter arterial chemoembolization plus sorafenib versus transcatheter arterial chemoembolization alone to treat advanced hepatocellular carcinoma: a meta-analysis. *BMC Cancer* 2017;17:714. Available at: <https://www.ncbi.nlm.nih.gov/pubmed/29110700>.

373. Jin PP, Shao SY, Wu WT, et al. Combination of transarterial chemoembolization and sorafenib improves outcomes of unresectable hepatocellular carcinoma: an updated systematic review and meta-

analysis. *Jpn J Clin Oncol* 2018;48:1058-1069. Available at: <https://www.ncbi.nlm.nih.gov/pubmed/30272196>.

374. Li L, Zhao W, Wang M, et al. Transarterial chemoembolization plus sorafenib for the management of unresectable hepatocellular carcinoma: a systematic review and meta-analysis. *BMC Gastroenterol* 2018;18:138. Available at: <https://www.ncbi.nlm.nih.gov/pubmed/30180810>.

375. Meyer T, Fox R, Ma YT, et al. Sorafenib in combination with transarterial chemoembolisation in patients with unresectable hepatocellular carcinoma (TACE 2): a randomised placebo-controlled, double-blind, phase 3 trial. *Lancet Gastroenterol Hepatol* 2017;2:565-575. Available at: <https://www.ncbi.nlm.nih.gov/pubmed/28648803>.

376. Ibrahim SM, Lewandowski RJ, Sato KT, et al. Radioembolization for the treatment of unresectable hepatocellular carcinoma: a clinical review. *World J Gastroenterol* 2008;14:1664-1669. Available at: <http://www.ncbi.nlm.nih.gov/pubmed/18350597>.

377. Kulik LM, Carr BI, Mulcahy MF, et al. Safety and efficacy of 90Y radiotherapy for hepatocellular carcinoma with and without portal vein thrombosis. *Hepatology* 2008;47:71-81. Available at: <http://www.ncbi.nlm.nih.gov/pubmed/18027884>.

378. Woodall CE, Scoggins CR, Ellis SF, et al. Is selective internal radioembolization safe and effective for patients with inoperable hepatocellular carcinoma and venous thrombosis? *J Am Coll Surg* 2009;208:375-382. Available at: <http://www.ncbi.nlm.nih.gov/pubmed/19317999>.

379. Salem R, Lewandowski RJ, Mulcahy MF, et al. Radioembolization for hepatocellular carcinoma using Yttrium-90 microspheres: a comprehensive report of long-term outcomes. *Gastroenterology* 2010;138:52-64. Available at: <http://www.ncbi.nlm.nih.gov/pubmed/19766639>.

380. Sangro B, Carpanese L, Cianni R, et al. Survival after yttrium-90 resin microsphere radioembolization of hepatocellular carcinoma across Barcelona clinic liver cancer stages: a European evaluation. *Hepatology*



2011;54:868-878. Available at:

<http://www.ncbi.nlm.nih.gov/pubmed/21618574>.

381. Mazzaferro V, Sposito C, Bhoori S, et al. Yttrium-90 radioembolization for intermediate-advanced hepatocellular carcinoma: a phase 2 study. *Hepatology* 2013;57:1826-1837. Available at:

<http://www.ncbi.nlm.nih.gov/pubmed/22911442>.

382. Vouche M, Habib A, Ward TJ, et al. Unresectable solitary hepatocellular carcinoma not amenable to radiofrequency ablation: multicenter radiology-pathology correlation and survival of radiation segmentectomy. *Hepatology* 2014;60:192-201. Available at:

<http://www.ncbi.nlm.nih.gov/pubmed/24691943>.

383. Abdel-Rahman OM, Elsayed Z. Yttrium-90 microsphere radioembolisation for unresectable hepatocellular carcinoma. *Cochrane Database Syst Rev* 2016;2:Cd011313. Available at:

<https://www.ncbi.nlm.nih.gov/pubmed/26905230>.

384. Garin E, Tselikas L, Guiu B, et al. Personalised versus standard dosimetry approach of selective internal radiation therapy in patients with locally advanced hepatocellular carcinoma (DOSISPHERE-01): a randomised, multicentre, open-label phase 2 trial. *Lancet Gastroenterol Hepatol* 2021;6:17-29. Available at:

<https://www.ncbi.nlm.nih.gov/pubmed/33166497>.

385. Vilgrain V, Pereira H, Assenat E, et al. Efficacy and safety of selective internal radiotherapy with yttrium-90 resin microspheres compared with sorafenib in locally advanced and inoperable hepatocellular carcinoma (SARAH): an open-label randomised controlled phase 3 trial. *Lancet Oncol* 2017;18:1624-1636. Available at:

<https://www.ncbi.nlm.nih.gov/pubmed/29107679>.

386. Chow PKH, Gandhi M, Tan SB, et al. SIRveNIB: Selective internal radiation therapy versus sorafenib in Asia-Pacific patients with hepatocellular carcinoma. *J Clin Oncol* 2018;36:1913-1921. Available at:

<https://www.ncbi.nlm.nih.gov/pubmed/29498924>.

387. Atassi B, Bangash AK, Bahrani A, et al. Multimodality imaging following 90Y radioembolization: a comprehensive review and pictorial essay. *Radiographics* 2008;28:81-99. Available at:

<http://www.ncbi.nlm.nih.gov/pubmed/18203932>.

388. Jia Z, Jiang G, Tian F, et al. A systematic review on the safety and effectiveness of yttrium-90 radioembolization for hepatocellular carcinoma with portal vein tumor thrombosis. *Saudi J Gastroenterol* 2016;22:353-359. Available at:

<https://www.ncbi.nlm.nih.gov/pubmed/27748320>.

389. Lobo L, Yakoub D, Picado O, et al. Unresectable hepatocellular carcinoma: radioembolization versus chemoembolization: a systematic review and meta-analysis. *Cardiovasc Intervent Radiol* 2016;39:1580-1588. Available at:

<https://www.ncbi.nlm.nih.gov/pubmed/27586657>.

390. Ludwig JM, Zhang D, Xing M, Kim HS. Meta-analysis: adjusted indirect comparison of drug-eluting bead transarterial chemoembolization versus (90)Y-radioembolization for hepatocellular carcinoma. *Eur Radiol* 2017;27:2031-2041. Available at:

<https://www.ncbi.nlm.nih.gov/pubmed/27562480>.

391. Hawkins MA, Dawson LA. Radiation therapy for hepatocellular carcinoma: from palliation to cure. *Cancer* 2006;106:1653-1663. Available at:

<http://www.ncbi.nlm.nih.gov/pubmed/16541431>.

392. Hoffer SE, Finkelstein SE, Russell MS, Shridhar R. Nonsurgical options for hepatocellular carcinoma: evolving role of external beam radiotherapy. *Cancer Control* 2010;17:100-110. Available at:

<http://www.ncbi.nlm.nih.gov/pubmed/20404793>.

393. Kwon JH, Bae SH, Kim JY, et al. Long-term effect of stereotactic body radiation therapy for primary hepatocellular carcinoma ineligible for local ablation therapy or surgical resection. *Stereotactic radiotherapy for liver cancer*. *BMC Cancer* 2010;10:475-475. Available at:

<http://www.ncbi.nlm.nih.gov/pubmed/20813065>.

394. Andolino DL, Johnson CS, Maluccio M, et al. Stereotactic body radiotherapy for primary hepatocellular carcinoma. *Int J Radiat Oncol Biol*





Phys 2011;81:e447-453. Available at:

<http://www.ncbi.nlm.nih.gov/pubmed/21645977>.

395. Huang W-Y, Jen Y-M, Lee M-S, et al. Stereotactic body radiation therapy in recurrent hepatocellular carcinoma. *Int J Radiat Oncol Biol Phys* 2012;84:355-361. Available at:

<http://www.ncbi.nlm.nih.gov/pubmed/22342300>.

396. Kang J-K, Kim M-S, Cho CK, et al. Stereotactic body radiation therapy for inoperable hepatocellular carcinoma as a local salvage treatment after incomplete transarterial chemoembolization. *Cancer* 2012;118:5424-5431. Available at:

<http://www.ncbi.nlm.nih.gov/pubmed/22570179>.

397. Bujold A, Massey CA, Kim JJ, et al. Sequential phase I and II trials of stereotactic body radiotherapy for locally advanced hepatocellular carcinoma. *J Clin Oncol* 2013;31:1631-1639. Available at:

<http://www.ncbi.nlm.nih.gov/pubmed/23547075>.

398. Wahl DR, Stenmark MH, Tao Y, et al. Outcomes after stereotactic body radiotherapy or radiofrequency ablation for hepatocellular carcinoma. *J Clin Oncol* 2016;34:452-459. Available at:

<https://www.ncbi.nlm.nih.gov/pubmed/26628466>.

399. Rajyaguru DJ, Borgert AJ, Smith AL, et al. Radiofrequency ablation versus stereotactic body radiotherapy for localized hepatocellular carcinoma in nonsurgically managed patients: analysis of the National Cancer Database. *J Clin Oncol* 2018;36:600-608. Available at:

<https://www.ncbi.nlm.nih.gov/pubmed/29328861>.

400. Facciuto ME, Singh MK, Rochon C, et al. Stereotactic body radiation therapy in hepatocellular carcinoma and cirrhosis: evaluation of radiological and pathological response. *J Surg Oncol* 2012;105:692-698. Available at:

<http://www.ncbi.nlm.nih.gov/pubmed/21960321>.

401. Katz AW, Chawla S, Qu Z, et al. Stereotactic hypofractionated radiation therapy as a bridge to transplantation for hepatocellular carcinoma: clinical outcome and pathologic correlation. *Int J Radiat Oncol*

*Biol Phys* 2012;83:895-900. Available at:

<http://www.ncbi.nlm.nih.gov/pubmed/22172906>.

402. O'Connor JK, Trotter J, Davis GL, et al. Long-term outcomes of stereotactic body radiation therapy in the treatment of hepatocellular cancer as a bridge to transplantation. *Liver Transpl* 2012;18:949-954. Available at:

<http://www.ncbi.nlm.nih.gov/pubmed/22467602>.

403. Cardenes HR, Price TR, Perkins SM, et al. Phase I feasibility trial of stereotactic body radiation therapy for primary hepatocellular carcinoma. *Clin Transl Oncol* 2010;12:218-225. Available at:

<http://www.ncbi.nlm.nih.gov/pubmed/20231127>.

404. Velec M, Haddad CR, Craig T, et al. Predictors of liver toxicity following stereotactic body radiation therapy for hepatocellular carcinoma. *Int J Radiat Oncol Biol Phys* 2017;97:939-946. Available at:

<https://www.ncbi.nlm.nih.gov/pubmed/28333016>.

405. Tse RV, Hawkins M, Lockwood G, et al. Phase I study of individualized stereotactic body radiotherapy for hepatocellular carcinoma and intrahepatic cholangiocarcinoma. *J Clin Oncol* 2008;26:657-664. Available at:

<http://www.ncbi.nlm.nih.gov/pubmed/18172187>.

406. Tanguturi SK, Wo JY, Zhu AX, et al. Radiation therapy for liver tumors: ready for inclusion in guidelines? *Oncologist* 2014;19:868-879. Available at:

<https://www.ncbi.nlm.nih.gov/pubmed/25001265>.

407. Proton Beam Therapy. American Society for Radiation Oncology; 2014. Available at:

[http://www.astro.org/uploadedFiles/Main\\_Site/Practice\\_Management/Reimbursement/ASTRO%20PBT%20Model%20Policy%20FINAL.pdf](http://www.astro.org/uploadedFiles/Main_Site/Practice_Management/Reimbursement/ASTRO%20PBT%20Model%20Policy%20FINAL.pdf).

Accessed 11/26/18.

408. Hong TS, Wo JY, Yeap BY, et al. Multi-institutional phase II study of high-dose hypofractionated proton beam therapy in patients with localized, unresectable hepatocellular carcinoma and intrahepatic cholangiocarcinoma. *J Clin Oncol* 2016;34:460-468. Available at:

<https://www.ncbi.nlm.nih.gov/pubmed/26668346>.





409. Qi WX, Fu S, Zhang Q, Guo XM. Charged particle therapy versus photon therapy for patients with hepatocellular carcinoma: a systematic review and meta-analysis. *Radiother Oncol* 2015;114:289-295. Available at: <https://www.ncbi.nlm.nih.gov/pubmed/25497556>.

410. Sanford NN, Pursley J, Noe B, et al. Protons versus Photons for Unresectable Hepatocellular Carcinoma: Liver Decompensation and Overall Survival. *Int J Radiat Oncol Biol Phys* 2019;105:64-72. Available at: <https://www.ncbi.nlm.nih.gov/pubmed/30684667>.

411. Bush DA, Smith JC, Slater JD, et al. Randomized clinical trial comparing proton beam radiation therapy with transarterial chemoembolization for hepatocellular carcinoma: results of an interim analysis. *Int J Radiat Oncol Biol Phys* 2016;95:477-482. Available at: <https://www.ncbi.nlm.nih.gov/pubmed/27084661>.

412. Kim TH, Park JW, Kim BH, et al. Phase II study of hypofractionated proton beam therapy for hepatocellular carcinoma. *Front Oncol* 2020;10:542. Available at: <https://www.ncbi.nlm.nih.gov/pubmed/32411594>.

413. Kirikoshi H, Saito S, Yoneda M, et al. Outcome of transarterial chemoembolization monotherapy, and in combination with percutaneous ethanol injection, or radiofrequency ablation therapy for hepatocellular carcinoma. *Hepatol Res* 2009;39:553-562. Available at: <http://www.ncbi.nlm.nih.gov/pubmed/19527484>.

414. Maluccio M, Covey AM, Gandhi R, et al. Comparison of survival rates after bland arterial embolization and ablation versus surgical resection for treating solitary hepatocellular carcinoma up to 7 cm. *J Vasc Interv Radiol* 2005;16:955-961. Available at: <http://www.ncbi.nlm.nih.gov/pubmed/16002503>.

415. Elnekave E, Erinjeri JP, Brown KT, et al. Long-term outcomes comparing surgery to embolization-ablation for treatment of solitary HCC <7 cm. *Ann Surg Oncol* 2013. Available at: <http://www.ncbi.nlm.nih.gov/pubmed/23563960>.

416. Koda M, Murawaki Y, Mitsuda A, et al. Combination therapy with transcatheter arterial chemoembolization and percutaneous ethanol injection compared with percutaneous ethanol injection alone for patients with small hepatocellular carcinoma: a randomized control study. *Cancer* 2001;92:1516-1524. Available at: <http://www.ncbi.nlm.nih.gov/pubmed/11745230>.

417. Becker G, Soezgen T, Olschewski M, et al. Combined TACE and PEI for palliative treatment of unresectable hepatocellular carcinoma. *World J Gastroenterol* 2005;11:6104-6109. Available at: <http://www.ncbi.nlm.nih.gov/pubmed/16273634>.

418. Peng Z-W, Zhang Y-J, Chen M-S, et al. Radiofrequency ablation with or without transcatheter arterial chemoembolization in the treatment of hepatocellular carcinoma: a prospective randomized trial. *J Clin Oncol* 2013;31:426-432. Available at: <http://www.ncbi.nlm.nih.gov/pubmed/23269991>.

419. Shibata T, Isoda H, Hirokawa Y, et al. Small hepatocellular carcinoma: is radiofrequency ablation combined with transcatheter arterial chemoembolization more effective than radiofrequency ablation alone for treatment? *Radiology* 2009;252:905-913. Available at: <http://radiology.rsna.org/content/252/3/905.full.pdf>.

420. Kim JH, Won HJ, Shin YM, et al. Medium-sized (3.1-5.0 cm) hepatocellular carcinoma: transarterial chemoembolization plus radiofrequency ablation versus radiofrequency ablation alone. *Ann Surg Oncol* 2011;18:1624-1629. Available at: <http://www.ncbi.nlm.nih.gov/pubmed/21445671>.

421. Peng ZW, Zhang YJ, Liang HH, et al. Recurrent hepatocellular carcinoma treated with sequential transcatheter arterial chemoembolization and RF ablation versus RF ablation alone: a prospective randomized trial. *Radiology* 2012;262:689-700. Available at: <http://www.ncbi.nlm.nih.gov/pubmed/22157201>.

422. Sheta E, El-Kalla F, El-Gharib M, et al. Comparison of single-session transarterial chemoembolization combined with microwave ablation or radiofrequency ablation in the treatment of hepatocellular carcinoma: a



randomized-controlled study. *Eur J Gastroenterol Hepatol* 2016;28:1198-1203. Available at: <https://www.ncbi.nlm.nih.gov/pubmed/27362551>.

423. Wang W, Shi J, Xie WF. Transarterial chemoembolization in combination with percutaneous ablation therapy in unresectable hepatocellular carcinoma: a meta-analysis. *Liver Int* 2010;30:741-749. Available at: <http://www.ncbi.nlm.nih.gov/pubmed/20331507>.

424. Huo YR, Eslick GD. Transcatheter arterial chemoembolization plus radiotherapy compared with chemoembolization alone for hepatocellular carcinoma: a systematic review and meta-analysis. *JAMA Oncol* 2015;1:756-765. Available at: <https://www.ncbi.nlm.nih.gov/pubmed/26182200>.

425. Abdel-Rahman O, Elsayed Z. External beam radiotherapy for unresectable hepatocellular carcinoma. *Cochrane Database Syst Rev* 2017;3:CD011314. Available at: <https://www.ncbi.nlm.nih.gov/pubmed/28267205>.

426. Yoon SM, Ryoo BY, Lee SJ, et al. Efficacy and safety of transarterial chemoembolization plus external beam radiotherapy vs sorafenib in hepatocellular carcinoma with macroscopic vascular invasion: a randomized clinical trial. *JAMA Oncol* 2018;4:661-669. Available at: <https://www.ncbi.nlm.nih.gov/pubmed/29543938>.

427. Llovet JM, Vilana R, Bru C, et al. Increased risk of tumor seeding after percutaneous radiofrequency ablation for single hepatocellular carcinoma. *Hepatology* 2001;33:1124-1129. Available at: <http://www.ncbi.nlm.nih.gov/pubmed/11343240>.

428. Livraghi T, Solbiati L, Meloni MF, et al. Treatment of focal liver tumors with percutaneous radio-frequency ablation: complications encountered in a multicenter study. *Radiology* 2003;226:441-451. Available at: <http://www.ncbi.nlm.nih.gov/pubmed/12563138>.

429. Lencioni R, Cioni D, Crocetti L, et al. Early-stage hepatocellular carcinoma in patients with cirrhosis: long-term results of percutaneous image-guided radiofrequency ablation. *Radiology* 2005;234:961-967. Available at: <http://www.ncbi.nlm.nih.gov/pubmed/15665226>.

430. Zhang Y-J, Liang H-H, Chen M-S, et al. Hepatocellular carcinoma treated with radiofrequency ablation with or without ethanol injection: a prospective randomized trial. *Radiology* 2007;244:599-607. Available at: <http://www.ncbi.nlm.nih.gov/pubmed/17641378>.

431. Soliman H, Ringash J, Jiang H, et al. Phase II trial of palliative radiotherapy for hepatocellular carcinoma and liver metastases. *J Clin Oncol* 2013;31:3980-3986. Available at: <http://www.ncbi.nlm.nih.gov/pubmed/24062394>.

432. Llovet JM, Ricci S, Mazzaferro V, et al. Sorafenib in advanced hepatocellular carcinoma. *N Engl J Med* 2008;359:378-390. Available at: <http://www.ncbi.nlm.nih.gov/pubmed/18650514>.

433. Cheng AL, Kang YK, Chen Z, et al. Efficacy and safety of sorafenib in patients in the Asia-Pacific region with advanced hepatocellular carcinoma: a phase III randomised, double-blind, placebo-controlled trial. *Lancet Oncol* 2009;10:25-34. Available at: <http://www.ncbi.nlm.nih.gov/pubmed/19095497>.

434. Abou-Alfa GK. Selection of patients with hepatocellular carcinoma for sorafenib. *J Natl Compr Canc Netw* 2009;7:397-403. Available at: <http://www.ncbi.nlm.nih.gov/pubmed/19406040>.

435. Finn RS, Zhu AX, Farah W, et al. Therapies for advanced stage hepatocellular carcinoma with macrovascular invasion or metastatic disease: A systematic review and meta-analysis. *Hepatology* 2018;67:422-435. Available at: <https://www.ncbi.nlm.nih.gov/pubmed/28881497>.

436. Abou-Alfa GK, Schwartz L, Ricci S, et al. Phase II study of sorafenib in patients with advanced hepatocellular carcinoma. *J Clin Oncol* 2006;24:4293-4300. Available at: <http://www.ncbi.nlm.nih.gov/pubmed/16908937>.

437. Abou-Alfa GK, Amadori D, Santoro A, et al. Safety and efficacy of sorafenib in patients with hepatocellular carcinoma (HCC) and Child-Pugh A versus B cirrhosis. *Gastrointest Cancer Res* 2011;4:40-44. Available at: <http://www.ncbi.nlm.nih.gov/pubmed/21673874>.



438. Pinter M, Sieghart W, Huckle F, et al. Prognostic factors in patients with advanced hepatocellular carcinoma treated with sorafenib. *Aliment Pharmacol Ther* 2011;34:949-959. Available at: <http://www.ncbi.nlm.nih.gov/pubmed/21883324>.

439. Hollebecque A, Cattani S, Romano O, et al. Safety and efficacy of sorafenib in hepatocellular carcinoma: the impact of the Child-Pugh score. *Aliment Pharmacol Ther* 2011;34:1193-1201. Available at: <http://www.ncbi.nlm.nih.gov/pubmed/21958438>.

440. Kim JE, Ryoo BY, Ryu MH, et al. Sorafenib for hepatocellular carcinoma according to Child-Pugh class of liver function. *Cancer Chemother Pharmacol* 2011;68:1285-1290. Available at: <http://www.ncbi.nlm.nih.gov/pubmed/21445543>.

441. Lencioni R, Kudo M, Ye SL, et al. First interim analysis of the GIDEON (Global Investigation of therapeutic decisions in hepatocellular carcinoma and of its treatment with sorafenib) non-interventional study. *Int J Clin Pract* 2012;66:675-683. Available at: <http://www.ncbi.nlm.nih.gov/pubmed/22698419>.

442. Chiu J, Tang YF, Yao T-J, et al. The use of single-agent sorafenib in the treatment of advanced hepatocellular carcinoma patients with underlying Child-Pugh B liver cirrhosis: a retrospective analysis of efficacy, safety, and survival benefits. *Cancer* 2012;118:5293-5301. Available at: <http://www.ncbi.nlm.nih.gov/pubmed/22517493>.

443. Marrero JA, Lencioni R, Ye S-L, et al. Final analysis of GIDEON (Global Investigation of Therapeutic Decisions in Hepatocellular Carcinoma [HCC] and of its treatment with sorafenib [sor]) in >3000 sor-treated patients (pts): Clinical findings in pts with liver dysfunction [abstract]. *J Clin Oncol* 2013;31:Abstract 4126. Available at: [http://meeting.ascopubs.org/cgi/content/abstract/31/15\\_suppl/4126](http://meeting.ascopubs.org/cgi/content/abstract/31/15_suppl/4126).

444. Miller AA, Murry DJ, Owzar K, et al. Phase I and pharmacokinetic study of sorafenib in patients with hepatic or renal dysfunction: CALGB 60301. *J Clin Oncol* 2009;27:1800-1805. Available at: <https://www.ncbi.nlm.nih.gov/pubmed/19255312>.

445. Zhu AX, Rosmorduc O, Evans TR, et al. SEARCH: a phase III, randomized, double-blind, placebo-controlled trial of sorafenib plus erlotinib in patients with advanced hepatocellular carcinoma. *J Clin Oncol* 2015;33:559-566. Available at: <http://www.ncbi.nlm.nih.gov/pubmed/25547503>.

446. Kudo M, Finn RS, Qin S, et al. Lenvatinib versus sorafenib in first-line treatment of patients with unresectable hepatocellular carcinoma: a randomised phase 3 non-inferiority trial. *Lancet* 2018;391:1163-1173. Available at: <https://www.ncbi.nlm.nih.gov/pubmed/29433850>.

447. Finn RS, Ikeda M, Zhu AX, et al. Phase Ib study of lenvatinib plus pembrolizumab in patients with unresectable hepatocellular carcinoma. *J Clin Oncol* 2020;38:2960-2970. Available at: <https://www.ncbi.nlm.nih.gov/pubmed/32716739>.

448. Zhu AX, Blaszkowsky LS, Ryan DP, et al. Phase II study of gemcitabine and oxaliplatin in combination with bevacizumab in patients with advanced hepatocellular carcinoma. *J Clin Oncol* 2006;24:1898-1903. Available at: <http://www.ncbi.nlm.nih.gov/pubmed/16622265>.

449. Siegel AB, Cohen EI, Ocean A, et al. Phase II trial evaluating the clinical and biologic effects of bevacizumab in unresectable hepatocellular carcinoma. *J Clin Oncol* 2008;26:2992-2998. Available at: <http://www.ncbi.nlm.nih.gov/pubmed/18565886>.

450. Thomas MB, Morris JS, Chadha R, et al. Phase II trial of the combination of bevacizumab and erlotinib in patients who have advanced hepatocellular carcinoma. *J Clin Oncol* 2009;27:843-850. Available at: <http://www.ncbi.nlm.nih.gov/pubmed/19139433>.

451. Hsu CH, Yang TS, Hsu C, et al. Efficacy and tolerability of bevacizumab plus capecitabine as first-line therapy in patients with advanced hepatocellular carcinoma. *Br J Cancer* 2010;102:981-986. Available at: <http://www.ncbi.nlm.nih.gov/pubmed/20160718>.

452. Sun W, Sohal D, Haller DG, et al. Phase 2 trial of bevacizumab, capecitabine, and oxaliplatin in treatment of advanced hepatocellular



# NCCN Guidelines Version 5.2021

## Hepatobiliary Cancers

carcinoma. Cancer 2011;117:3187-3192. Available at: <http://www.ncbi.nlm.nih.gov/pubmed/21264839>.

453. Pishvaian MJ, Lee MS, Ryoo BY, et al. Updated safety and clinical activity results from a phase Ib study of atezolizumab + bevacizumab in hepatocellular carcinoma (HCC). ESMO 2018 Congress. Munich, Germany; 2018. Available at: <https://oncologypro.esmo.org/Meeting-Resources/ESMO-2018-Congress/Updated-safety-and-clinical-activity-results-from-a-Phase-Ib-study-of-atezolizumab-bevacizumab-in-hepatocellular-carcinoma-HCC>.

454. Fang P, Hu JH, Cheng ZG, et al. Efficacy and safety of bevacizumab for the treatment of advanced hepatocellular carcinoma: a systematic review of phase II trials. PLoS One 2012;7:e49717. Available at: <https://www.ncbi.nlm.nih.gov/pubmed/23284624>.

455. Finn RS, Qin S, Ikeda M, et al. Atezolizumab plus bevacizumab in unresectable hepatocellular carcinoma. N Engl J Med 2020;382:1894-1905. Available at: <https://www.ncbi.nlm.nih.gov/pubmed/32402160>.

456. Finn R, Qin S, Ikeda M, et al. IMbrave150: Updated overall survival (OS) data from a global, randomized, open-label phase III study of atezolizumab (atezo) + bevacizumab (bev) versus sorafenib (sor) in patients (pts) with unresectable hepatocellular carcinoma (HCC) [abstract]. J Clin Oncol 2021;39:Abstract 267. Available at: [https://ascopubs.org/doi/abs/10.1200/JCO.2021.39.3\\_suppl.267](https://ascopubs.org/doi/abs/10.1200/JCO.2021.39.3_suppl.267).

457. Bruix J, Qin S, Merle P, et al. Regorafenib for patients with hepatocellular carcinoma who progressed on sorafenib treatment (RESORCE): a randomised, double-blind, placebo-controlled, phase 3 trial. Lancet 2017;389:56-66. Available at: <https://www.ncbi.nlm.nih.gov/pubmed/27932229>.

458. Abou-Alfa GK, Meyer T, Cheng AL, et al. Cabozantinib in patients with advanced and progressing hepatocellular carcinoma. N Engl J Med 2018;379:54-63. Available at: <https://www.ncbi.nlm.nih.gov/pubmed/29972759>.

459. Kelley RK, Meyer T, Rimassa L, et al. Serum Alpha-fetoprotein Levels and Clinical Outcomes in the Phase III CELESTIAL Study of Cabozantinib versus Placebo in Patients with Advanced Hepatocellular Carcinoma. Clin Cancer Res 2020;26:4795-4804. Available at: <https://www.ncbi.nlm.nih.gov/pubmed/32636319>.

460. Zhu AX, Park JO, Ryoo BY, et al. Ramucirumab versus placebo as second-line treatment in patients with advanced hepatocellular carcinoma following first-line therapy with sorafenib (REACH): a randomised, double-blind, multicentre, phase 3 trial. Lancet Oncol 2015;16:859-870. Available at: <http://www.ncbi.nlm.nih.gov/pubmed/26095784>.

461. Chau I, Peck-Radosavljevic M, Borg C, et al. Ramucirumab as second-line treatment in patients with advanced hepatocellular carcinoma following first-line therapy with sorafenib: Patient-focused outcome results from the randomised phase III REACH study. Eur J Cancer 2017;81:17-25. Available at: <https://www.ncbi.nlm.nih.gov/pubmed/28591675>.

462. Zhu AX, Kang YK, Yen CJ, et al. Ramucirumab after sorafenib in patients with advanced hepatocellular carcinoma and increased alpha-fetoprotein concentrations (REACH-2): a randomised, double-blind, placebo-controlled, phase 3 trial. Lancet Oncol 2019;20:282-296. Available at: <https://www.ncbi.nlm.nih.gov/pubmed/30665869>.

463. Zhu AX, Finn RS, Kang YK, et al. Serum alpha-fetoprotein and clinical outcomes in patients with advanced hepatocellular carcinoma treated with ramucirumab. Br J Cancer 2021;124:1388-1397. Available at: <https://www.ncbi.nlm.nih.gov/pubmed/33531690>.

464. FDA grants accelerated approval to nivolumab for HCC previously treated with sorafenib. 2017. Available at: <https://www.fda.gov/drugs/resources-information-approved-drugs/fda-grants-accelerated-approval-nivolumab-hcc-previously-treated-sorafenib>. Accessed July 30, 2021.

465. Yau T, Park JW, Finn RS, et al. CheckMate 459: a randomized, multicenter phase 3 study of nivolumab (NIVO) vs sorafenib (SOR) as first-line (1L) treatment in patients (pts) with advanced hepatocellular carcinoma





# NCCN Guidelines Version 5.2021

## Hepatobiliary Cancers

[abstract]. Ann Oncol 2019;30:Abstract LBA38\_PR. Available at: [https://www.annalsofncology.org/article/S0923-7534\(19\)60389-3/fulltext](https://www.annalsofncology.org/article/S0923-7534(19)60389-3/fulltext).

466. Bristol Myers Squibb statement on Opdivo® (nivolumab) monotherapy post-sorafenib hepatocellular carcinoma U.S. indication. 2021. Available at: <https://news.bms.com/news/corporate-financial/2021/Bristol-Myers-Squibb-Statement-on-Opdivo-nivolumab-Monotherapy-Post-Sorafenib-Hepatocellular-Carcinoma-U.S.-Indication/default.aspx>. Accessed July 30, 2021.

467. Yau T, Kang YK, Kim TY, et al. Efficacy and safety of nivolumab plus ipilimumab in patients with advanced hepatocellular carcinoma previously treated with sorafenib: The CheckMate 040 randomized clinical trial. JAMA Oncol 2020. Available at: <https://www.ncbi.nlm.nih.gov/pubmed/33001135>.

468. El-Khoueiry A, Yau T, Kang Y-K, et al. Nivolumab (NIVO) plus ipilimumab (IPI) combination therapy in patients (Pts) with advanced hepatocellular carcinoma (aHCC): Long-term results from CheckMate 040 [abstract]. J Clin Oncol 2021;39:Abstract 269. Available at: [https://ascopubs.org/doi/abs/10.1200/JCO.2021.39.3\\_suppl.269](https://ascopubs.org/doi/abs/10.1200/JCO.2021.39.3_suppl.269).

469. Zhu AX, Finn RS, Edeline J, et al. Pembrolizumab in patients with advanced hepatocellular carcinoma previously treated with sorafenib (KEYNOTE-224): a non-randomised, open-label phase 2 trial. Lancet Oncol 2018;19:940-952. Available at: <https://www.ncbi.nlm.nih.gov/pubmed/29875066>.

470. Finn RS, Ryoo BY, Merle P, et al. Pembrolizumab as second-line therapy in patients with advanced hepatocellular carcinoma in KEYNOTE-240: A randomized, double-blind, phase III trial. J Clin Oncol 2020;38:193-202. Available at: <https://www.ncbi.nlm.nih.gov/pubmed/31790344>.

471. Merle P, Edeline J, Bouattour M, et al. Pembrolizumab (pembro) vs placebo (pbo) in patients (pts) with advanced hepatocellular carcinoma (aHCC) previously treated with sorafenib: Updated data from the randomized, phase III KEYNOTE-240 study [abstract]. J Clin Oncol 2021;39:Abstract 268. Available at: [https://ascopubs.org/doi/abs/10.1200/JCO.2021.39.3\\_suppl.268](https://ascopubs.org/doi/abs/10.1200/JCO.2021.39.3_suppl.268).

472. Berton D, Banerjee SN, Curigliano G, et al. Antitumor activity of dostarlimab in patients with mismatch repair-deficient/microsatellite instability-high tumors: A combined analysis of two cohorts in the GARNET study [abstract]. J Clin Oncol 2021;39:Abstract 2564. Available at: [https://ascopubs.org/doi/abs/10.1200/JCO.2021.39.15\\_suppl.2564](https://ascopubs.org/doi/abs/10.1200/JCO.2021.39.15_suppl.2564).

473. Andre T, Berton D, Curigliano G, et al. Safety and efficacy of anti-PD-1 antibody dostarlimab in patients (pts) with mismatch repair-deficient (dMMR) solid cancers: Results from GARNET study [abstract]. J Clin Oncol 2021;39:Abstract 9. Available at: [https://ascopubs.org/doi/abs/10.1200/JCO.2021.39.3\\_suppl.9](https://ascopubs.org/doi/abs/10.1200/JCO.2021.39.3_suppl.9).

474. Qin S, Bai Y, Lim HY, et al. Randomized, multicenter, open-label study of oxaliplatin plus fluorouracil/leucovorin versus doxorubicin as palliative chemotherapy in patients with advanced hepatocellular carcinoma from Asia. J Clin Oncol 2013;31:3501-3508. Available at: <https://www.ncbi.nlm.nih.gov/pubmed/23980077>.

475. Qin S, Cheng Y, Liang J, et al. Efficacy and safety of the FOLFOX4 regimen versus doxorubicin in Chinese patients with advanced hepatocellular carcinoma: a subgroup analysis of the EACH study. Oncologist 2014;19:1169-1178. Available at: <https://www.ncbi.nlm.nih.gov/pubmed/25223462>.

476. Goyal L, Zheng H, Abrams TA, et al. A phase II and biomarker study of sorafenib combined with modified FOLFOX in patients with advanced hepatocellular carcinoma. Clin Cancer Res 2019;25:80-89. Available at: <https://www.ncbi.nlm.nih.gov/pubmed/30190369>.

477. Cainap C, Qin S, Huang WT, et al. Linifanib versus Sorafenib in patients with advanced hepatocellular carcinoma: results of a randomized phase III trial. J Clin Oncol 2015;33:172-179. Available at: <http://www.ncbi.nlm.nih.gov/pubmed/25488963>.

478. Rimassa L, Assenat E, Peck-Radosavljevic M, et al. Tivantinib for second-line treatment of MET-high, advanced hepatocellular carcinoma (METIV-HCC): a final analysis of a phase 3, randomised, placebo-controlled study. Lancet Oncol 2018;19:682-693. Available at: <https://www.ncbi.nlm.nih.gov/pubmed/29625879>.





# NCCN Guidelines Version 5.2021

## Hepatobiliary Cancers

479. Santoro A, Rimassa L, Borbath I, et al. Tivantinib for second-line treatment of advanced hepatocellular carcinoma: a randomised, placebo-controlled phase 2 study. *Lancet Oncol* 2013;14:55-63. Available at: <https://www.ncbi.nlm.nih.gov/pubmed/23182627>.

480. Kang YK, Yau T, Park JW, et al. Randomized phase II study of axitinib versus placebo plus best supportive care in second-line treatment of advanced hepatocellular carcinoma. *Ann Oncol* 2015;26:2457-2463. Available at: <https://www.ncbi.nlm.nih.gov/pubmed/26386123>.

481. Li Q, Qin S, Gu S, et al. Apatinib as second-line therapy in Chinese patients with advanced hepatocellular carcinoma: A randomized, placebo-controlled, double-blind, phase III study [abstract]. *J Clin Oncol* 2020;38:Abstract 4507. Available at: [https://ascopubs.org/doi/abs/10.1200/JCO.2020.38.15\\_suppl.4507](https://ascopubs.org/doi/abs/10.1200/JCO.2020.38.15_suppl.4507).

482. Sia D, Tovar V, Moeini A, Llovet JM. Intrahepatic cholangiocarcinoma: pathogenesis and rationale for molecular therapies. *Oncogene* 2013;32:4861-4870. Available at: <http://www.ncbi.nlm.nih.gov/pubmed/23318457>.

483. Galuppo R, Ramaiah D, Ponte OM, Gedaly R. Molecular therapies in hepatocellular carcinoma: what can we target? *Dig Dis Sci* 2014;59:1688-1697. Available at: <http://www.ncbi.nlm.nih.gov/pubmed/24573715>.

484. Liu H, Wang ZG, Fu SY, et al. Randomized clinical trial of chemoembolization plus radiofrequency ablation versus partial hepatectomy for hepatocellular carcinoma within the Milan criteria. *Br J Surg* 2016;103:348-356. Available at: <https://www.ncbi.nlm.nih.gov/pubmed/26780107>.

485. Hyun MH, Lee YS, Kim JH, et al. Hepatic resection compared to chemoembolization in intermediate- to advanced-stage hepatocellular carcinoma: A meta-analysis of high-quality studies. *Hepatology* 2018;68:977-993. Available at: <https://www.ncbi.nlm.nih.gov/pubmed/29543988>.

486. Volk ML, Hernandez JC, Lok AS, Marrero JA. Modified Charlson comorbidity index for predicting survival after liver transplantation. *Liver*

*Transpl* 2007;13:1515-1520. Available at: <http://www.ncbi.nlm.nih.gov/pubmed/17969207>.

487. Utsunomiya T, Shimada M, Kudo M, et al. Nationwide study of 4741 patients with non-B non-C hepatocellular carcinoma with special reference to the therapeutic impact. *Ann Surg* 2014;259:336-345. Available at: <http://www.ncbi.nlm.nih.gov/pubmed/23673768>.

488. Roayaie S, Blume IN, Thung SN, et al. A system of classifying microvascular invasion to predict outcome after resection in patients with hepatocellular carcinoma. *Gastroenterology* 2009;137:850-855. Available at: <https://www.ncbi.nlm.nih.gov/pubmed/19524573>.

489. Sumie S, Nakashima O, Okuda K, et al. The significance of classifying microvascular invasion in patients with hepatocellular carcinoma. *Ann Surg Oncol* 2014;21:1002-1009. Available at: <https://www.ncbi.nlm.nih.gov/pubmed/24254204>.

490. Park H, Park JY. Clinical significance of AFP and PIVKA-II responses for monitoring treatment outcomes and predicting prognosis in patients with hepatocellular carcinoma. *Biomed Res Int* 2013;2013:310427. Available at: <https://www.ncbi.nlm.nih.gov/pubmed/24455683>.

491. Figueras J, Ibanez L, Ramos E, et al. Selection criteria for liver transplantation in early-stage hepatocellular carcinoma with cirrhosis: results of a multicenter study. *Liver Transpl* 2001;7:877-883. Available at: <https://www.ncbi.nlm.nih.gov/pubmed/11679986>.

492. Mirici-Cappa F, Gramenzi A, Santi V, et al. Treatments for hepatocellular carcinoma in elderly patients are as effective as in younger patients: a 20-year multicentre experience. *Gut* 2010;59:387-396. Available at: <https://www.ncbi.nlm.nih.gov/pubmed/20207642>.

493. Ozenne V, Bouattour M, Goutte N, et al. Prospective evaluation of the management of hepatocellular carcinoma in the elderly. *Dig Liver Dis* 2011;43:1001-1005. Available at: <https://www.ncbi.nlm.nih.gov/pubmed/21798829>.



# NCCN Guidelines Version 5.2021

## Hepatobiliary Cancers

494. Marabelle A, Le DT, Ascierto PA, et al. Efficacy of pembrolizumab in patients with noncolorectal high microsatellite instability/mismatch repair-deficient cancer: Results from the phase II KEYNOTE-158 study. *J Clin Oncol* 2020;38:1-10. Available at: <https://www.ncbi.nlm.nih.gov/pubmed/31682550>.

495. El-Khoueiry AB, Sangro B, Yau T, et al. Nivolumab in patients with advanced hepatocellular carcinoma (CheckMate 040): an open-label, non-comparative, phase 1/2 dose escalation and expansion trial. *Lancet* 2017;389:2492-2502. Available at: <https://www.ncbi.nlm.nih.gov/pubmed/28434648>.

496. Kambhampati S, Bauer KE, Bracci PM, et al. Nivolumab in patients with advanced hepatocellular carcinoma and Child-Pugh class B cirrhosis: safety and clinical outcomes in a retrospective case series. *Cancer* 2019;125:3234-3241. Available at: <https://www.ncbi.nlm.nih.gov/pubmed/31154669>.

497. Kudo M, Matilla A, Santoro A, et al. Checkmate-040: nivolumab (NIVO) in patients (pts) with advanced hepatocellular carcinoma (aHCC) and Child-Pugh B (CPB) status. *J Clin Oncol* 2019;37:327-327. Available at: [https://ascopubs.org/doi/abs/10.1200/JCO.2019.37.4\\_suppl.327](https://ascopubs.org/doi/abs/10.1200/JCO.2019.37.4_suppl.327).

498. Kudo M, Okusaka T, Motomura K, et al. Ramucirumab after prior sorafenib in patients with advanced hepatocellular carcinoma and elevated alpha-fetoprotein: Japanese subgroup analysis of the REACH-2 trial. *J Gastroenterol* 2020;55:627-639. Available at: <https://www.ncbi.nlm.nih.gov/pubmed/32107609>.

499. Levy AD, Murakata LA, Rohrmann CA, Jr. Gallbladder carcinoma: radiologic-pathologic correlation. *Radiographics* 2001;21:295-314; questionnaire, 549-255. Available at: <http://www.ncbi.nlm.nih.gov/pubmed/11259693>.

500. Henley SJ, Weir HK, Jim MA, et al. Gallbladder cancer incidence and mortality, United States 1999-2011. *Cancer Epidemiol Biomarkers Prev* 2015;24:1319-1326. Available at: <https://www.ncbi.nlm.nih.gov/pubmed/26070529>.

501. Van Dyke AL, Shiels MS, Jones GS, et al. Biliary tract cancer incidence and trends in the United States by demographic group, 1999-2013. *Cancer* 2019;125:1489-1498. Available at: <https://www.ncbi.nlm.nih.gov/pubmed/30645774>.

502. Randi G, Franceschi S, La Vecchia C. Gallbladder cancer worldwide: geographical distribution and risk factors. *Int J Cancer* 2006;118:1591-1602. Available at: <http://www.ncbi.nlm.nih.gov/pubmed/16397865>.

503. Lazcano-Ponce EC, Miquel JF, Munoz N, et al. Epidemiology and molecular pathology of gallbladder cancer. *CA Cancer J Clin* 2001;51:349-364. Available at: <http://www.ncbi.nlm.nih.gov/pubmed/11760569>.

504. Miranda-Filho A, Pineros M, Ferreccio C, et al. Gallbladder and extrahepatic bile duct cancers in the Americas: Incidence and mortality patterns and trends. *Int J Cancer* 2020;147:978-989. Available at: <https://www.ncbi.nlm.nih.gov/pubmed/31922259>.

505. Jarnagin WR, Ruo L, Little SA, et al. Patterns of initial disease recurrence after resection of gallbladder carcinoma and hilar cholangiocarcinoma: implications for adjuvant therapeutic strategies. *Cancer* 2003;98:1689-1700. Available at: <http://www.ncbi.nlm.nih.gov/pubmed/14534886>.

506. Sheth S, Bedford A, Chopra S. Primary gallbladder cancer: recognition of risk factors and the role of prophylactic cholecystectomy. *Am J Gastroenterol* 2000;95:1402-1410. Available at: <http://www.ncbi.nlm.nih.gov/pubmed/10894571>.

507. Tazuma S, Kajiyama G. Carcinogenesis of malignant lesions of the gall bladder. The impact of chronic inflammation and gallstones. *Langenbecks Arch Surg* 2001;386:224-229. Available at: <http://www.ncbi.nlm.nih.gov/pubmed/11382326>.

508. Khan ZS, Livingston EH, Huerta S. Reassessing the need for prophylactic surgery in patients with porcelain gallbladder: case series and systematic review of the literature. *Arch Surg* 2011;146:1143-1147. Available at: <http://www.ncbi.nlm.nih.gov/pubmed/22006872>.



# NCCN Guidelines Version 5.2021

## Hepatobiliary Cancers

509. Schnelladorfer T. Porcelain gallbladder: a benign process or concern for malignancy? J Gastrointest Surg 2013. Available at: <http://www.ncbi.nlm.nih.gov/pubmed/23423431>.

510. Stephen AE, Berger DL. Carcinoma in the porcelain gallbladder: a relationship revisited. Surgery 2001;129:699-703. Available at: <http://www.ncbi.nlm.nih.gov/pubmed/11391368>.

511. Elnemr A, Ohta T, Kayahara M, et al. Anomalous pancreaticobiliary ductal junction without bile duct dilatation in gallbladder cancer. Hepatogastroenterology 2001;48:382-386. Available at: <http://www.ncbi.nlm.nih.gov/pubmed/11379314>.

512. Reid KM, Ramos-De la Medina A, Donohue JH. Diagnosis and surgical management of gallbladder cancer: a review. J Gastrointest Surg 2007;11:671-681. Available at: <http://www.ncbi.nlm.nih.gov/pubmed/17468929>.

513. Hundal R, Shaffer EA. Gallbladder cancer: epidemiology and outcome. Clin Epidemiol 2014;6:99-109. Available at: <https://www.ncbi.nlm.nih.gov/pubmed/24634588>.

514. Williams AS, Huang WY. The analysis of microsatellite instability in extracolonic gastrointestinal malignancy. Pathology 2013;45:540-552. Available at: <https://www.ncbi.nlm.nih.gov/pubmed/24018804>.

515. Roa I, de Toro G, Schalper K, et al. Overexpression of the HER2/neu gene: a new therapeutic possibility for patients with advanced gallbladder cancer. Gastrointest Cancer Res 2014;7:42-48. Available at: <https://www.ncbi.nlm.nih.gov/pubmed/24799970>.

516. Shindoh J, de Aretxabala X, Aloia TA, et al. Tumor location is a strong predictor of tumor progression and survival in T2 gallbladder cancer: an international multicenter study. Ann Surg 2015;261:733-739. Available at: <https://www.ncbi.nlm.nih.gov/pubmed/24854451>.

517. Lee H, Choi DW, Park JY, et al. Surgical strategy for T2 gallbladder cancer according to tumor location. Ann Surg Oncol 2015;22:2779-2786. Available at: <https://www.ncbi.nlm.nih.gov/pubmed/25519930>.

518. Donohue JH, Stewart AK, Menck HR. The National Cancer Data Base report on carcinoma of the gallbladder, 1989-1995. Cancer 1998;83:2618-2628. Available at: <http://www.ncbi.nlm.nih.gov/pubmed/9874470>.

519. Duffy A, Capanu M, Abou-Alfa GK, et al. Gallbladder cancer (GBC): 10-year experience at Memorial Sloan-Kettering Cancer Centre (MSKCC). J Surg Oncol 2008;98:485-489. Available at: <http://www.ncbi.nlm.nih.gov/pubmed/18802958>.

520. Ito H, Ito K, D'Angelica M, et al. Accurate staging for gallbladder cancer: implications for surgical therapy and pathological assessment. Ann Surg 2011;254:320-325. Available at: <http://www.ncbi.nlm.nih.gov/pubmed/21617582>.

521. Hawkins WG, DeMatteo RP, Jarnagin WR, et al. Jaundice predicts advanced disease and early mortality in patients with gallbladder cancer. Ann Surg Oncol 2004;11:310-315. Available at: <http://www.ncbi.nlm.nih.gov/pubmed/14993027>.

522. Furlan A, Ferris JV, Hosseinzadeh K, Borhani AA. Gallbladder carcinoma update: multimodality imaging evaluation, staging, and treatment options. AJR Am J Roentgenol 2008;191:1440-1447. Available at: <http://www.ncbi.nlm.nih.gov/pubmed/18941083>.

523. de Savornin Lohman EAJ, de Bitter TJJ, van Laarhoven C, et al. The diagnostic accuracy of CT and MRI for the detection of lymph node metastases in gallbladder cancer: A systematic review and meta-analysis. Eur J Radiol 2019;110:156-162. Available at: <https://www.ncbi.nlm.nih.gov/pubmed/30599854>.

524. Petrowsky H, Wildbrett P, Husarik DB, et al. Impact of integrated positron emission tomography and computed tomography on staging and management of gallbladder cancer and cholangiocarcinoma. J Hepatol 2006;45:43-50. Available at: <http://www.ncbi.nlm.nih.gov/pubmed/16690156>.

525. Corvera CU, Blumgart LH, Akhurst T, et al. 18F-fluorodeoxyglucose positron emission tomography influences management decisions in



patients with biliary cancer. J Am Coll Surg 2008;206:57-65. Available at: <http://www.ncbi.nlm.nih.gov/pubmed/18155569>.

526. Lee SW, Kim HJ, Park JH, et al. Clinical usefulness of 18F-FDG PET-CT for patients with gallbladder cancer and cholangiocarcinoma. J Gastroenterol 2010;45:560-566. Available at: <http://www.ncbi.nlm.nih.gov/pubmed/20035356>.

527. Lamarca A, Barriuso J, Chander A, et al. (18)F-fluorodeoxyglucose positron emission tomography ((18)FDG-PET) for patients with biliary tract cancer: Systematic review and meta-analysis. J Hepatol 2019;71:115-129. Available at: <https://www.ncbi.nlm.nih.gov/pubmed/30797051>.

528. Strom BL, Maislin G, West SL, et al. Serum CEA and CA 19-9: potential future diagnostic or screening tests for gallbladder cancer? Int J Cancer 1990;45:821-824. Available at: <http://www.ncbi.nlm.nih.gov/pubmed/2335386>.

529. Dixon E, Vollmer CM, Jr., Sahajpal A, et al. An aggressive surgical approach leads to improved survival in patients with gallbladder cancer: a 12-year study at a North American Center. Ann Surg 2005;241:385-394. Available at: <http://www.ncbi.nlm.nih.gov/pubmed/15729060>.

530. Fuks D, Regimbeau JM, Le Treut YP, et al. Incidental gallbladder cancer by the AFC-GBC-2009 Study Group. World J Surg 2011;35:1887-1897. Available at: <http://www.ncbi.nlm.nih.gov/pubmed/21547420>.

531. Lee SE, Jang JY, Lim CS, et al. Systematic review on the surgical treatment for T1 gallbladder cancer. World J Gastroenterol 2011;17:174-180. Available at: <http://www.ncbi.nlm.nih.gov/pubmed/21245989>.

532. Foster JM, Hoshi H, Gibbs JF, et al. Gallbladder cancer: Defining the indications for primary radical resection and radical re-resection. Ann Surg Oncol 2007;14:833-840. Available at: <http://www.ncbi.nlm.nih.gov/pubmed/17103074>.

533. Coburn NG, Cleary SP, Tan JC, Law CH. Surgery for gallbladder cancer: a population-based analysis. J Am Coll Surg 2008;207:371-382. Available at: <http://www.ncbi.nlm.nih.gov/pubmed/18722943>.

534. You DD, Lee HG, Paik KY, et al. What is an adequate extent of resection for T1 gallbladder cancers? Ann Surg 2008;247:835-838. Available at: <http://www.ncbi.nlm.nih.gov/pubmed/18438121>.

535. Jensen EH, Abraham A, Habermann EB, et al. A critical analysis of the surgical management of early-stage gallbladder cancer in the United States. J Gastrointest Surg 2009;13:722-727. Available at: <http://www.ncbi.nlm.nih.gov/pubmed/19083068>.

536. Downing Sr CKOG, et al. Early-stage gallbladder cancer in the surveillance, epidemiology, and end results database: Effect of extended surgical resection. Archives of Surgery 2011;146:734-738. Available at: <http://www.ncbi.nlm.nih.gov/pubmed/21690451>.

537. Shirai Y, Sakata J, Wakai T, et al. "Extended" radical cholecystectomy for gallbladder cancer: long-term outcomes, indications and limitations. World J Gastroenterol 2012;18:4736-4743. Available at: <http://www.ncbi.nlm.nih.gov/pubmed/23002343>.

538. Widmann B, Warschkow R, Beutner U, et al. Effect of lymphadenectomy in curative gallbladder cancer treatment: a systematic review and meta-analysis. Langenbecks Arch Surg 2020;405:573-584. Available at: <https://www.ncbi.nlm.nih.gov/pubmed/32458141>.

539. D'Angelica M, Dalal KM, DeMatteo RP, et al. Analysis of the extent of resection for adenocarcinoma of the gallbladder. Ann Surg Oncol 2009;16:806-816. Available at: <http://www.ncbi.nlm.nih.gov/pubmed/18985272>.

540. Gani F, Buettner S, Margonis GA, et al. Assessing the impact of common bile duct resection in the surgical management of gallbladder cancer. J Surg Oncol 2016;114:176-180. Available at: <https://www.ncbi.nlm.nih.gov/pubmed/27198742>.

541. Pawlik TM, Gleisner AL, Vigano L, et al. Incidence of finding residual disease for incidental gallbladder carcinoma: implications for re-resection. J Gastrointest Surg 2007;11:1478-1486; discussion 1486-1477. Available at: <http://www.ncbi.nlm.nih.gov/pubmed/17846848>.





542. Fong Y, Jarnagin W, Blumgart LH. Gallbladder cancer: comparison of patients presenting initially for definitive operation with those presenting after prior noncurative intervention. *Ann Surg* 2000;232:557-569. Available at: <http://www.ncbi.nlm.nih.gov/pubmed/10998654>.

543. Shih SP, Schulick RD, Cameron JL, et al. Gallbladder cancer: the role of laparoscopy and radical resection. *Ann Surg* 2007;245:893-901. Available at: <http://www.ncbi.nlm.nih.gov/pubmed/17522515>.

544. Agarwal AK, Kalayarsan R, Javed A, et al. Role of staging laparoscopy in primary gall bladder cancer-an analysis of 409 patients: a prospective study to evaluate the role of staging laparoscopy in the management of gallbladder cancer. *Ann Surg* 2012. Available at: <http://www.ncbi.nlm.nih.gov/pubmed/23059504>.

545. Butte JM, Gonen M, Allen PJ, et al. The role of laparoscopic staging in patients with incidental gallbladder cancer. *HPB (Oxford)* 2011;13:463-472. Available at: <http://www.ncbi.nlm.nih.gov/pubmed/21689230>.

546. Maker AV, Butte JM, Oxenberg J, et al. Is port site resection necessary in the surgical management of gallbladder cancer? *Ann Surg Oncol* 2012;19:409-417. Available at: <http://www.ncbi.nlm.nih.gov/pubmed/21698501>.

547. Fuks D, Regimbeau JM, Pessaux P, et al. Is port-site resection necessary in the surgical management of gallbladder cancer? *J Visc Surg* 2013. Available at: <http://www.ncbi.nlm.nih.gov/pubmed/23665059>.

548. Regimbeau JM, Fuks D, Bachellier P, et al. Prognostic value of jaundice in patients with gallbladder cancer by the AFC-GBC-2009 study group. *Eur J Surg Oncol* 2011;37:505-512. Available at: <http://www.ncbi.nlm.nih.gov/pubmed/21514090>.

549. Nishio H, Ebata T, Yokoyama Y, et al. Gallbladder cancer involving the extrahepatic bile duct is worthy of resection. *Ann Surg* 2011;253:953-960. Available at: <https://www.ncbi.nlm.nih.gov/pubmed/21490453>.

550. Dasari BVM, Ionescu MI, Pawlik TM, et al. Outcomes of surgical resection of gallbladder cancer in patients presenting with jaundice: A

systematic review and meta-analysis. *J Surg Oncol* 2018;118:477-485. Available at: <https://www.ncbi.nlm.nih.gov/pubmed/30259519>.

551. Hakeem AR, Papoulas M, Menon KV. The role of neoadjuvant chemotherapy or chemoradiotherapy for advanced gallbladder cancer - A systematic review. *Eur J Surg Oncol* 2019;45:83-91. Available at: <https://www.ncbi.nlm.nih.gov/pubmed/30287098>.

552. Creasy JM, Goldman DA, Dudeja V, et al. Systemic chemotherapy combined with resection for locally advanced gallbladder carcinoma: surgical and survival outcomes. *J Am Coll Surg* 2017;224:906-916. Available at: <https://www.ncbi.nlm.nih.gov/pubmed/28216422>.

553. Engineer R, Goel M, Chopra S, et al. Neoadjuvant chemoradiation followed by surgery for locally advanced gallbladder cancers: a new paradigm. *Ann Surg Oncol* 2016;23:3009-3015. Available at: <https://www.ncbi.nlm.nih.gov/pubmed/27075323>.

554. Merino DM, McShane LM, Fabrizio D, et al. Establishing guidelines to harmonize tumor mutational burden (TMB): in silico assessment of variation in TMB quantification across diagnostic platforms: phase I of the Friends of Cancer Research TMB Harmonization Project. *J Immunother Cancer* 2020;8. Available at: <https://www.ncbi.nlm.nih.gov/pubmed/32217756>.

555. Le DT, Durham JN, Smith KN, et al. Mismatch repair deficiency predicts response of solid tumors to PD-1 blockade. *Science* 2017;357:409-413. Available at: <https://www.ncbi.nlm.nih.gov/pubmed/28596308>.

556. Le DT, Uram JN, Wang H, et al. PD-1 blockade in tumors with mismatch-repair deficiency. *N Engl J Med* 2015;372:2509-2520. Available at: <https://www.ncbi.nlm.nih.gov/pubmed/26028255>.

557. Lim JH. Cholangiocarcinoma: morphologic classification according to growth pattern and imaging findings. *AJR Am J Roentgenol* 2003;181:819-827. Available at: <http://www.ncbi.nlm.nih.gov/pubmed/12933488>.





558. Saha SK, Zhu AX, Fuchs CS, Brooks GA. Forty-year trends in cholangiocarcinoma incidence in the U.S.: intrahepatic disease on the rise. *Oncologist* 2016;21:594-599. Available at: <https://www.ncbi.nlm.nih.gov/pubmed/27000463>.

559. Mukkamalla SKR, Naseri HM, Kim BM, et al. Trends in incidence and factors affecting survival of patients with cholangiocarcinoma in the United States. *J Natl Compr Canc Netw* 2018;16:370-376. Available at: <https://www.ncbi.nlm.nih.gov/pubmed/29632056>.

560. DeOliveira ML, Cunningham SC, Cameron JL, et al. Cholangiocarcinoma: thirty-one-year experience with 564 patients at a single institution. *Ann Surg* 2007;245:755-762. Available at: <http://www.ncbi.nlm.nih.gov/pubmed/17457168>.

561. Chapman RW. Risk factors for biliary tract carcinogenesis. *Ann Oncol* 1999;10 Suppl 4:308-311. Available at: <http://www.ncbi.nlm.nih.gov/pubmed/10436847>.

562. Tyson GL, El-Serag HB. Risk factors for cholangiocarcinoma. *Hepatology* 2011;54:173-184. Available at: <http://www.ncbi.nlm.nih.gov/pubmed/21488076>.

563. Huai JP, Ding J, Ye XH, Chen YP. Inflammatory bowel disease and risk of cholangiocarcinoma: evidence from a meta-analysis of population-based studies. *Asian Pac J Cancer Prev* 2014;15:3477-3482. Available at: <https://www.ncbi.nlm.nih.gov/pubmed/24870743>.

564. Welzel TM, Graubard BI, El-Serag HB, et al. Risk factors for intrahepatic and extrahepatic cholangiocarcinoma in the United States: a population-based case-control study. *Clin Gastroenterol Hepatol* 2007;5:1221-1228. Available at: <http://www.ncbi.nlm.nih.gov/pubmed/17689296>.

565. Clements O, Eliahoo J, Kim JU, et al. Risk factors for intrahepatic and extrahepatic cholangiocarcinoma: A systematic review and meta-analysis. *J Hepatol* 2020;72:95-103. Available at: <https://www.ncbi.nlm.nih.gov/pubmed/31536748>.

566. Chang K-Y, Chang J-Y, Yen Y. Increasing incidence of intrahepatic cholangiocarcinoma and its relationship to chronic viral hepatitis. *J Natl Compr Canc Netw* 2009;7:423-427. Available at: <http://www.ncbi.nlm.nih.gov/pubmed/19406042>.

567. Wongjarupong N, Assavapongpaiboon B, Susantitaphong P, et al. Non-alcoholic fatty liver disease as a risk factor for cholangiocarcinoma: a systematic review and meta-analysis. *BMC Gastroenterol* 2017;17:149. Available at: <https://www.ncbi.nlm.nih.gov/pubmed/29216833>.

568. Endo I, Gonen M, Yopp AC, et al. Intrahepatic cholangiocarcinoma: rising frequency, improved survival, and determinants of outcome after resection. *Ann Surg* 2008;248:84-96. Available at: <http://www.ncbi.nlm.nih.gov/pubmed/18580211>.

569. Nathan H, Aloia TA, Vauthey J-N, et al. A proposed staging system for intrahepatic cholangiocarcinoma. *Ann Surg Oncol* 2009;16:14-22. Available at: <http://www.ncbi.nlm.nih.gov/pubmed/18987916>.

570. de Jong MC, Nathan H, Sotiropoulos GC, et al. Intrahepatic cholangiocarcinoma: an international multi-institutional analysis of prognostic factors and lymph node assessment. *J Clin Oncol* 2011;29:3140-3145. Available at: <http://www.ncbi.nlm.nih.gov/pubmed/21730269>.

571. Edge SB, Byrd DR, Compton CC, et al. *AJCC Cancer Staging Manual* (ed 7). New York, NY: Springer; 2010.

572. Farges O, Fuks D, Le Treut Y-P, et al. AJCC 7th edition of TNM staging accurately discriminates outcomes of patients with resectable intrahepatic cholangiocarcinoma. *Cancer* 2011;117:2170-2177. Available at: <http://www.ncbi.nlm.nih.gov/pubmed/21523730>.

573. de Jong MC, Hong S-M, Augustine MM, et al. Hilar cholangiocarcinoma: tumor depth as a predictor of outcome. *Arch Surg* 2011;146:697-703. Available at: <http://www.ncbi.nlm.nih.gov/pubmed/21690446>.



574. Hong S-M, Pawlik TM, Cho H, et al. Depth of tumor invasion better predicts prognosis than the current American Joint Committee on Cancer T classification for distal bile duct carcinoma. *Surgery* 2009;146:250-257. Available at: <http://www.ncbi.nlm.nih.gov/pubmed/19628081>.

575. Bismuth H, Nakache R, Diamond T. Management strategies in resection for hilar cholangiocarcinoma. *Ann Surg* 1992;215:31-38. Available at: <http://www.ncbi.nlm.nih.gov/pubmed/1309988>.

576. Jarnagin WR, Fong Y, DeMatteo RP, et al. Staging, resectability, and outcome in 225 patients with hilar cholangiocarcinoma. *Ann Surg* 2001;234:507-517; discussion 517-509. Available at: <http://www.ncbi.nlm.nih.gov/pubmed/11573044>.

577. Matsuo K, Rocha FG, Ito K, et al. The Blumgart preoperative staging system for hilar cholangiocarcinoma: analysis of resectability and outcomes in 380 patients. *J Am Coll Surg* 2012;215:343-355. Available at: <http://www.ncbi.nlm.nih.gov/pubmed/22749003>.

578. Aljiffry M, Walsh MJ, Molinari M. Advances in diagnosis, treatment and palliation of cholangiocarcinoma: 1990-2009. *World J Gastroenterol* 2009;15:4240-4262. Available at: <http://www.ncbi.nlm.nih.gov/pubmed/19750567>.

579. Mann DV, Edwards R, Ho S, et al. Elevated tumour marker CA19-9: clinical interpretation and influence of obstructive jaundice. *Eur J Surg Oncol* 2000;26:474-479. Available at: <http://www.ncbi.nlm.nih.gov/pubmed/11016469>.

580. Hwang JP, Feld JJ, Hammond SP, et al. Hepatitis B Virus Screening and Management for Patients With Cancer Prior to Therapy: ASCO Provisional Clinical Opinion Update. *J Clin Oncol* 2020;38:3698-3715. Available at: <https://ascopubs.org/doi/pdf/10.1200/JCO.20.01757>.

581. Fowler KJ, Potretzke TA, Hope TA, et al. LI-RADS M (LR-M): definite or probable malignancy, not specific for hepatocellular carcinoma. *Abdom Radiol (NY)* 2018;43:149-157. Available at: <https://www.ncbi.nlm.nih.gov/pubmed/28580538>.

582. Heimbach JK, Sanchez W, Rosen CB, Gores GJ. Trans-peritoneal fine needle aspiration biopsy of hilar cholangiocarcinoma is associated with disease dissemination. *HPB (Oxford)* 2011;13:356-360. Available at: <https://www.ncbi.nlm.nih.gov/pubmed/21492336>.

583. Sainani NI, Catalano OA, Holalkere NS, et al. Cholangiocarcinoma: current and novel imaging techniques. *Radiographics* 2008;28:1263-1287. Available at: <http://www.ncbi.nlm.nih.gov/pubmed/18794305>.

584. Zhang H, Zhu J, Ke F, et al. Radiological imaging for assessing the respectability of hilar cholangiocarcinoma: a systematic review and meta-analysis. *Biomed Res Int* 2015;2015:497942. Available at: <https://www.ncbi.nlm.nih.gov/pubmed/26448940>.

585. Zaydfudim VM, Wang AY, de Lange EE, et al. IgG4-associated cholangitis can mimic hilar cholangiocarcinoma. *Gut Liver* 2015;9:556-560. Available at: <https://www.ncbi.nlm.nih.gov/pubmed/26033685>.

586. Oh HC, Kim MH, Lee KT, et al. Clinical clues to suspicion of IgG4-associated sclerosing cholangitis disguised as primary sclerosing cholangitis or hilar cholangiocarcinoma. *J Gastroenterol Hepatol* 2010;25:1831-1837. Available at: <https://www.ncbi.nlm.nih.gov/pubmed/21091993>.

587. Oseini AM, Chaiteerakij R, Shire AM, et al. Utility of serum immunoglobulin G4 in distinguishing immunoglobulin G4-associated cholangitis from cholangiocarcinoma. *Hepatology* 2011;54:940-948. Available at: <https://www.ncbi.nlm.nih.gov/pubmed/21674559>.

588. Xu WL, Ling YC, Wang ZK, Deng F. Diagnostic performance of serum IgG4 level for IgG4-related disease: a meta-analysis. *Sci Rep* 2016;6:32035. Available at: <https://www.ncbi.nlm.nih.gov/pubmed/27558881>.

589. Halefoglu AM. Magnetic resonance cholangiopancreatography: a useful tool in the evaluation of pancreatic and biliary disorders. *World J Gastroenterol* 2007;13:2529-2534. Available at: <http://www.ncbi.nlm.nih.gov/pubmed/17551999>.



590. Hekimoglu K, Ustundag Y, Dusak A, et al. MRCP vs. ERCP in the evaluation of biliary pathologies: review of current literature. *J Dig Dis* 2008;9:162-169. Available at:

<http://www.ncbi.nlm.nih.gov/pubmed/18956595>.

591. Vogl TJ, Schwarz WO, Heller M, et al. Staging of Klatskin tumours (hilar cholangiocarcinomas): comparison of MR cholangiography, MR imaging, and endoscopic retrograde cholangiography. *Eur Radiol* 2006;16:2317-2325. Available at:

<http://www.ncbi.nlm.nih.gov/pubmed/16622690>.

592. Hyodo T, Kumano S, Kushihata F, et al. CT and MR cholangiography: advantages and pitfalls in perioperative evaluation of biliary tree. *Br J Radiol* 2012;85:887-896. Available at:

<http://www.ncbi.nlm.nih.gov/pubmed/22422383>.

593. Kim JY, Kim M-H, Lee TY, et al. Clinical role of 18F-FDG PET-CT in suspected and potentially operable cholangiocarcinoma: a prospective study compared with conventional imaging. *Am J Gastroenterol* 2008;103:1145-1151. Available at:

<http://www.ncbi.nlm.nih.gov/pubmed/18177454>.

594. Ruys AT, Bennink RJ, van Westreenen HL, et al. FDG-positron emission tomography/computed tomography and standardized uptake value in the primary diagnosis and staging of hilar cholangiocarcinoma. *HPB (Oxford)* 2011;13:256-262. Available at:

<http://www.ncbi.nlm.nih.gov/pubmed/21418131>.

595. Nakagohri T, Asano T, Kinoshita H, et al. Aggressive surgical resection for hilar-invasive and peripheral intrahepatic cholangiocarcinoma. *World J Surg* 2003;27:289-293. Available at:

<http://www.ncbi.nlm.nih.gov/pubmed/12607053>.

596. Konstadoulakis MM, Roayaie S, Gomatos IP, et al. Fifteen-year, single-center experience with the surgical management of intrahepatic cholangiocarcinoma: operative results and long-term outcome. *Surgery* 2008;143:366-374. Available at:

<http://www.ncbi.nlm.nih.gov/pubmed/18291258>.

597. Paik KY, Jung JC, Heo JS, et al. What prognostic factors are important for resected intrahepatic cholangiocarcinoma? *J Gastroenterol Hepatol* 2008;23:766-770. Available at:

<http://www.ncbi.nlm.nih.gov/pubmed/17868336>.

598. Lang H, Sotiropoulos GC, Sgourakis G, et al. Operations for intrahepatic cholangiocarcinoma: single-institution experience of 158 patients. *J Am Coll Surg* 2009;208:218-228. Available at:

<http://www.ncbi.nlm.nih.gov/pubmed/19228533>.

599. Murakami Y, Uemura K, Sudo T, et al. Prognostic factors after surgical resection for intrahepatic, hilar, and distal cholangiocarcinoma. *Ann Surg Oncol* 2011;18:651-658. Available at:

<http://www.ncbi.nlm.nih.gov/pubmed/20945107>.

600. Ribero D, Pinna AD, Guglielmi A, et al. Surgical approach for long-term survival of patients with intrahepatic cholangiocarcinoma: a multi-institutional analysis of 434 patients. *Arch Surg* 2012;147:1107-1113. Available at:

<http://www.ncbi.nlm.nih.gov/pubmed/22910846>.

601. Tamandl D, Herberger B, Gruenberger B, et al. Influence of hepatic resection margin on recurrence and survival in intrahepatic cholangiocarcinoma. *Ann Surg Oncol* 2008;15:2787-2794. Available at:

<http://www.ncbi.nlm.nih.gov/pubmed/18685896>.

602. Farges O, Fuks D, Boleslawski E, et al. Influence of surgical margins on outcome in patients with intrahepatic cholangiocarcinoma: a multicenter study by the AFC-IHCC-2009 study group. *Ann Surg* 2011;254:824-829; discussion 830. Available at:

<http://www.ncbi.nlm.nih.gov/pubmed/22042474>.

603. Spolverato G, Kim Y, Ejaz A, et al. Conditional probability of long-term survival after liver resection for intrahepatic cholangiocarcinoma: a multi-institutional analysis of 535 patients. *JAMA Surg* 2015;150:538-545. Available at:

<https://www.ncbi.nlm.nih.gov/pubmed/25831462>.

604. Carpizo DR, D'Angelica M. Management and extent of resection for intrahepatic cholangiocarcinoma. *Surg Oncol Clin N Am* 2009;18:289-305, viii-ix. Available at:

<http://www.ncbi.nlm.nih.gov/pubmed/19306813>.



605. Goere D, Wagholikar GD, Pessaux P, et al. Utility of staging laparoscopy in subsets of biliary cancers : laparoscopy is a powerful diagnostic tool in patients with intrahepatic and gallbladder carcinoma. Surg Endosc 2006;20:721-725. Available at: <http://www.ncbi.nlm.nih.gov/pubmed/16508808>.

606. Joseph S, Connor S, Garden OJ. Staging laparoscopy for cholangiocarcinoma. HPB (Oxford) 2008;10:116-119. Available at: <http://www.ncbi.nlm.nih.gov/pubmed/18773068>.

607. Weber SM, Ribero D, O'Reilly EM, et al. Intrahepatic cholangiocarcinoma: expert consensus statement. HPB (Oxford) 2015;17:669-680. Available at: <https://www.ncbi.nlm.nih.gov/pubmed/26172134>.

608. Shimada M, Yamashita Y, Aishima S, et al. Value of lymph node dissection during resection of intrahepatic cholangiocarcinoma. Br J Surg 2001;88:1463-1466. Available at: <http://www.ncbi.nlm.nih.gov/pubmed/11683741>.

609. Choi S-B, Kim K-S, Choi J-Y, et al. The prognosis and survival outcome of intrahepatic cholangiocarcinoma following surgical resection: association of lymph node metastasis and lymph node dissection with survival. Ann Surg Oncol 2009;16:3048-3056. Available at: <http://www.ncbi.nlm.nih.gov/pubmed/19626372>.

610. Clark CJ, Wood-Wentz CM, Reid-Lombardo KM, et al. Lymphadenectomy in the staging and treatment of intrahepatic cholangiocarcinoma: a population-based study using the National Cancer Institute SEER database. HPB (Oxford) 2011;13:612-620. Available at: <http://www.ncbi.nlm.nih.gov/pubmed/21843261>.

611. Morine Y, Shimada M, Utsunomiya T, et al. Clinical impact of lymph node dissection in surgery for peripheral-type intrahepatic cholangiocarcinoma. Surg Today 2012;42:147-151. Available at: <https://www.ncbi.nlm.nih.gov/pubmed/22124809>.

612. Fisher SB, Patel SH, Kooby DA, et al. Lymphovascular and perineural invasion as selection criteria for adjuvant therapy in intrahepatic

cholangiocarcinoma: a multi-institution analysis. HPB (Oxford) 2012;14:514-522. Available at: <http://www.ncbi.nlm.nih.gov/pubmed/22762399>.

613. Hyder O, Hatzaras I, Sotiropoulos GC, et al. Recurrence after operative management of intrahepatic cholangiocarcinoma. Surgery 2013;153:811-818. Available at: <http://www.ncbi.nlm.nih.gov/pubmed/23499016>.

614. Ribero D, Rosso S, Pinna AD, et al. Postoperative nomogram for predicting survival after resection for intrahepatic cholangiocarcinoma [abstract]. J Clin Oncol 2013;31:Abstract 4129. Available at: [http://meeting.ascopubs.org/cgi/content/abstract/31/15\\_suppl/4129](http://meeting.ascopubs.org/cgi/content/abstract/31/15_suppl/4129).

615. Carrafiello G, Lagana D, Cotta E, et al. Radiofrequency ablation of intrahepatic cholangiocarcinoma: preliminary experience. Cardiovasc Intervent Radiol 2010;33:835-839. Available at: <http://www.ncbi.nlm.nih.gov/pubmed/20411389>.

616. Kim JH, Won HJ, Shin YM, et al. Radiofrequency ablation for the treatment of primary intrahepatic cholangiocarcinoma. AJR Am J Roentgenol 2011;196:W205-209. Available at: <http://www.ncbi.nlm.nih.gov/pubmed/21257864>.

617. Kiefer MV, Albert M, McNally M, et al. Chemoembolization of intrahepatic cholangiocarcinoma with cisplatin, doxorubicin, mitomycin C, ethiodol, and polyvinyl alcohol: a 2-center study. Cancer 2011;117:1498-1505. Available at: <http://www.ncbi.nlm.nih.gov/pubmed/21425151>.

618. Kuhlmann JB, Euringer W, Spangenberg HC, et al. Treatment of unresectable cholangiocarcinoma: conventional transarterial chemoembolization compared with drug eluting bead-transarterial chemoembolization and systemic chemotherapy. Eur J Gastroenterol Hepatol 2012;24:437-443. Available at: <http://www.ncbi.nlm.nih.gov/pubmed/22261548>.

619. Hyder O, Marsh JW, Salem R, et al. Intra-arterial therapy for advanced intrahepatic cholangiocarcinoma: a multi-institutional analysis.





Ann Surg Oncol 2013;20:3779-3786. Available at:  
<http://www.ncbi.nlm.nih.gov/pubmed/23846786>.

620. Poggi G, Quaretti P, Minoia C, et al. Transhepatic arterial chemoembolization with oxaliplatin-eluting microspheres (OEM-TACE) for unresectable hepatic tumors. Anticancer Res 2008;28:3835-3842. Available at: <http://www.ncbi.nlm.nih.gov/pubmed/19192637>.

621. Schiffman SC, Metzger T, Dubel G, et al. Precision hepatic arterial irinotecan therapy in the treatment of unresectable intrahepatic cholangiocellular carcinoma: optimal tolerance and prolonged overall survival. Ann Surg Oncol 2011;18:431-438. Available at: <http://www.ncbi.nlm.nih.gov/pubmed/20862554>.

622. Ibrahim SM, Mulcahy MF, Lewandowski RJ, et al. Treatment of unresectable cholangiocarcinoma using yttrium-90 microspheres: results from a pilot study. Cancer 2008;113:2119-2128. Available at: <http://www.ncbi.nlm.nih.gov/pubmed/18759346>.

623. Saxena A, Bester L, Chua TC, et al. Yttrium-90 radiotherapy for unresectable intrahepatic cholangiocarcinoma: a preliminary assessment of this novel treatment option. Ann Surg Oncol 2010;17:484-491. Available at: <http://www.ncbi.nlm.nih.gov/pubmed/19876691>.

624. Wijlemans JW, Van Erpecum KJ, Lam MG, et al. Trans-arterial (90)yttrium radioembolization for patients with unresectable tumors originating from the biliary tree. Ann Hepatol 2011;10:349-354. Available at: <http://www.ncbi.nlm.nih.gov/pubmed/21677339>.

625. Hoffmann R-T, Paprottka PM, Schon A, et al. Transarterial hepatic yttrium-90 radioembolization in patients with unresectable intrahepatic cholangiocarcinoma: factors associated with prolonged survival. Cardiovasc Intervent Radiol 2012;35:105-116. Available at: <http://www.ncbi.nlm.nih.gov/pubmed/21431970>.

626. Rafi S, Piduru SM, El-Rayes B, et al. Yttrium-90 radioembolization for unresectable standard-chemorefractory intrahepatic cholangiocarcinoma: survival, efficacy, and safety study. Cardiovasc Intervent Radiol

2013;36:440-448. Available at:  
<http://www.ncbi.nlm.nih.gov/pubmed/22956045>.

627. Mouli S, Memon K, Baker T, et al. Yttrium-90 radioembolization for intrahepatic cholangiocarcinoma: safety, response, and survival analysis. J Vasc Interv Radiol 2013;24:1227-1234. Available at: <http://www.ncbi.nlm.nih.gov/pubmed/23602420>.

628. Al-Adra DP, Gill RS, Axford SJ, et al. Treatment of unresectable intrahepatic cholangiocarcinoma with yttrium-90 radioembolization: a systematic review and pooled analysis. Eur J Surg Oncol 2015;41:120-127. Available at: <https://www.ncbi.nlm.nih.gov/pubmed/25449754>.

629. Edeline J, Toucheffeu Y, Guiu B, et al. Radioembolization plus chemotherapy for first-line treatment of locally advanced intrahepatic cholangiocarcinoma: A phase 2 clinical trial. JAMA Oncol 2019. Available at: <https://www.ncbi.nlm.nih.gov/pubmed/31670746>.

630. Shinohara ET, Mitra N, Guo M, Metz JM. Radiation therapy is associated with improved survival in the adjuvant and definitive treatment of intrahepatic cholangiocarcinoma. Int J Radiat Oncol Biol Phys 2008;72:1495-1501. Available at: <http://www.ncbi.nlm.nih.gov/pubmed/18472359>.

631. Tao R, Krishnan S, Bhosale PR, et al. Ablative radiotherapy doses lead to a substantial prolongation of survival in patients with inoperable intrahepatic cholangiocarcinoma: a retrospective dose response analysis. J Clin Oncol 2016;34:219-226. Available at: <https://www.ncbi.nlm.nih.gov/pubmed/26503201>.

632. Mambrini A, Guglielmi A, Pacetti P, et al. Capecitabine plus hepatic intra-arterial epirubicin and cisplatin in unresectable biliary cancer: a phase II study. Anticancer Res 2007;27:3009-3013. Available at: <http://www.ncbi.nlm.nih.gov/pubmed/17695488>.

633. Inaba Y, Arai Y, Yamaura H, et al. Phase I/II study of hepatic arterial infusion chemotherapy with gemcitabine in patients with unresectable intrahepatic cholangiocarcinoma (JIVROSG-0301). Am J Clin Oncol





# NCCN Guidelines Version 5.2021

## Hepatobiliary Cancers

2011;34:58-62. Available at:

<http://www.ncbi.nlm.nih.gov/pubmed/20177362>.

634. Kemeny NE, Schwartz L, Gonen M, et al. Treating primary liver cancer with hepatic arterial infusion of floxuridine and dexamethasone: does the addition of systemic bevacizumab improve results? *Oncology* 2011;80:153-159. Available at:

<http://www.ncbi.nlm.nih.gov/pubmed/21677464>.

635. Jarnagin WR, Schwartz LH, Gultekin DH, et al. Regional chemotherapy for unresectable primary liver cancer: results of a phase II clinical trial and assessment of DCE-MRI as a biomarker of survival. *Ann Oncol* 2009;20:1589-1595. Available at:

<https://www.ncbi.nlm.nih.gov/pubmed/19491285>.

636. Konstantinidis IT, Do RK, Gultekin DH, et al. Regional chemotherapy for unresectable intrahepatic cholangiocarcinoma: a potential role for dynamic magnetic resonance imaging as an imaging biomarker and a survival update from two prospective clinical trials. *Ann Surg Oncol* 2014;21:2675-2683. Available at:

<https://www.ncbi.nlm.nih.gov/pubmed/24664624>.

637. Boehm LM, Jayakrishnan TT, Miura JT, et al. Comparative effectiveness of hepatic artery based therapies for unresectable intrahepatic cholangiocarcinoma. *J Surg Oncol* 2015;111:213-220. Available at: <https://www.ncbi.nlm.nih.gov/pubmed/25176325>.

638. Konstantinidis IT, Groot Koerkamp B, Do RK, et al. Unresectable intrahepatic cholangiocarcinoma: Systemic plus hepatic arterial infusion chemotherapy is associated with longer survival in comparison with systemic chemotherapy alone. *Cancer* 2016;122:758-765. Available at: <https://www.ncbi.nlm.nih.gov/pubmed/26695839>.

639. Akamatsu N, Sugawara Y, Hashimoto D. Surgical strategy for bile duct cancer: Advances and current limitations. *World J Clin Oncol* 2011;2:94-107. Available at:

<http://www.ncbi.nlm.nih.gov/pubmed/21603318>.

640. Nagino M, Ebata T, Yokoyama Y, et al. Evolution of surgical treatment for perihilar cholangiocarcinoma: a single-center 34-year review of 574 consecutive resections. *Ann Surg* 2013;258:129-140. Available at: <https://www.ncbi.nlm.nih.gov/pubmed/23059502>.

641. Qiao Q-L, Zhang T-P, Guo J-C, et al. Prognostic factors after pancreatoduodenectomy for distal bile duct cancer. *Am Surg* 2011;77:1445-1448. Available at:

<http://www.ncbi.nlm.nih.gov/pubmed/22196654>.

642. Groot Koerkamp B, Wiggers JK, Gonen M, et al. Survival after resection of perihilar cholangiocarcinoma-development and external validation of a prognostic nomogram. *Ann Oncol* 2015;26:1930-1935. Available at: <https://www.ncbi.nlm.nih.gov/pubmed/26133967>.

643. Schwarz RE, Smith DD. Lymph node dissection impact on staging and survival of extrahepatic cholangiocarcinomas, based on U.S. population data. *J Gastrointest Surg* 2007;11:158-165. Available at: <http://www.ncbi.nlm.nih.gov/pubmed/17390167>.

644. Ito K, Ito H, Allen PJ, et al. Adequate lymph node assessment for extrahepatic bile duct adenocarcinoma. *Ann Surg* 2010;251:675-681. Available at: <http://www.ncbi.nlm.nih.gov/pubmed/20224368>.

645. Ota T, Araida T, Yamamoto M, Takasaki K. Operative outcome and problems of right hepatic lobectomy with pancreatoduodenectomy for advanced carcinoma of the biliary tract. *J Hepatobiliary Pancreat Surg* 2007;14:155-158. Available at: <https://www.ncbi.nlm.nih.gov/pubmed/17384906>.

646. Miwa S, Kobayashi A, Akahane Y, et al. Is major hepatectomy with pancreatoduodenectomy justified for advanced biliary malignancy? *J Hepatobiliary Pancreat Surg* 2007;14:136-141. Available at: <https://www.ncbi.nlm.nih.gov/pubmed/17384903>.

647. Ribero D, Zimmitti G, Aloia TA, et al. Preoperative cholangitis and future liver remnant volume determine the risk of liver failure in patients undergoing resection for hilar cholangiocarcinoma. *J Am Coll Surg*



# NCCN Guidelines Version 5.2021

## Hepatobiliary Cancers

2016;223:87-97. Available at:

<https://www.ncbi.nlm.nih.gov/pubmed/27049784>.

648. Nishio H, Nagino M, Nimura Y. Surgical management of hilar cholangiocarcinoma: the Nagoya experience. *HPB (Oxford)* 2005;7:259-262. Available at: <http://www.ncbi.nlm.nih.gov/pubmed/18333203>.

649. Ito F, Agni R, Rettammel RJ, et al. Resection of hilar cholangiocarcinoma: concomitant liver resection decreases hepatic recurrence. *Ann Surg* 2008;248:273-279. Available at: <http://www.ncbi.nlm.nih.gov/pubmed/18650638>.

650. van Gulik TM, Kloek JJ, Ruys AT, et al. Multidisciplinary management of hilar cholangiocarcinoma (Klatskin tumor): extended resection is associated with improved survival. *Eur J Surg Oncol* 2011;37:65-71. Available at: <http://www.ncbi.nlm.nih.gov/pubmed/21115233>.

651. Cheng QB, Yi B, Wang JH, et al. Resection with total caudate lobectomy confers survival benefit in hilar cholangiocarcinoma of Bismuth type III and IV. *Eur J Surg Oncol* 2012;38:1197-1203. Available at: <http://www.ncbi.nlm.nih.gov/pubmed/22992326>.

652. Cho MS, Kim SH, Park SW, et al. Surgical outcomes and predicting factors of curative resection in patients with hilar cholangiocarcinoma: 10-year single-institution experience. *J Gastrointest Surg* 2012;16:1672-1679. Available at: <http://www.ncbi.nlm.nih.gov/pubmed/22798185>.

653. de Jong MC, Marques H, Clary BM, et al. The impact of portal vein resection on outcomes for hilar cholangiocarcinoma: a multi-institutional analysis of 305 cases. *Cancer* 2012;118:4737-4747. Available at: <http://www.ncbi.nlm.nih.gov/pubmed/22415526>.

654. Wu XS, Dong P, Gu J, et al. Combined portal vein resection for hilar cholangiocarcinoma: a meta-analysis of comparative studies. *J Gastrointest Surg* 2013;17:1107-1115. Available at: <http://www.ncbi.nlm.nih.gov/pubmed/23592188>.

655. Cho A, Yamamoto H, Kainuma O, et al. Laparoscopy in the management of hilar cholangiocarcinoma. *World J Gastroenterol*

2014;20:15153-15157. Available at:

<http://www.ncbi.nlm.nih.gov/pubmed/25386064>.

656. Ruys AT, Busch OR, Gouma DJ, van Gulik TM. Staging laparoscopy for hilar cholangiocarcinoma: is it still worthwhile? *Indian J Surg Oncol* 2012;3:147-153. Available at: <http://www.ncbi.nlm.nih.gov/pubmed/23728233>.

657. Nimura Y. Preoperative biliary drainage before resection for cholangiocarcinoma (Pro). *HPB (Oxford)* 2008;10:130-133. Available at: <http://www.ncbi.nlm.nih.gov/pubmed/18773090>.

658. Kennedy TJ, Yopp A, Qin Y, et al. Role of preoperative biliary drainage of liver remnant prior to extended liver resection for hilar cholangiocarcinoma. *HPB (Oxford)* 2009;11:445-451. Available at: <http://www.ncbi.nlm.nih.gov/pubmed/19768150>.

659. Liu F, Li Y, Wei Y, Li B. Preoperative biliary drainage before resection for hilar cholangiocarcinoma: whether or not? A systematic review. *Dig Dis Sci* 2011;56:663-672. Available at: <http://www.ncbi.nlm.nih.gov/pubmed/20635143>.

660. Farges O, Regimbeau JM, Fuks D, et al. Multicentre European study of preoperative biliary drainage for hilar cholangiocarcinoma. *Br J Surg* 2013;100:274-283. Available at: <http://www.ncbi.nlm.nih.gov/pubmed/23124720>.

661. Abulkhir A, Limongelli P, Healey AJ, et al. Preoperative portal vein embolization for major liver resection: a meta-analysis. *Ann Surg* 2008;247:49-57. Available at: <http://www.ncbi.nlm.nih.gov/pubmed/18156923>.

662. Shindoh J, Vauthey J-N, Zimmitti G, et al. Analysis of the efficacy of portal vein embolization for patients with extensive liver malignancy and very low future liver remnant volume, including a comparison with the associating liver partition with portal vein ligation for staged hepatectomy approach. *J Am Coll Surg* 2013. Available at: <http://www.ncbi.nlm.nih.gov/pubmed/23632095>.



663. Davids PH, Groen AK, Rauws EA, et al. Randomised trial of self-expanding metal stents versus polyethylene stents for distal malignant biliary obstruction. *Lancet* 1992;340:1488-1492. Available at: <http://www.ncbi.nlm.nih.gov/pubmed/1281903>.

664. Prat F, Chapat O, Ducot B, et al. A randomized trial of endoscopic drainage methods for inoperable malignant strictures of the common bile duct. *Gastrointest Endosc* 1998;47:1-7. Available at: <http://www.ncbi.nlm.nih.gov/pubmed/9468416>.

665. Abraham NS, Barkun JS, Barkun AN. Palliation of malignant biliary obstruction: a prospective trial examining impact on quality of life. *Gastrointest Endosc* 2002;56:835-841. Available at: <http://www.ncbi.nlm.nih.gov/pubmed/12447294>.

666. Paik WH, Park YS, Hwang JH, et al. Palliative treatment with self-expandable metallic stents in patients with advanced type III or IV hilar cholangiocarcinoma: a percutaneous versus endoscopic approach. *Gastrointest Endosc* 2009;69:55-62. Available at: <http://www.ncbi.nlm.nih.gov/pubmed/18657806>.

667. Robles R, Figueras J, Turrion VS, et al. Spanish experience in liver transplantation for hilar and peripheral cholangiocarcinoma. *Ann Surg* 2004;239:265-271. Available at: <http://www.ncbi.nlm.nih.gov/pubmed/14745336>.

668. Becker NS, Rodriguez JA, Barshes NR, et al. Outcomes analysis for 280 patients with cholangiocarcinoma treated with liver transplantation over an 18-year period. *J Gastrointest Surg* 2008;12:117-122. Available at: <http://www.ncbi.nlm.nih.gov/pubmed/17963015>.

669. Kaiser GM, Sotiropoulos GC, Jauch KW, et al. Liver transplantation for hilar cholangiocarcinoma: a German survey. *Transplant Proc* 2008;40:3191-3193. Available at: <http://www.ncbi.nlm.nih.gov/pubmed/19010230>.

670. Friman S, Foss A, Isoniemi H, et al. Liver transplantation for cholangiocarcinoma: selection is essential for acceptable results. *Scand J*

*Gastroenterol* 2011;46:370-375. Available at: <http://www.ncbi.nlm.nih.gov/pubmed/21073376>.

671. Darwish Murad S, Kim WR, Harnois DM, et al. Efficacy of neoadjuvant chemoradiation, followed by liver transplantation, for perihilar cholangiocarcinoma at 12 US centers. *Gastroenterology* 2012;143:88-98. Available at: <http://www.ncbi.nlm.nih.gov/pubmed/22504095>.

672. Panjala C, Nguyen JH, Al-Hajjaj AN, et al. Impact of neoadjuvant chemoradiation on the tumor burden before liver transplantation for unresectable cholangiocarcinoma. *Liver Transpl* 2012;18:594-601. Available at: <http://www.ncbi.nlm.nih.gov/pubmed/22140024>.

673. Duignan S, Maguire D, Ravichand CS, et al. Neoadjuvant chemoradiotherapy followed by liver transplantation for unresectable cholangiocarcinoma: a single-centre national experience. *HPB (Oxford)* 2013. Available at: <http://www.ncbi.nlm.nih.gov/pubmed/23600750>.

674. Rea DJ, Heimbach JK, Rosen CB, et al. Liver transplantation with neoadjuvant chemoradiation is more effective than resection for hilar cholangiocarcinoma. *Ann Surg* 2005;242:451-458. Available at: <http://www.ncbi.nlm.nih.gov/pubmed/16135931>.

675. Hong JC, Jones CM, Duffy JP, et al. Comparative analysis of resection and liver transplantation for intrahepatic and hilar cholangiocarcinoma: a 24-year experience in a single center. *Arch Surg* 2011;146:683-689. Available at: <http://www.ncbi.nlm.nih.gov/pubmed/21690444>.

676. Ortnor MEJ, Caca K, Berr F, et al. Successful photodynamic therapy for nonresectable cholangiocarcinoma: a randomized prospective study. *Gastroenterology* 2003;125:1355-1363. Available at: <http://www.ncbi.nlm.nih.gov/pubmed/14598251>.

677. Zoepf T, Jakobs R, Arnold JC, et al. Palliation of nonresectable bile duct cancer: improved survival after photodynamic therapy. *Am J Gastroenterol* 2005;100:2426-2430. Available at: <http://www.ncbi.nlm.nih.gov/pubmed/16279895>.



678. Cereda S, Belli C, Reni M. Adjuvant treatment in biliary tract cancer: to treat or not to treat? *World J Gastroenterol* 2012;18:2591-2596.

Available at: <http://www.ncbi.nlm.nih.gov/pubmed/22690066>.

679. Mallick S, Benson R, Haresh KP, et al. Adjuvant radiotherapy in the treatment of gall bladder carcinoma: What is the current evidence. *J Egypt Natl Canc Inst* 2016;28:1-6. Available at:

<https://www.ncbi.nlm.nih.gov/pubmed/26265290>.

680. Primrose JN, Fox RP, Palmer DH, et al. Capecitabine compared with observation in resected biliary tract cancer (BILCAP): a randomised, controlled, multicentre, phase 3 study. *Lancet Oncol* 2019;20:663-673.

Available at: <https://www.ncbi.nlm.nih.gov/pubmed/30922733>.

681. Takada T, Amano H, Yasuda H, et al. Is postoperative adjuvant chemotherapy useful for gallbladder carcinoma? A phase III multicenter prospective randomized controlled trial in patients with resected pancreaticobiliary carcinoma. *Cancer* 2002;95:1685-1695. Available at:

<http://www.ncbi.nlm.nih.gov/pubmed/12365016>.

682. Edeline J, Benabdelghani M, Bertaut A, et al. Gemcitabine and oxaliplatin chemotherapy or surveillance in resected biliary tract cancer (PRODIGE 12-ACCORD 18-UNICANCER GI): a randomized phase III study. *J Clin Oncol* 2019;37:658-667. Available at:

<https://www.ncbi.nlm.nih.gov/pubmed/30707660>.

683. Ebata T, Hirano S, Konishi M, et al. Randomized clinical trial of adjuvant gemcitabine chemotherapy versus observation in resected bile duct cancer. *Br J Surg* 2018;105:192-202. Available at:

<https://www.ncbi.nlm.nih.gov/pubmed/29405274>.

684. Glazer ES, Liu P, Abdalla EK, et al. Neither neoadjuvant nor adjuvant therapy increases survival after biliary tract cancer resection with wide negative margins. *J Gastrointest Surg* 2012;16:1666-1671. Available at:

<http://www.ncbi.nlm.nih.gov/pubmed/22777053>.

685. Tran Cao HS, Zhang Q, Sada YH, et al. The role of surgery and adjuvant therapy in lymph node-positive cancers of the gallbladder and

intrahepatic bile ducts. *Cancer* 2018;124:74-83. Available at:

<https://www.ncbi.nlm.nih.gov/pubmed/28841223>.

686. Horgan AM, Amir E, Walter T, Knox JJ. Adjuvant therapy in the treatment of biliary tract cancer: a systematic review and meta-analysis. *Journal of Clinical Oncology* 2012;30:1934-1940. Available at:

<http://www.ncbi.nlm.nih.gov/pubmed/22529261>.

687. Rangarajan K, Simmons G, Manas D, et al. Systemic adjuvant chemotherapy for cholangiocarcinoma surgery: A systematic review and meta-analysis. *Eur J Surg Oncol* 2020;46:684-693. Available at:

<https://www.ncbi.nlm.nih.gov/pubmed/31761507>.

688. Ma N, Cheng H, Qin B, et al. Adjuvant therapy in the treatment of gallbladder cancer: a meta-analysis. *BMC Cancer* 2015;15:615. Available at: <https://www.ncbi.nlm.nih.gov/pubmed/26337466>.

689. Gold DG, Miller RC, Haddock MG, et al. Adjuvant therapy for gallbladder carcinoma: the Mayo Clinic Experience. *Int J Radiat Oncol Biol Phys* 2009;75:150-155. Available at:

<http://www.ncbi.nlm.nih.gov/pubmed/19297105>.

690. Cho SY, Kim SH, Park S-J, et al. Adjuvant chemoradiation therapy in gallbladder cancer. *J Surg Oncol* 2010;102:87-93. Available at:

<http://www.ncbi.nlm.nih.gov/pubmed/20578085>.

691. Kim K, Chie EK, Jang JY, et al. Postoperative chemoradiotherapy for gallbladder cancer. *Strahlenther Onkol* 2012;188:388-392. Available at:

<http://www.ncbi.nlm.nih.gov/pubmed/22402869>.

692. Kim Y, Amini N, Wilson A, et al. Impact of chemotherapy and external-beam radiation therapy on outcomes among patients with resected gallbladder cancer: a multi-institutional analysis. *Ann Surg Oncol* 2016;23:2998-3008. Available at:

<https://www.ncbi.nlm.nih.gov/pubmed/27169772>.

693. Hughes MA, Frassica DA, Yeo CJ, et al. Adjuvant concurrent chemoradiation for adenocarcinoma of the distal common bile duct. *Int J*





Radiat Oncol Biol Phys 2007;68:178-182. Available at:  
<http://www.ncbi.nlm.nih.gov/pubmed/17276614>.

694. Nelson JW, Ghafoori AP, Willett CG, et al. Concurrent chemoradiotherapy in resected extrahepatic cholangiocarcinoma. Int J Radiat Oncol Biol Phys 2009;73:148-153. Available at:  
<http://www.ncbi.nlm.nih.gov/pubmed/18805651>.

695. Lim KH, Oh DY, Chie EK, et al. Adjuvant concurrent chemoradiation therapy (CCRT) alone versus CCRT followed by adjuvant chemotherapy: which is better in patients with radically resected extrahepatic biliary tract cancer?: a non-randomized, single center study. BMC Cancer 2009;9:345. Available at: <http://www.ncbi.nlm.nih.gov/pubmed/19781103>.

696. Kim TH, Han SS, Park SJ, et al. Role of adjuvant chemoradiotherapy for resected extrahepatic biliary tract cancer. Int J Radiat Oncol Biol Phys 2011;81:e853-859. Available at:  
<http://www.ncbi.nlm.nih.gov/pubmed/21497455>.

697. Borghero Y, Crane CH, Szklaruk J, et al. Extrahepatic bile duct adenocarcinoma: patients at high-risk for local recurrence treated with surgery and adjuvant chemoradiation have an equivalent overall survival to patients with standard-risk treated with surgery alone. Ann Surg Oncol 2008;15:3147-3156. Available at:  
<http://www.ncbi.nlm.nih.gov/pubmed/18754070>.

698. Park J-h, Choi EK, Ahn SD, et al. Postoperative chemoradiotherapy for extrahepatic bile duct cancer. Int J Radiat Oncol Biol Phys 2011;79:696-704. Available at:  
<http://www.ncbi.nlm.nih.gov/pubmed/20510541>.

699. Das P, Wolff RA, Abbruzzese JL, et al. Concurrent capecitabine and upper abdominal radiation therapy is well tolerated. Radiat Oncol 2006;1:41-41. Available at:  
<http://www.ncbi.nlm.nih.gov/pubmed/17062148>.

700. Lin LL, Picus J, Drebin JA, et al. A phase II study of alternating cycles of split course radiation therapy and gemcitabine chemotherapy for inoperable pancreatic or biliary tract carcinoma. Am J Clin Oncol

2005;28:234-241. Available at:  
<http://www.ncbi.nlm.nih.gov/pubmed/15923794>.

701. Ben-Josef E, Guthrie KA, El-Khoueiry AB, et al. SWOG S0809: a phase II intergroup trial of adjuvant capecitabine and gemcitabine followed by radiotherapy and concurrent capecitabine in extrahepatic cholangiocarcinoma and gallbladder carcinoma. J Clin Oncol 2015;33:2617-2622. Available at:  
<http://www.ncbi.nlm.nih.gov/pubmed/25964250>.

702. Wang SJ, Lemieux A, Kalpathy-Cramer J, et al. Nomogram for predicting the benefit of adjuvant chemoradiotherapy for resected gallbladder cancer. Journal of Clinical Oncology 2011;29:4627-4632. Available at: <http://www.ncbi.nlm.nih.gov/pubmed/22067404>.

703. Jeong Y, Park JH, Lee YJ, et al. Postoperative radiotherapy for gallbladder cancer. Anticancer Res 2014;34:5621-5629. Available at:  
<https://www.ncbi.nlm.nih.gov/pubmed/25275065>.

704. Park J, Kim MH, Kim KP, et al. Natural history and prognostic factors of advanced cholangiocarcinoma without surgery, chemotherapy, or radiotherapy: a large-scale observational study. Gut Liver 2009;3:298-305. Available at: <http://www.ncbi.nlm.nih.gov/pubmed/20431764>.

705. Glimelius B, Hoffman K, Sjoden PO, et al. Chemotherapy improves survival and quality of life in advanced pancreatic and biliary cancer. Ann Oncol 1996;7:593-600. Available at:  
<http://www.ncbi.nlm.nih.gov/pubmed/8879373>.

706. Sharma A, Dwary AD, Mohanti BK, et al. Best supportive care compared with chemotherapy for unresectable gall bladder cancer: a randomized controlled study. Journal of Clinical Oncology 2010;28:4581-4586. Available at: <http://www.ncbi.nlm.nih.gov/pubmed/20855823>.

707. Hezel AF, Zhu AX. Systemic therapy for biliary tract cancers. Oncologist 2008;13:415-423. Available at:  
<http://www.ncbi.nlm.nih.gov/pubmed/18448556>.



708. Geynisman DM, Catenacci DV. Toward personalized treatment of advanced biliary tract cancers. *Discov Med* 2012;14:41-57. Available at: <http://www.ncbi.nlm.nih.gov/pubmed/22846202>.

709. Eckel F, Schmid RM. Chemotherapy in advanced biliary tract carcinoma: a pooled analysis of clinical trials. *Br J Cancer* 2007;96:896-902. Available at: <http://www.ncbi.nlm.nih.gov/pubmed/17325704>.

710. Yonemoto N, Furuse J, Okusaka T, et al. A multi-center retrospective analysis of survival benefits of chemotherapy for unresectable biliary tract cancer. *Jpn J Clin Oncol* 2007;37:843-851. Available at: <http://www.ncbi.nlm.nih.gov/pubmed/17942578>.

711. Kornek GV, Schuell B, Laengle F, et al. Mitomycin C in combination with capecitabine or biweekly high-dose gemcitabine in patients with advanced biliary tract cancer: a randomised phase II trial. *Ann Oncol* 2004;15:478-483. Available at: <http://www.ncbi.nlm.nih.gov/pubmed/14998852>.

712. Ducreux M, Van Cutsem E, Van Laethem JL, et al. A randomised phase II trial of weekly high-dose 5-fluorouracil with and without folinic acid and cisplatin in patients with advanced biliary tract carcinoma: results of the 40955 EORTC trial. *Eur J Cancer* 2005;41:398-403. Available at: <http://www.ncbi.nlm.nih.gov/pubmed/15691639>.

713. Valle J, Wasan H, Palmer DH, et al. Cisplatin plus gemcitabine versus gemcitabine for biliary tract cancer. *N Engl J Med* 2010;362:1273-1281. Available at: <http://www.ncbi.nlm.nih.gov/pubmed/20375404>.

714. Okusaka T, Nakachi K, Fukutomi A, et al. Gemcitabine alone or in combination with cisplatin in patients with biliary tract cancer: a comparative multicentre study in Japan. *Br J Cancer* 2010;103:469-474. Available at: <http://www.ncbi.nlm.nih.gov/pubmed/20628385>.

715. Grenader T, Nash S, Plotkin Y, et al. Derived neutrophil lymphocyte ratio may predict benefit from cisplatin in the advanced biliary cancer: the ABC-02 and BT-22 studies. *Ann Oncol* 2015;26:1910-1916. Available at: <https://www.ncbi.nlm.nih.gov/pubmed/26037798>.

716. Lamarca A, Palmer DH, Wasan HS, et al. Second-line FOLFOX chemotherapy versus active symptom control for advanced biliary tract cancer (ABC-06): a phase 3, open-label, randomised, controlled trial. *Lancet Oncol* 2021. Available at: <https://www.ncbi.nlm.nih.gov/pubmed/33798493>.

717. Caparica R, Lengele A, Bekolo W, Hendlisz A. FOLFIRI as second-line treatment of metastatic biliary tract cancer patients. *Autops Case Rep* 2019;9:e2019087. Available at: <https://www.ncbi.nlm.nih.gov/pubmed/31528622>.

718. Doval DC, Sekhon JS, Gupta SK, et al. A phase II study of gemcitabine and cisplatin in chemotherapy-naïve, unresectable gall bladder cancer. *Br J Cancer* 2004;90:1516-1520. Available at: <http://www.ncbi.nlm.nih.gov/pubmed/15083178>.

719. Thongprasert S, Napapan S, Charoentum C, Moonprakan S. Phase II study of gemcitabine and cisplatin as first-line chemotherapy in inoperable biliary tract carcinoma. *Ann Oncol* 2005;16:279-281. Available at: <http://www.ncbi.nlm.nih.gov/pubmed/15668284>.

720. Giuliani F, Gebbia V, Maiello E, et al. Gemcitabine and cisplatin for inoperable and/or metastatic biliary tree carcinomas: a multicenter phase II study of the Gruppo Oncologico dell'Italia Meridionale (GOIM). *Ann Oncol* 2006;17 Suppl 7:73-77. Available at: <http://www.ncbi.nlm.nih.gov/pubmed/16760299>.

721. Lee J, Kim T-Y, Lee MA, et al. Phase II trial of gemcitabine combined with cisplatin in patients with inoperable biliary tract carcinomas. *Cancer Chemother Pharmacol* 2008;61:47-52. Available at: <http://www.ncbi.nlm.nih.gov/pubmed/17364190>.

722. Meyerhardt JA, Zhu AX, Stuart K, et al. Phase-II study of gemcitabine and cisplatin in patients with metastatic biliary and gallbladder cancer. *Dig Dis Sci* 2008;53:564-570. Available at: <http://www.ncbi.nlm.nih.gov/pubmed/17597402>.

723. Andre T, Reyes-Vidal JM, Fartoux L, et al. Gemcitabine and oxaliplatin in advanced biliary tract carcinoma: a phase II study. *Br J*



Cancer 2008;99:862-867. Available at:  
<http://www.ncbi.nlm.nih.gov/pubmed/19238628>.

724. Harder J, Riecken B, Kummer O, et al. Outpatient chemotherapy with gemcitabine and oxaliplatin in patients with biliary tract cancer. Br J Cancer 2006;95:848-852. Available at:  
<http://www.ncbi.nlm.nih.gov/pubmed/16969352>.

725. Kim HJ, Lee NS, Lee S-C, et al. A phase II study of gemcitabine in combination with oxaliplatin as first-line chemotherapy in patients with inoperable biliary tract cancer. Cancer Chemother Pharmacol 2009;64:371-377. Available at:  
<http://www.ncbi.nlm.nih.gov/pubmed/19142638>.

726. Jang J-S, Lim HY, Hwang IG, et al. Gemcitabine and oxaliplatin in patients with unresectable biliary cancer including gall bladder cancer: a Korean Cancer Study Group phase II trial. Cancer Chemother Pharmacol 2010;65:641-647. Available at:  
<http://www.ncbi.nlm.nih.gov/pubmed/19652971>.

727. Alberts SR, Al-Khatib H, Mahoney MR, et al. Gemcitabine, 5-fluorouracil, and leucovorin in advanced biliary tract and gallbladder carcinoma: a North Central Cancer Treatment Group phase II trial. Cancer 2005;103:111-118. Available at:  
<http://www.ncbi.nlm.nih.gov/pubmed/15558814>.

728. Knox JJ, Hedley D, Oza A, et al. Combining gemcitabine and capecitabine in patients with advanced biliary cancer: a phase II trial. J Clin Oncol 2005;23:2332-2338. Available at:  
<http://www.ncbi.nlm.nih.gov/pubmed/15800324>.

729. Riechelmann RP, Townsley CA, Chin SN, et al. Expanded phase II trial of gemcitabine and capecitabine for advanced biliary cancer. Cancer 2007;110:1307-1312. Available at:  
<http://www.ncbi.nlm.nih.gov/pubmed/17628484>.

730. Koeberle D, Saletti P, Borner M, et al. Patient-reported outcomes of patients with advanced biliary tract cancers receiving gemcitabine plus capecitabine: a multicenter, phase II trial of the Swiss Group for Clinical

Cancer Research. J Clin Oncol 2008;26:3702-3708. Available at:  
<http://www.ncbi.nlm.nih.gov/pubmed/18669455>.

731. Iqbal S, Rankin C, Lenz H-J, et al. A phase II trial of gemcitabine and capecitabine in patients with unresectable or metastatic gallbladder cancer or cholangiocarcinoma: Southwest Oncology Group study S0202. Cancer Chemother Pharmacol 2011;68:1595-1602. Available at:  
<http://www.ncbi.nlm.nih.gov/pubmed/21556747>.

732. Sahai V, Catalano PJ, Zalupski MM, et al. Nab-paclitaxel and gemcitabine as first-line treatment of advanced or metastatic cholangiocarcinoma: a phase 2 clinical trial. JAMA Oncol 2018;4:1707-1712. Available at: <https://www.ncbi.nlm.nih.gov/pubmed/30178032>.

733. Shroff RT, Javle MM, Xiao L, et al. Gemcitabine, cisplatin, and nab-paclitaxel for the treatment of advanced biliary tract cancers: a phase 2 clinical trial. JAMA Oncol 2019;5:824-830. Available at:  
<https://www.ncbi.nlm.nih.gov/pubmed/30998813>.

734. Borbath I, Ceratti A, Verslype C, et al. Combination of gemcitabine and cetuximab in patients with advanced cholangiocarcinoma: a phase II study of the Belgian Group of Digestive Oncology. Ann Oncol 2013;24:2824-2829. Available at:  
<http://www.ncbi.nlm.nih.gov/pubmed/23975665>.

735. Nehls O, Klump B, Arkenau HT, et al. Oxaliplatin, fluorouracil and leucovorin for advanced biliary system adenocarcinomas: a prospective phase II trial. Br J Cancer 2002;87:702-704. Available at:  
<http://www.ncbi.nlm.nih.gov/pubmed/12232749>.

736. Nehls O, Oettle H, Hartmann JT, et al. Capecitabine plus oxaliplatin as first-line treatment in patients with advanced biliary system adenocarcinoma: a prospective multicentre phase II trial. Br J Cancer 2008;98:309-315. Available at:  
<http://www.ncbi.nlm.nih.gov/pubmed/18182984>.

737. Kim TW, Chang HM, Kang HJ, et al. Phase II study of capecitabine plus cisplatin as first-line chemotherapy in advanced biliary cancer. Ann



Oncol 2003;14:1115-1120. Available at:

<http://www.ncbi.nlm.nih.gov/pubmed/12853355>.

738. Kobayashi K, Tsuji A, Morita S, et al. A phase II study of LFP therapy (5-FU (5-fluorouracil) continuous infusion (CVI) and Low-dose consecutive (Cisplatin) CDDP) in advanced biliary tract carcinoma. BMC Cancer 2006;6:121-121. Available at:

<http://www.ncbi.nlm.nih.gov/pubmed/16677397>.

739. Kim ST, Kang JH, Lee J, et al. Capecitabine plus oxaliplatin versus gemcitabine plus oxaliplatin as first-line therapy for advanced biliary tract cancers: a multicenter, open-label, randomized, phase III, noninferiority trial. Ann Oncol 2019;30:788-795. Available at:

<https://www.ncbi.nlm.nih.gov/pubmed/30785198>.

740. Rao S, Cunningham D, Hawkins RE, et al. Phase III study of 5FU, etoposide and leucovorin (FELV) compared to epirubicin, cisplatin and 5FU (ECF) in previously untreated patients with advanced biliary cancer. Br J Cancer 2005;92:1650-1654. Available at:

<http://www.ncbi.nlm.nih.gov/pubmed/15856037>.

741. Yamashita Y-i, Taketomi A, Fukuzawa K, et al. Gemcitabine combined with 5-fluorouracil and cisplatin (GFP) in patients with advanced biliary tree cancers: a pilot study. Anticancer Res 2006;26:771-775. Available at:

<http://www.ncbi.nlm.nih.gov/pubmed/16739352>.

742. Wagner AD, Buechner-Steudel P, Moehler M, et al. Gemcitabine, oxaliplatin and 5-FU in advanced bile duct and gallbladder carcinoma: two parallel, multicentre phase-II trials. Br J Cancer 2009;101:1846-1852. Available at:

<http://www.ncbi.nlm.nih.gov/pubmed/19904267>.

743. Sohal DP, Mykulowycz K, Uehara T, et al. A phase II trial of gemcitabine, irinotecan and panitumumab in advanced cholangiocarcinoma. Ann Oncol 2013;24:3061-3065. Available at:

<http://www.ncbi.nlm.nih.gov/pubmed/24146220>.

744. Moehler M, Maderer A, Schimanski C, et al. Gemcitabine plus sorafenib versus gemcitabine alone in advanced biliary tract cancer: a double-blind placebo-controlled multicentre phase II AIO study with

biomarker and serum programme. Eur J Cancer 2014;50:3125-3135.

Available at: <https://www.ncbi.nlm.nih.gov/pubmed/25446376>.

745. Lamarca A, Hubner RA, David Ryder W, Valle JW. Second-line chemotherapy in advanced biliary cancer: a systematic review. Ann Oncol 2014;25:2328-2338. Available at:

<http://www.ncbi.nlm.nih.gov/pubmed/24769639>.

746. Ghafoori AP, Nelson JW, Willett CG, et al. Radiotherapy in the treatment of patients with unresectable extrahepatic cholangiocarcinoma. Int J Radiat Oncol Biol Phys 2010. Available at:

<http://www.ncbi.nlm.nih.gov/pubmed/20864265>.

747. Macdonald OK, Crane CH. Palliative and postoperative radiotherapy in biliary tract cancer. Surg Oncol Clin N Am 2002;11:941-954. Available at:

<http://www.ncbi.nlm.nih.gov/pubmed/12607581>.

748. Czito BG, Anscher MS, Willett CG. Radiation therapy in the treatment of cholangiocarcinoma. Oncology (Williston Park) 2006;20:873-884. Available at:

<http://www.ncbi.nlm.nih.gov/pubmed/16922259>.

749. Frakulli R, Buwenge M, Macchia G, et al. Stereotactic body radiation therapy in cholangiocarcinoma: a systematic review. Br J Radiol 2019;92:20180688. Available at:

<https://www.ncbi.nlm.nih.gov/pubmed/30673295>.

750. Moureau-Zabotto L, Turrini O, Resbeut M, et al. Impact of radiotherapy in the management of locally advanced extrahepatic cholangiocarcinoma. BMC Cancer 2013;13:568. Available at:

<https://www.ncbi.nlm.nih.gov/pubmed/24299517>.

751. Uno T, Itami J, Aruga M, et al. Primary carcinoma of the gallbladder: role of external beam radiation therapy in patients with locally advanced tumor. Strahlenther Onkol 1996;172:496-500. Available at:

<https://www.ncbi.nlm.nih.gov/pubmed/8830812>.

752. Mondesir J, Willekens C, Touat M, de Botton S. IDH1 and IDH2 mutations as novel therapeutic targets: current perspectives. J Blood Med





2016;7:171-180. Available at:

<https://www.ncbi.nlm.nih.gov/pubmed/27621679>.

753. Borger DR, Tanabe KK, Fan KC, et al. Frequent mutation of isocitrate dehydrogenase (IDH)1 and IDH2 in cholangiocarcinoma identified through broad-based tumor genotyping. *Oncologist* 2012;17:72-79. Available at:

<http://www.ncbi.nlm.nih.gov/pubmed/22180306>.

754. Wang P, Dong Q, Zhang C, et al. Mutations in isocitrate dehydrogenase 1 and 2 occur frequently in intrahepatic cholangiocarcinomas and share hypermethylation targets with glioblastomas. *Oncogene* 2013;32:3091-3100. Available at:

<https://www.ncbi.nlm.nih.gov/pubmed/22824796>.

755. Voss JS, Holtegaard LM, Kerr SE, et al. Molecular profiling of cholangiocarcinoma shows potential for targeted therapy treatment decisions. *Hum Pathol* 2013;44:1216-1222. Available at:

<https://www.ncbi.nlm.nih.gov/pubmed/23391413>.

756. Kipp BR, Voss JS, Kerr SE, et al. Isocitrate dehydrogenase 1 and 2 mutations in cholangiocarcinoma. *Hum Pathol* 2012;43:1552-1558.

Available at: <https://www.ncbi.nlm.nih.gov/pubmed/22503487>.

757. Churi CR, Shroff R, Wang Y, et al. Mutation profiling in cholangiocarcinoma: prognostic and therapeutic implications. *PLoS One* 2014;9:e115383. Available at:

<https://www.ncbi.nlm.nih.gov/pubmed/25536104>.

758. Ruzzenente A, Fassan M, Conci S, et al. Cholangiocarcinoma heterogeneity revealed by multigene mutational profiling: clinical and prognostic relevance in surgically resected patients. *Ann Surg Oncol* 2016;23:1699-1707. Available at:

<https://www.ncbi.nlm.nih.gov/pubmed/26717940>.

759. Zhu AX, Borger DR, Kim Y, et al. Genomic profiling of intrahepatic cholangiocarcinoma: refining prognosis and identifying therapeutic targets. *Ann Surg Oncol* 2014;21:3827-3834. Available at:

<https://www.ncbi.nlm.nih.gov/pubmed/24889489>.

760. Boscoe AN, Rolland C, Kelley RK. Frequency and prognostic significance of isocitrate dehydrogenase 1 mutations in cholangiocarcinoma: a systematic literature review. *J Gastrointest Oncol* 2019;10:751-765. Available at:

<https://www.ncbi.nlm.nih.gov/pubmed/31392056>.

761. Abou-Alfa G, Macarulla T, Javle MM, et al. Ivosidenib in *IDH1*-mutant, chemotherapy-refractory cholangiocarcinoma (ClarIDHy): a multicentre, randomized, double-blind, placebo-controlled, phase 3 study. *Lancet Oncol* 2020. Available at:

<https://www.ncbi.nlm.nih.gov/pubmed/32416072>.

762. Ross JS, Wang K, Gay L, et al. New routes to targeted therapy of intrahepatic cholangiocarcinomas revealed by next-generation sequencing. *Oncologist* 2014;19:235-242. Available at:

<https://www.ncbi.nlm.nih.gov/pubmed/24563076>.

763. Graham RP, Barr Fritcher EG, Pestova E, et al. Fibroblast growth factor receptor 2 translocations in intrahepatic cholangiocarcinoma. *Hum Pathol* 2014;45:1630-1638. Available at:

<https://www.ncbi.nlm.nih.gov/pubmed/24837095>.

764. Arai Y, Totoki Y, Hosoda F, et al. Fibroblast growth factor receptor 2 tyrosine kinase fusions define a unique molecular subtype of cholangiocarcinoma. *Hepatology* 2014;59:1427-1434. Available at:

<https://www.ncbi.nlm.nih.gov/pubmed/24122810>.

765. Abou-Alfa GK, Sahai V, Hollebecque A, et al. Pemigatinib for previously treated, locally advanced or metastatic cholangiocarcinoma: a multicentre, open-label, phase 2 study. *Lancet Oncol* 2020. Available at:

<https://www.ncbi.nlm.nih.gov/pubmed/32203698>.

766. Javle MM, Roychowdhury S, Kelley RK, et al. Final results from a phase II study of infigratinib (BGJ398), an FGFR-selective tyrosine kinase inhibitor, in patients with previously treated advanced cholangiocarcinoma harboring an FGFR2 gene fusion or rearrangement [abstract]. *J Clin Oncol* 2021;39:Abstract 265. Available at:

[https://ascopubs.org/doi/abs/10.1200/JCO.2021.39.3\\_suppl.265](https://ascopubs.org/doi/abs/10.1200/JCO.2021.39.3_suppl.265).



# NCCN Guidelines Version 5.2021

## Hepatobiliary Cancers

767. Demols A, Rocq L, Charry M, et al. *NTRK* gene fusions in biliary tract cancers. *J Clin Oncol* 2020;38:574-574. Available at:

[https://ascopubs.org/doi/abs/10.1200/JCO.2020.38.4\\_suppl.574](https://ascopubs.org/doi/abs/10.1200/JCO.2020.38.4_suppl.574).

768. Drilon A, Siena S, Ou SI, et al. Safety and antitumor activity of the multitargeted pan-TRK, ROS1, and ALK inhibitor entrectinib: Combined results from two phase I trials (ALKA-372-001 and STARTRK-1). *Cancer Discov* 2017;7:400-409. Available at:

<https://www.ncbi.nlm.nih.gov/pubmed/28183697>.

769. Doebele RC, Drilon A, Paz-Ares L, et al. Entrectinib in patients with advanced or metastatic *NTRK* fusion-positive solid tumours: integrated analysis of three phase 1-2 trials. *Lancet Oncol* 2020;21:271-282.

Available at: <https://www.ncbi.nlm.nih.gov/pubmed/31838007>.

770. Drilon A, Laetsch TW, Kummar S, et al. Efficacy of larotrectinib in *TRK* fusion-positive cancers in adults and children. *N Engl J Med* 2018;378:731-739. Available at:

<https://www.ncbi.nlm.nih.gov/pubmed/29466156>.

771. Goeppert B, Frauenschuh L, Renner M, et al. BRAF V600E-specific immunohistochemistry reveals low mutation rates in biliary tract cancer and restriction to intrahepatic cholangiocarcinoma. *Mod Pathol* 2014;27:1028-1034. Available at:

<https://www.ncbi.nlm.nih.gov/pubmed/24309328>.

772. Wainberg ZA, Lassen UN, Elez E, et al. Efficacy and safety of dabrafenib (D) and trametinib (T) in patients (pts) with BRAF V600E-mutated biliary tract cancer (BTC): A cohort of the ROAR basket trial. *J Clin Oncol* 2019;37:187-187. Available at:

[https://ascopubs.org/doi/abs/10.1200/JCO.2019.37.4\\_suppl.187](https://ascopubs.org/doi/abs/10.1200/JCO.2019.37.4_suppl.187).

773. Subbiah V, Lassen U, Elez E, et al. Dabrafenib plus trametinib in patients with BRAF(V600E)-mutated biliary tract cancer (ROAR): a phase 2, open-label, single-arm, multicentre basket trial. *Lancet Oncol* 2020;21:1234-1243. Available at:

<https://www.ncbi.nlm.nih.gov/pubmed/32818466>.

774. Salama AKS, Li S, Macrae ER, et al. Dabrafenib and trametinib in patients with tumors with BRAF(V600E) mutations: Results of the NCI-MATCH trial Subprotocol H. *J Clin Oncol* 2020;38:3895-3904. Available at: <https://www.ncbi.nlm.nih.gov/pubmed/32758030>.

775. Kim HJ, Yoo TW, Park DI, et al. Gene amplification and protein overexpression of HER-2/neu in human extrahepatic cholangiocarcinoma as detected by chromogenic in situ hybridization and immunohistochemistry: its prognostic implication in node-positive patients. *Ann Oncol* 2007;18:892-897. Available at:

<https://www.ncbi.nlm.nih.gov/pubmed/17322545>.

776. Marabelle A, Fakih M, Lopez J, et al. Association of tumour mutational burden with outcomes in patients with advanced solid tumours treated with pembrolizumab: prospective biomarker analysis of the multicohort, open-label, phase 2 KEYNOTE-158 study. *Lancet Oncol* 2020;21:1353-1365. Available at:

<https://www.ncbi.nlm.nih.gov/pubmed/32919526>.

777. Sicklick JK, Kato S, Okamura R, et al. Molecular profiling of cancer patients enables personalized combination therapy: the I-PREDICT study. *Nat Med* 2019;25:744-750. Available at:

<https://www.ncbi.nlm.nih.gov/pubmed/31011206>.

778. Kim RD, Chung V, Alese OB, et al. A phase 2 multi-institutional study of nivolumab for patients with advanced refractory biliary tract cancer. *JAMA Oncol* 2020;6:888-894. Available at:

<https://www.ncbi.nlm.nih.gov/pubmed/32352498>.

779. Lwin Z, Gomez-Roca C, Saada-Bouazid E, et al. LEAP-005: Phase II study of lenvatinib (len) plus pembrolizumab (pembro) in patients (pts) with previously treated advanced solid tumours [abstract]. *Ann Oncol* 2020;31:Abstract LBA41. Available at:

<https://oncologypro.esmo.org/meeting-resources/esmo-virtual-congress-2020/leap-005-phase-ii-study-of-lenvatinib-len-plus-pembrolizumab-pembro-in-patients-pts-with-previously-treated-advanced-solid-tumours>.



780. Javle M, Churi C, Kang HC, et al. HER2/neu-directed therapy for biliary tract cancer. *J Hematol Oncol* 2015;8:58. Available at: <https://www.ncbi.nlm.nih.gov/pubmed/26022204>.

781. Subbiah V, Hu MI-N, Gainor JF, et al. Clinical activity of the RET inhibitor pralsetinib (BLU-667) in patients with RET fusion–positive solid tumors [abstract]. *J Clin Oncol* 2021;39:Abstract 467. Available at: [https://ascopubs.org/doi/abs/10.1200/JCO.2021.39.3\\_suppl.467](https://ascopubs.org/doi/abs/10.1200/JCO.2021.39.3_suppl.467).

782. Kato S, Subbiah V, Marchlik E, et al. RET Aberrations in Diverse Cancers: Next-Generation Sequencing of 4,871 Patients. *Clin Cancer Res* 2017;23:1988-1997. Available at: <https://www.ncbi.nlm.nih.gov/pubmed/27683183>.

783. Sun W, Patel A, Normolle D, et al. A phase 2 trial of regorafenib as a single agent in patients with chemotherapy-refractory, advanced, and metastatic biliary tract adenocarcinoma. *Cancer* 2019;125:902-909. Available at: <https://www.ncbi.nlm.nih.gov/pubmed/30561756>.

784. Kim RD, Sanoff HK, Poklepovic AS, et al. A multi-institutional phase 2 trial of regorafenib in refractory advanced biliary tract cancer. *Cancer* 2020;126:3464-3470. Available at: <https://www.ncbi.nlm.nih.gov/pubmed/32453456>.

785. Demols A, Borbath I, Van den Eynde M, et al. Regorafenib after failure of gemcitabine and platinum-based chemotherapy for locally advanced/metastatic biliary tumors: REACHIN, a randomized, double-blind, phase II trial. *Ann Oncol* 2020;31:1169-1177. Available at: <https://www.ncbi.nlm.nih.gov/pubmed/32464280>.